Severe Influenza A (H1N1): The Course of Imaging Findings

Dorith Shaham MD[1], Naama R. Bogot MD[4], Galit Aviram MD[5], Ludmila Guralnik MD[6], Sivan Lieberman MD[1], Laurian Copel MD[7], Jacob Sosna MD[1], Allon E. Moses MD[2], Itamar Grotto MD PhD[8] and Dan Engelhard MD[3]

Departments of [1]Radiology, [2]Microbiology & Infectious Diseases, and [3]Pediatrics, Hadassah-Hebrew University Medical Center, Jerusalem, Israel
[4]Department of Radiology, Shaare Zedek Medical Center, Jerusalem, Israel
[5]Department of Radiology, Tel Aviv Sourasky Medical Center, Tel Aviv, Israel
[6]Department of Radiology, Rambam Medical Center, Haifa, Israel
[7]Department of Radiology, Assaf Harofeh Medical Center, Zerifin, Israel
[8]Ministry of Health, Jerusalem, Israel

ABSTRACT: **Background:** An outbreak of respiratory illness caused by a novel swine-origin influenza virus (influenza A/H1N1 2009) that began in Mexico was declared a global pandemic by the World Health Organization in June 2009. The pandemic affected many countries, including Israel.

Objectives: To compare the course of chest radiographic and computed tomography findings in patients who survived and those who died following admission to the intensive care unit (ICU) or intubation due to severe laboratory-confirmed swine-origin influenza A/H1N1 2009.

Methods: We retrospectively reviewed the patient records (267 radiographs, 8 CTs) of 22 patients (10 males, 12 females) aged 3.5–66 years (median 34) with confirmed influenza A/H1N1 2009, admitted to the ICU and/or intubated in five major Israeli medical centers during the period July–November 2009. We recorded demographic, clinical, and imaging findings – including pattern of opacification, extent, laterality, distribution, zone of findings, and presence/absence of nodular opacities – at initial radiography and during the course of disease, and compared the findings of survivors and non-survivors. Statistical significance was calculated using the Wilcoxon (continuous variables) and Fisher exact tests.

Results: The most common findings on the initial chest radiography were airspace opacities, which were multifocal in 17 patients (77%) and bilateral in 16 (73%), and located in the lower or lower and middle lung zones in 19 patients (86%). Large airspace nodules with indistinct margins were seen in 8 patients (36%). Twelve patients survived, 10 died. Patients who died had multiple background illnesses and were significantly older than survivors ($P = 0.006$). Radiologic findings for the two groups were not significantly different.

Conclusion: Airspace opacities, often with nodular appearance, were the most common findings among patients with severe influenza A/H1N1 2009. The course of radiologic findings was similar in patients with severe influenza A/H1N1 2009 who survived and those who died.

IMAJ 2011; 13: 591–596

KEY WORDS: chest computed tomography, chest radiography, intensive care unit, infectious diseases, influenza A/H1N1 2009, intubation, pandemic

An outbreak of respiratory illness caused by a novel influenza virus of swine origin (influenza A/H1N1 2009) that began in Mexico [1] was declared a global pandemic by the World Health Organization in June 2009 [2]. By March 2010, over 1.5 million cases and 16,000 deaths had been verified and reported worldwide [3,4]. Due to the enormous burden of morbidity, reports of verified cases underestimated the magnitude of the pandemic [5,6]. In some countries, 10%–30% of influenza A/H1N1 2009 patients required admission to intensive care units [5].

In Israel, despite a gradual decline in the rate of new diagnoses in late 2009, by February 2010 a total of 10,267 patients had been diagnosed with verified influenza A/H1N1 2009, with 223 patients admitted to intensive care units and 90 deaths [4]. A normal seasonal level of influenza-like disease was reached in April 2010 [7]. The WHO reported that half of the hospitalized patients were at higher risk due to chronic underlying conditions and immunocompromised states; however, a third of those admitted to ICUs were previously healthy [5].

The objective of our study was to describe the radiologic characteristics (on chest radiographs and CT) of severe influenza A/H1N1 2009 in patients who were hospitalized in an ICU and/or intubated, and to determine whether specific findings could be predictive of a mortal outcome in a patient population drawn from five leading medical centers in Israel.

PATIENTS AND METHODS

The study was approved by the Hadassah-Hebrew University Medical Center Institutional Review Board (approval 200-16.10.09), with agreement of the general directors or institutional review boards of all participating medical centers. Informed consent was waived.

PATIENTS

We identified patients who were admitted between 4 July 2009 and 15 November 2009 to the Hadassah-Hebrew University,

WHO = World Health Organization
ICU = intensive care unit

Shaare Zedek, Tel Aviv Sourasky, Assaf Harofeh, and Rambam medical centers with severe influenza A/H1N1 2009 confirmed by real-time reverse transcription polymerase chain reaction. We defined patients with severe disease as those who died with confirmed influenza A/H1N1 2009 infection, or who were admitted to the ICU and/or were intubated for severe respiratory symptoms associated with influenza A/H1N1 2009. A total of 22 patients in these medical centers met the inclusion criteria. We retrospectively reviewed their patient records, chest radiographs and CT scans.

The participants included 10 males and 12 females aged 3.5–66 years (median 34). Twenty patients (91%) were admitted to an ICU; 18 (82%) required advanced mechanical ventilation. One patient who was unconscious and required intubation and mechanical ventilation before admission was hospitalized on a medical ward. One patient died suddenly at night, 2 days following hospitalization, without mechanical ventilation or admission to the ICU. Three young patients, age 16–34 (mean 25), were observed in the ICU but did not require mechanical ventilation. ICU length of stay ranged from 2 to 48 days (mean 15). Ten patients died (case fatality rate 0.45).

We divided the patients into two groups – Group A with 12 patients who survived (patients 1–12) and Group B with 10 patients who died (patients 13–22) – and compared the course of radiological findings in the two groups. Patient characteristics from the two groups are shown in Table 1.

Admission date, length of hospitalization, ICU admission date, length of ICU stay, requirement of intubation and mechanical ventilation, other documented infections, and whether the patient survived or died, were recorded. Anonymized data were provided by each center and analyzed by the principal investigator.

Table 1. Characteristics and significant medical history of patients with severe influenza A/H1N1 2009 who survived (n=12)

Patient #	Age (yrs)	Gender	Significant medical history
Patients who survived			
1	24	M	Previously healthy
2	3.5	F	Previously healthy
3	63	M	Hypertension, hyperlipidemia
4	25	F	35 weeks pregnant
5	23	M	Cerebral palsy, epilepsy
6	18	F	Morbid obesity, gastroplasty 2 days prior to illness
7	34	F	33 weeks pregnant
8	16	M	Previously healthy
9	32	F	31 weeks pregnant
10	34	M	Hypothyroidism
11	26	F	29 weeks pregnant (twins)
12	28	F	20 weeks pregnant, thalassemia minor
Patients who died			
13	60	F	Mild retardation, schizophrenia, chronic anemia, septic shock
14	50	M	Ischemic heart disease, diabetes, end-stage renal disease, obesity
15	64	F	Diabetes, chronic lymphocytic leukemia, recent chemotherapy
16	51	F	Metastatic carcinoma of colon, chemotherapy
17	50	M	Obesity, diabetes
18	22	M	Down syndrome
19	44	M	Cellulitis of left hand, rhabdomyolysis, acute renal failure, IV drug abuse
20	63	F	Kidney transplantation
21	27	F	Morbid obesity
22	66	M	Chronic renal failure, bipolar disorder, syncope

RADIOLOGIC TECHNIQUE

Portable chest radiographs were performed with computed radiography equipment (AMX-4 plus, GE Healthcare, Milwaukee, WI, USA; FCR XG-1, Fuji Photo Film Co Ltd, Tokyo, Japan; Polymobile 2 and Mobilett XP, Siemens Healthcare, Munich, Germany) using standard protocols (70–80 kV, 1.6–5.0 mAs, 1 meter film-focus distance, antero-posterior view, broad tube focus).

CT examinations were performed using Brilliance 64-slice multidetector CT or MX 8000 IDT 16-slice MDCT (Philips Medical systems, Cleveland, OH) using standard techniques (collimation 64 x 0.625 mm or 16 x 0.75 mm, slice thickness 2–3 mm, increment 1–3 mm, mAs 180–420, and kVp 120). Iodinated contrast material (60–80 ml, 300 mg/ml) was injected at 2 ml/second.

MDCT = multidetector computed tomography

RADIOGRAPHIC ASSESSMENT

All chest radiographs and CT scans were analyzed by a fellowship-trained thoracic radiologist with 13 years thoracic experience (D.S.) in consensus with one of two other fellowship-trained thoracic radiologists (N.B., 8 years experience; S.L., 3 years).

Radiographs were classified as normal or abnormal. On the first abnormal radiograph for each patient, the appearance of opacification was characterized as airspace (confluent lung opacity that obscures the underlying vessels and is not accompanied by volume loss) or reticular (a collection of innumerable small linear opacities with a net-like appearance) [8]. This finding usually represents interstitial disease and may cause perihilar haziness. The extent (focal, multifocal), laterality (unilateral, bilateral), distribution (central, peripheral, diffuse) and zone(s) of the findings (upper, middle, lower, each comprising a third of the craniocaudal extent of the lung on frontal radiograph) were also noted.

Several additional radiographic findings were recorded as present or absent at any time during the course of the disease, including ground-glass opacities (hazy increased attenuation without obscuration of the underlying vessels), nodular opacities (well or poorly defined rounded opacities), and atelectasis (reduced volume accompanied by increased opacity [8]).

The number of radiographs and the course of pulmonary changes, determined by comparison of each radiograph to the preceding one, were documented. Extrapulmonary findings, including the presence and size of right or left pleural effusion (small, moderate, large) and other mediastinal abnormalities, were also noted. A radiograph was considered 'worse' than a preceding study when there was increasing opacification in the lungs due to more extensive lung disease or enlarging pulmonary effusions. CT studies were similarly evaluated.

STATISTICAL ANALYSIS

Demographic, clinical and radiologic characteristics were detailed and compared for the two groups. Statistical significance of differences between the groups was calculated using the Wilcoxon test for continuous variables and Fisher's exact test for categorical variables. $P < 0.05$ was considered significant.

RESULTS

PATIENTS

The male/female ratio was 5/7 in group A (12 survivors) and 5/5 in group B (10 patients who died). The age range in group A was 3.5–63 years (mean 27.21 ± 15.15) and 22–66 in group B (mean 49.70 ± 15.17). Patients in group B were significantly older ($P = 0.006$). All previously healthy patients (n=4) and pregnant women (n=5) were in group A. All patients in group B had at least one serious, systemic, preexisting condition. Patient demographics and clinical backgrounds are summarized in Table 1.

Additional documented infections were found in 6 of 12 patients (50%) in group A and 7 of the 10 patients (70%) in group B ($P = 0.41$), most commonly *Klebsiella pneumoniae*, *Pseudomonas aeruginosa* and *Staphylococcus aureus*.

Duration of hospitalization was longer for group A patients (range 5–58 days, mean 26.00 ± 17.81) versus group B patients (range 3–27, mean 11.60 ± 12.50), but the difference fell just short of statistical significance ($P = 0.058$). ICU length of stay was significantly longer ($P = 0.031$) for group A (range 2–48 days, mean 19.36 ± 15.11) versus group B (range 0–17 days, mean 7.10 ± 6.42).

RADIOGRAPHIC ASSESSMENT

We reviewed 267 radiographs, including 2–25 chest radiographs per patient in group A (mean 15.25 ± 16.50) and 2–19 in group B (mean 8.40 ± 6.77), and the difference was statistically significant ($P = 0.044$).

Table 2. A comparison of initial abnormal chest radiographic findings in patients with severe A/H1N1 2009 infection among patients who survived and those who died

	Group A (12 survivors)	Group B (10 non-survivors)	*P*
Type of opacities			
Airspace	12 (100%)	9 (90%)	
Interstitial	0 (0%)	1 (10%)	0.46
Extent			
Focal	4 (33%)	1 (10%)	
Multifocal	8 (67%)	9 (90%)	0.32
Laterality			
Unilateral	5 (42%)	1 (10%)	
Bilateral	7 (58%)	9 (90%)	0.10
Distribution			
Central	4 (33%)	6 (60%)	
Peripheral	4 (33%)	3 (30%)	
Diffuse	4 (33%)	1 (10%)	0.35
Zone			
Middle	1 (8%)	1 (10%)	
Lower	4 (33%)	6 (60%)	
Middle + lower	7 (58%)	2 (20%)	
All	0 (0%)	1 (10%)	0.21

Only one patient in group A (8%) and three in group B (30%) had normal initial radiographs. Findings on the first abnormal radiograph were similar in the two groups [Table 2]. At the first abnormal radiograph, all patients in group A and 9 of 10 in group B had airspace opacities; the remaining patient had perihilar interstitial haziness ($P = 0.46$). Four patients in group A (33%) and 1 in group B (10%) had a focal opacity; 8 in group A (67%) and 9 in group B (90%) had multifocal opacities ($P = 0.32$). Five patients in group A (42%) and 1 in group B (10%) had unilateral findings; 7 in group A (58%) and 9 in group B (90%) had bilateral findings ($P = 0.16$). Other findings for the first abnormal radiograph are summarized in Table 2.

During the course of disease, the most typical and potentially discriminative finding was large nodular airspace opacities with indistinct margins, detected in 8 patients (36%): 5 in group A (42%) and 3 in group B (30%) [Figure 1]. Ground-glass opacities were seen in only 5 patients (23%): 2 in group A (17%) and 3 in group B (30%). Atelectasis was detected in only 2 patients (9%), 1 from each group, in addition to 1 patient (group B) with iatrogenic left lung collapse.

The course of pulmonary findings [Table 3] was haphazard and did not appear different for the two groups. Improvement in chest radiographic findings occurred in three patients (# 15, 17, 19) in the days prior to death.

Additional extrapulmonary findings were also seen in both survivors and non-survivors. Small pleural effusions were seen in 17 patients (77%): 11 in Group A (92%) and 6 in Group B (60%). In the two groups combined, the effusion was bilateral in 9 of 17 (53%), left-sided in 6 (35%), and right-sided in 2 (12%).

Mediastinal abnormalities, judged incidental to the disease, were seen in 3 patients (14%), all from group B, and included mediastinal lipomatosis (1 patient) and cardiomegaly (2

Figure 1. [A] A 32 year old woman with severe influenza A/H1N1 2009 who survived (patient 9). Bilateral airspace nodular opacities in the mid and lower lung fields seen on the initial anterior posterior chest radiograph. **[B]** Ill-defined airspace nodular opacities with a predominantly central distribution on the initial anterior posterior chest radiograph in a 27 year old woman with severe influenza A/H1N1 2009 who died (patient 21). **[C]** Anterior posterior chest radiograph performed one day later revealed considerable worsening of the findings in the same patient. The patient died on the following day.

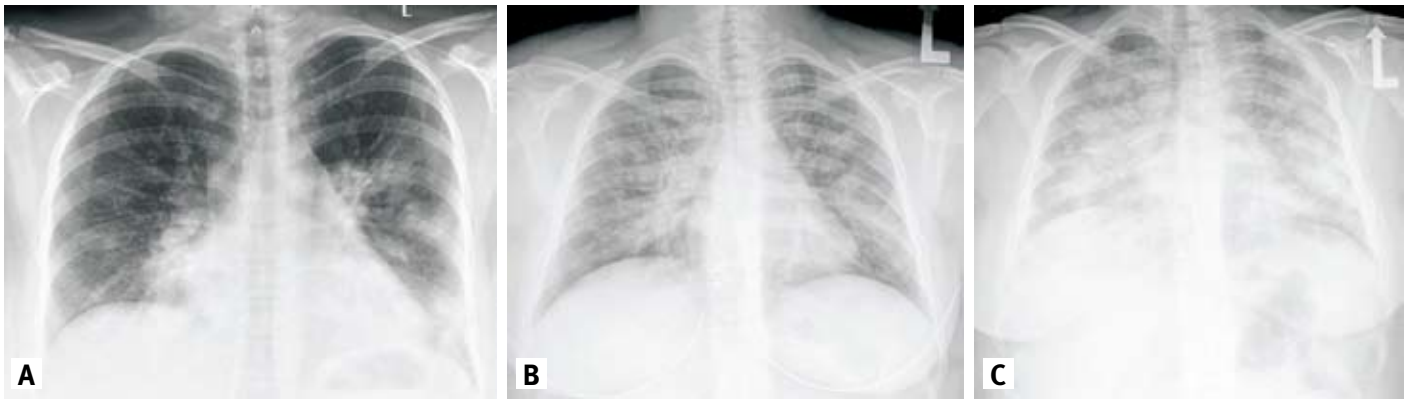

patients). Additional findings included pneumothorax (bilateral in two patients from group A, unilateral in one from group B), pneumomediastinum with subcutaneous emphysema following tracheostomy (one patient from A), hilar enlargement with perihilar haziness (one patient from B) and scoliosis unrelated to the disease (one patient from A).

CT FINDINGS

Eight CT scans of the chest were obtained in seven patients: six in five patients from group A and two from group B. CT was performed from admission day to 27 days following admission (mean 9 days). In the patient with two scans, one was performed on admission day and the second 24 days later. Six CT scans were obtained to better evaluate radiographic findings and their magnitude; two were performed for suspected pulmonary embolism. Iodinated contrast material was administered in five examinations, including the two studies in one patient.

In 71% of patients with CT (5/7), the pulmonary findings were airspace opacities. One patient had septal line thickening and another had subsegmental atelectatic changes, both from group A. Pulmonary findings were multifocal and bilateral in all cases. Four patients (57%) had diffuse lung opacities, 1 (14%) had central, and 2 (29%) had peripheral findings. Findings involved the middle and lower zones in 3 patients (43%), the lower zone in 2 (29%), the middle zone in 1 (14%), and all three zones in 1 (14%).

Only two patients had pleural effusions, both were small. No mediastinal abnormalities were seen on CT. Additional findings included cavitation, necrosis, and bronchial thickening in one group A patient, and nodular airspace disease in a patient from group B. In another patient from group A, similar airspace nodules were noted in the lung bases of an abdominal CT scan obtained 22 days prior to chest CT.

In the patient from group A who had two CT scans, the first study showed confluent, bilateral airspace disease; the second showed marked improvement with mild patchy ground-glass opacities and streaky bibasilar opacities, likely representing subsegmental atelectasis.

DISCUSSION

We evaluated all chest radiographs and CT scans of 22 patients with severe, RT-PCR-proven influenza A/H1N1 2009 infection, comparing findings for survivors and for those who died. The course of radiographic findings was haphazard and we found no significant differences in the nature of findings between the two groups.

A new and potentially useful finding in our study was large nodular airspace opacities with indistinct margins in 36% of the patients. This finding was unique in appearance and may be suggestive for severe influenza A/H1N1 2009 infection. Most patients had multifocal, bilateral airspace opacities, usually in the lower or lower and middle lung zones.

Ground-glass opacities were relatively uncommon in our series versus earlier reports [8-10], possibly due to the relatively greater severity of disease in our patients [8,9,11,12]. Greater severity may have resulted in denser consolidation [10]. Small pleural effusions were common. As reported previously [8,9,11,12], findings that are typical for small airway disease and usually seen in viral infections, such as centrilobular nodules, tree-in-bud opacities, and a mosaic pattern of attenuation, were not seen [9]. In seven patients who had undergone CT, findings were multifocal and bilateral, primarily airspace opacities, with diffuse distribution compared to chest radiographs. Most CT findings were in the mid-lower lung.

RT-PCR = reverse transcriptase-polymerase chain reaction

Table 3. Course of findings on chest radiography in severe influenza A/H1N1 patients who survived (Group A) and those who died (Group B)

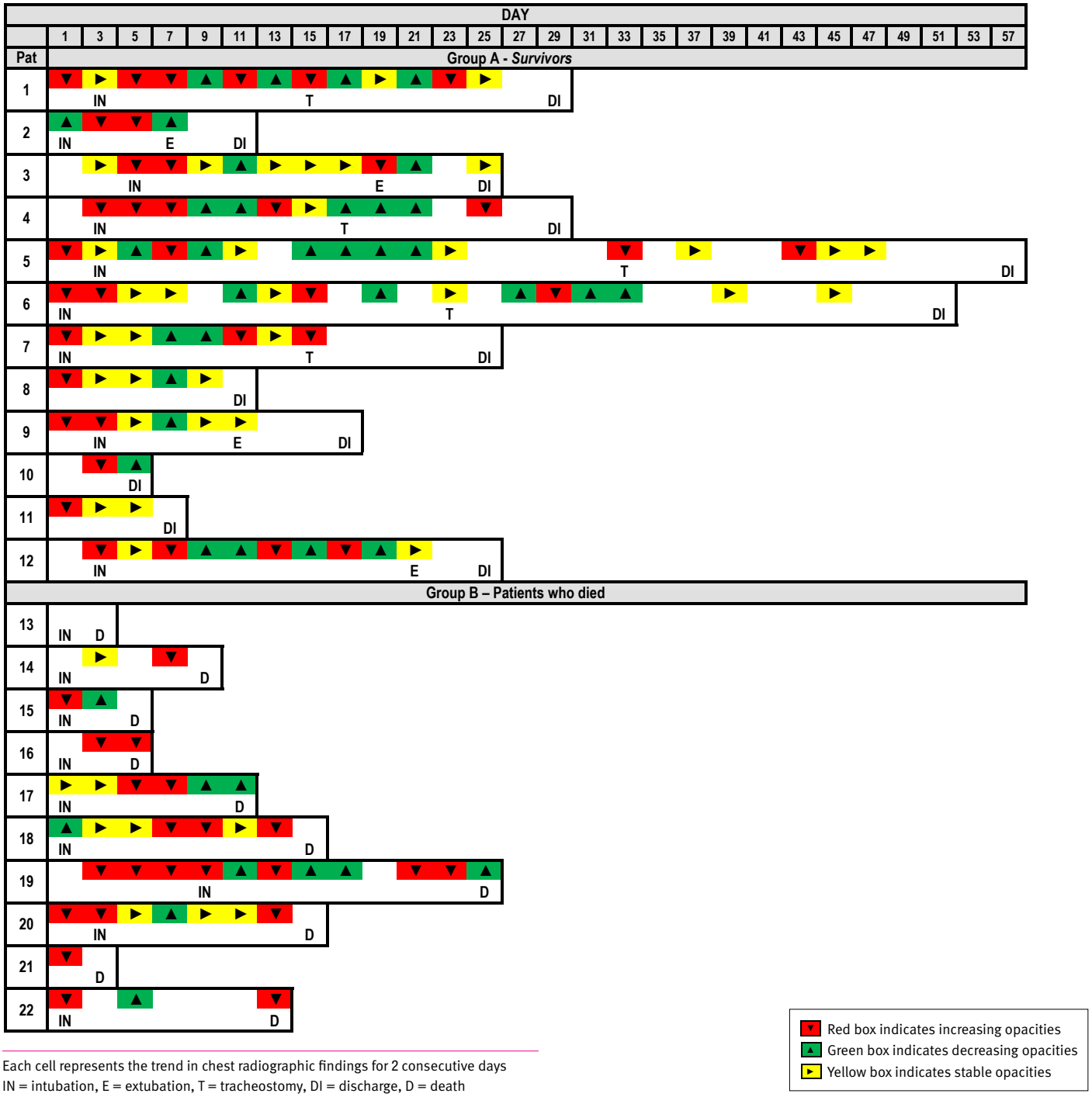

Each cell represents the trend in chest radiographic findings for 2 consecutive days
IN = intubation, E = extubation, T = tracheostomy, DI = discharge, D = death

Several recent papers described imaging findings in influenza A/H1N1 2009 virus of varying severity [10-14]. The most common findings were patchy ground-glass opacities, with or without associated focal or multifocal areas of consolidation. MDCT showed ground-glass opacities, with or without associated focal or multifocal areas of consolidation [10,12,14], and high resolution CT had higher sensitivity in detecting abnormalities compared to chest radiographs [10].

Earlier studies found that the initial chest radiograph was predictive of outcome. Agarwal et al. [11] reviewed chest

radiographs in 66 patients. The 14 patients requiring ICU admission and mechanical ventilation were predominantly male and had a higher mean age. All ventilated patients had an abnormal initial radiograph with extensive disease versus an abnormal initial radiograph in 73% of the 42 patients with less severe disease. The predominant radiographic finding was patchy consolidation, usually in the lower and central lung zones.

Aviram and colleagues [15] reviewed 97 admission chest radiographs of influenza A/H1N1 2009 patients to determine whether they were predictive of clinical outcome. In 39 patients (40%) there were abnormal findings, including ground-glass opacities (69%) and consolidation (59%), with patchy (41%) and nodular (28%) opacities. Bilateral opacities and involvement of multiple lung zones were common (62% and 72%, respectively) and occurred significantly more frequently in patients with adverse outcomes, including mechanical ventilation and death.

Our study is unique for its longitudinal evaluation of chest radiographs in patients with severe, laboratory-proven A/H1N1 2009 infection, whereas other studies evaluated a single admission chest radiograph of patients with varying degrees of severity.

A recent paper by Shlomai et al. [16] described 179 patients hospitalized in Israel who were tested for influenza A/H1N1 2009 infection, of whom 65 (36%) were found to be positive. Of those 65 patients, 14 (21.5%) had acute respiratory insufficiency requiring ICU admission. These patients were neither older nor previously sicker than patients with non-severe disease. In our patients who were admitted to the ICU, patients who died were significantly older than survivors, and all those who died had at least one serious, systemic, preexisting condition. All patients alive for more than 17 days in the ICU survived, demonstrating a benefit in prolonged intensive treatment.

Our study has several limitations. It was retrospective, and the number of participants was small. However, we describe about 25% of the A/H1N1 2009 patients who were admitted to the ICU during the study period and a similar proportion of those who died of the disease. Our patients reflect the experience of five academic institutions, including three of the six major tertiary medical centers in the country. In addition, to the best of our knowledge, ours is the only study to date summarizing findings for the duration of inpatient treatment for severe influenza A/H1N1 2009. We used consensus reading, as in a previous study [15], since interobserver agreement regarding type and localization of findings on chest radiographs has been shown to be inconsistent.

In conclusion, the most common findings in patients with severe influenza A/H1N1 2009 were multifocal, bilateral airspace opacities, usually in the lower or lower and middle lung zones, while ground-glass opacities were relatively rare. First described here are large nodular airspace opacities with indistinct margins, which were found in around a third of the patients and may be suggestive for severe influenza A/H1N1 disease. Most patients who died were older and had more preexisting illnesses. Survivors and non-survivors presented with similar radiographic and CT characteristics.

Acknowledgments

The authors wish to thank Shifra Fraifeld, the Research Associate in the Department of Radiology at the Hadassah-Hebrew University Medical Center, for her editorial assistance in the preparation of this manuscript.

Corresponding author:

Dr. D. Shaham

Dept. of Radiology, Hadassah-Hebrew University Medical Center (Ein Kerem Campus), Jerusalem 91120, Israel

Phone: (972-2) 677-8157, (972-2) 677-6901

Fax: (972-2) 643-7531

email: dshaham@hadassah.org.il

References

1. Perez-Padilla R, de la Rosa-Zamboni D, Ponce de Leon S, et al. Pneumonia and respiratory failure from swine-origin influenza A (H1N1) in Mexico. *N Engl J Med* 2009; 361 (7): 680-9.
2. World Now at the Start of 2009 Influenza Pandemic. Geneva: World Health Organization (WHO), 2009.
3. WHO Pandemic (H1N1) 2009 – update 90. Journal. 2010 Date; (March 8, 2010): Available from: http://www.who.int/csr/don/2010_03_05/en/index.html. Accessed Mar 10, 2010.
4. A/H1N1 influenza: the situation in Israel and the world. Journal. 2010 Date; (March 8, 2010): Available from: http://www.health.gov.il/h1n1/world.asp. Accessed Mar 8, 2010.
5. Clinical management of human infection with pandemic (H1N1) 2009: revised guidance November 2009. Journal. 2009 Date; (March 8, 2010): Available from: http://www.who.int/csr/resources/publications/swineflu/clinical_management_h1n1.pdf. Accessed Mar 8, 2010.
6. Dawood FS, Jain S, Finelli L, Shaw MW, et al. Emergence of a novel swine-origin influenza A (H1N1) virus in humans. *N Engl J Med* 2009; 360 (25): 2605-15.
7. Status of influenza-like illness in Israel (Apr 17, 2010). Journal. 2010 Date: Available from: http://www.health.gov.il/Download/pages/flu170410.pdf. Accessed Dec 27, 2010.
8. Hansell DM, Bankier AA, MacMahon H, McLoud TC, Muller NL, Remy J. Fleischner Society: glossary of terms for thoracic imaging. *Radiology* 2008; 246 (3): 697-722.
9. Ketai LH. Conventional wisdom: unconventional virus. *AJR Am J Roentgenol* 2009; 193 (6): 1486-7.
10. Marchiori E, Zanetti G, Hochhegger B, et al. High-resolution computed tomography findings from adult patients with influenza A (H1N1) virus-associated pneumonia. *Eur J Radiol* 2009; 74 (1): 93-8.
11. Agarwal PP, Cinti S, Kazerooni EA. Chest radiographic and CT findings in novel swine-origin influenza A (H1N1) virus (S-OIV) infection. *AJR Am J Roentgenol* 2009; 193 (6): 1488-93.
12. Ajlan AM, Quiney B, Nicolaou S, Muller NL. Swine-origin influenza A (H1N1) viral infection: radiographic and CT findings. *AJR Am J Roentgenol* 2009; 193 (6): 1494-9.
13. Lee CW, Seo JB, Song JW, et al. Pulmonary complication of novel influenza A (H1N1) infection: imaging features in two patients. *Korean J Radiol* 2009; 10 (6): 531-4.
14. Mollura DJ, Asnis DS, Crupi RS, et al. Imaging findings in a fatal case of pandemic swine-origin influenza A (H1N1). *AJR Am J Roentgenol* 2009; 193 (6): 1500-3.
15. Aviram G, Bar-Shai A, Sosna J, et al. H1N1 influenza: initial chest radiographic findings in helping predict patient outcome. *Radiology* 2010; 255 (1): 252-9.
16. Shlomai A, Nutman A, Kotlovsky T, Schechner V, Carmeli Y, Guzner-Gur H. Predictors of pandemic (H1N1) 2009 virus positivity and adverse outcomes among hospitalized patients with a compatible syndrome. *IMAJ Isr Med Assoc J* 2010; 12 (10): 622-7.