Deep Neck Infections, Life Threatening Infections of Dental Origin: Presentation and Management of Selected Cases

Michael Pesis DMD, Eitan Bar-Droma MD/DMD, Anatoliy Ilgiyaev DMD and Navot Givol DMD

Unit of Oral and Maxillofacial Surgery, Soroka University Medical Center and Faculty of Health Sciences, Ben-Gurion University of the Negev, Beer Sheva, Israel

ABSTRACT: **Background:** Untreated dental caries or even dental manipulations, such as a tooth extraction, might cause direct spread of an odontogenic infection and consequently the development of life-threatening conditions such as deep neck infections (DNI). The most common source of DNI is of odontogenic origin (38.8–49%). Abscess formation or cellulitis can lead to life-threatening complications, despite new diagnostic imaging technology and widespread availability of antibiotics.

Objectives: To demonstrate the dangers of DNI, which can create life-threatening situations.

Methods: Five cases of DNI of odontogenic origin, which were referred to the oral and maxillofacial surgery unit, are presented.

Results: Clinical manifestations included trismus, dysphagia, dysphonia, dyspnea, and infection symptoms. In all cases, computed tomography confirmed diagnosis and extent of abscess. Complications included mediastinitis, respiratory distress, osteomyelitis of the jaws, and in rare cases the mandibular condyle. Treatment included securing the airway, immediate surgical drainage, removal of the infection source, and antibiotic therapy. All patients were discharged in stable and improved condition.

Conclusions: DNI treatment on an emergency basis requires proper diagnosis and effective management. To confirm diagnosis and prevent serious complications, it is essential for physicians to recognize the spaces of the head and neck that are likely to be affected by DNI.

IMAJ 2019; 21: 806–811

KEY WORDS: deep neck infection, head and neck, odontogenic, osteomyelitis, mediastenitis

Deep neck infection (DNI) is an infectious process in the potential spaces and fascial planes of the neck, leading to abscess formation or cellulitis [1]. In the pre-antibiotic era, tonsillar and peritonsillar infections caused 70% of DNIs. Currently the most common primary source of DNI is odontogenic (38.8–49%). Deaths and complications of DNI are reduced due to timely intervention and availability of newer antimicrobial therapy with broad-spectrum coverage. However, some cases of DNI prove challenging, especially in immunocompromised patients where sometime the infection spreads very rapidly and can cause morbidity and mortality [2,3]. The second most common cause of DNI is peritonsillar abscess (20%), followed by salivary glands, foreign bodies, and malignancies. DNI can also be a consequence of tuberculosis, branchial cleft cyst, thyroiditis, pharyngitis, trauma to the head and neck, or intravenous (IV) drug abuse.

Odontogenic infections invade the spongy bone, reaching or passing through the cortical plate, to the soft tissues. The infection might spread upward to the brain, resulting in brain abscess, cavernous sinus thrombosis, or meningitis. Alternatively, the infections may spread downward and cause mediastinitis or pericarditis, pleural empyema, jugular vein thrombosis, and septic shock. DNI are potentially life-threatening infections with a significant morbidity and although the prevalence rates and complication incidence have been reduced, due to the new diagnostic imaging technologies and widespread availability of antibiotics, serious infection related complications have been reported in up to 20% of cases [4].

The most dramatic manifestation of DNI is Ludwig's angina, a rapidly progressive, potentially fulminant cellulitis involving the submental and both sides of sublingual and submandibular spaces. Immunocompromised patients with diabetes mellitus, who are undergoing chemotherapy or steroid therapy or patients with HIV infection are especially at risk of a fatal outcome. Bacterial cultures taken from DNI sites demonstrate polymicrobial flora including *Streptococcus* species, *Peptostreptococcus* species, *Staphylococcus aureus*, and anaerobic bacteria [5,6].

Clinical manifestation of DNI include pain, fever, malaise, fatigue, swelling, raised floor of the mouth, odynophagia, dysphagia, trismus, dysphonia, otalgia, and dyspnea [7,8]. These signs are warnings for general dentists. DNI presents as an emergency situation and requires action to secure the airway, an immediate surgical drainage of infected spaces, removal of the source of the infection, and antibiotic treatment. The

This work was presented, in part, at the International Conference of Oral and Maxillofacial Surgery, Hong Kong, China, March–April 2017

purpose of this article is to present five unique cases of DNI of odontogenic origin.

PATIENTS AND METHODS

We present five cases of DNI of odontogenic origin, which were referred to the oral and maxillofacial surgery unit. The study was approved by the institutional ethics committee.

CASE REPORTS

CASE 1

A 37-year-old man was referred to the emergency department (ED) due to severe progressive facial swelling and a toothache that persisted for a month and was aggravated in the last day before the patient was referred to the ED. A month prior to his admission to the ED, he had root canal treatment on tooth #37 and was treated for 3 weeks with twice daily 875 mg oral augmentin (amoxicillin and clavulanate). For the last 4 days, he was treated with 1 gram daily IV rocephin (ceftriaxone). He had lost 20 kg of weight during this 3-week period. General medical history was noncontributing. On physical examination, the patient presented with acute distress and extreme pain with slight dyspnea, dysphagia, and dysphonia.

Extra-oral examination revealed a fluctuate facial swelling in the submental and left submandibular regions that crossed the midline with local skin reddening. Mouth opening was 30 mm. Intra-oral examination revealed tooth #37 with a temporary filling and an extreme vestibular and buccal fluctuate swelling from tooth #37 to tooth #41 in addition to floor of mouth elevation on the left side. Computed tomography (CT) with contrast material showed pus collection approximately 2.8 × 5.2 cm in dimension, enveloping the left mandible [Figure 1], which caused displacement of the mouth floor muscles to the right. Enlarged submandibular lymph nodes did not indicate evidence of bone destruction.

The patient was diagnosed with DNI. In the operation room under general anesthesia a drainage of submental, left submandibular, and sublingual spaces was performed. The patient was admitted to the intensive care unit (ICU) where he stayed sedated with respiratory support for almost 3 weeks. During this period the patient was septic and treated with IV clindamycin 900 mg three times per day and IV tavanic (levofloxacin) 500 mg once a day. Tracheostomy was performed and the infected tooth was extracted. Finally, after 3 weeks, the patient was transferred to the oral and maxillofacial department for further observation. He was discharged from the hospital 4 weeks after admission with recommendations for further dental treatment.

Figure 1. Computed tomography scan with contrast material, sagittal view, demonstrating left submandibular hypodense areas approximately 2.8 × 5.2 cm in dimension, enveloping the left mandible

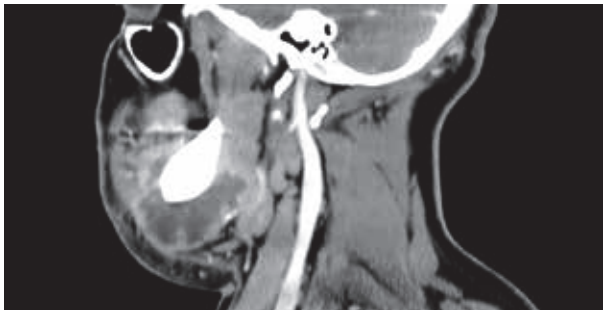

CASE 2

A 49-year-old man was referred to the ED due to severe progressive left submandibular swelling, toothache, fever, and functional deterioration. General medical history revealed schizophrenia and mental retardation. On physical examination, the patient was evaluated as a well-nourished man in acute distress and extreme pain, with fever, dyspnea, dysphagia, and dysphonia. Extra-oral examination revealed a fluctuate swelling in the submental, left infraorbital, and submandibular regions and on the neck on the same side with local skin reddening in addition to trismus. CT without contrast material demonstrated on the left side soft tissue swelling of the masticatory and parotid spaces that also involved the sternocleidomastoid muscle down to its lower part at the entrance to the chest. The CT showed that the spaces contained air bubbles and widespread liquefaction. There was involvement of the floor of the mouth and the parapharyngeal space on the left side with a slight deflection of the trachea. Multiple enlarged neck lymph nodes on both sides were noticed without evidence of bone destruction or osteomyelitis. The diagnosis was DNI.

The patient was rushed to the operation room. Under general anesthesia a drainage of pus from submental, left submandibular, sublingual, buccal, and infraorbital spaces was performed. Tooth #38 was extracted. The patient was admitted to the ICU where he stayed sedated with respiratory support. Due to appearance of signs and symptoms of sepsis on the second day after the surgery, the patient underwent a CT examination that revealed necrosis in the left submandibular and submental spaces that extended to the sternum with enlargement of the submandibular lymph nodes, mainly on the left [Figure 2].

The patient underwent several more debridements and additional drainage of the affected spaces. Treatment also included 900 mg IV clindamycin three times per day and 1 gram IV rocephin (ceftriaxone) once daily. Due to bacteriology culture positive for *Enterobacter* and Methicillin-resistant *Staphylococcus aureus* (MRSA), IV vancomycin (1250 mg) twice a day was added. After 17 days the patient was weaned and transferred to our oral and maxillofacial department for further observation. After final closure of drainage wounds and 4 weeks of hospitalization in total, the patient was discharged.

CASE 3

A 69-year-old man was referred to the ED due to severe progressive right facial swelling for a few days. The patient revealed that he underwent extraction of teeth #16, #17, and #48 a few days before the appearance of the symptoms. One week prior to hospitalization, he was treated twice in the ED for complaints of pain in the right temporomandibular joint area.

General medical history revealed that the patient had unbalanced diabetes and hypertension. He was a hepatitis C virus carrier. On physical examination, the patient was evaluated as a well-nourished man in pain, without fever or airway restriction. Extra-oral examination revealed fluctuate facial swelling in the right submandibular, buccal, and temporal regions with local skin reddening. Mouth opening was approximately 45 mm. Intra-oral examination revealed an extreme vestibular, buccal, and retromandibular fluctuate swelling and slight redness on the right oropharynx. Teeth extraction sites showed normal healing process with no evidence of local infection. CT examination with contrast material demonstrated bulged hard uneven texture in right masticatory space with involvement of the masseter muscle as well as lateral and medial pterygoid muscles, and infratemporal fossa. Hypodense areas inside the muscles and blurring of fat in the nearby subcutaneous soft tissues were noticeable. The process caused a slight deviation of the trachea to the left. An infiltration and a slight swelling of the right parotid gland were present. No mandibular bone destruction was noticeable. Light browsing of right mandibular condyle due to puffiness of the synovial tissue was present, as was a small focal bony destruction of the right lateral pterygoid process.

Figure 2. Computed tomography scan without contrast material, sagittal view, demonstrating necrosis in the left submandibular and submental spaces that extended to the sternum

The diagnosis was DNI. In the operation room, drainage of right submandibular, buccal, superficial temporal, pterygomandibular, and lateral pharyngeal spaces was performed. The patient was referred for further observation in our department unit for a week. The patient was treated with 1 gram IV augmentin (amoxicillin and clavulanate) three times per day. He was stable and his condition continued to improve. Two weeks after hospital admission, he was discharged.

CASE 4

A 21-year-old woman was referred to the ED due to progressive left facial swelling. Anamnesis revealed a toothache and high fever had been present for 5 days. She was treated for 3 days with antibiotics. The patient reported a history of recurrent episodes of inflammations on the left side of the mandible. The patient was generally healthy. On physical examination, the patient was evaluated as a well-nourished woman in no acute distress but in extreme pain with high fever (38.7°C) and dysphagia without dyspnea or dysphonia. Extra oral examination revealed a non-fluctuant submandibular and neck swelling extending to the cricoid cartilage. The skin on the left buccal region was erythematous and warm to palpation. The patient had a mild limitation of mouth opening. Intra-oral examination revealed teeth #37 and #38 with extensive caries and sublingual edema. CT examination with contrast material showed soft tissue swelling and extensive liquefaction zones in the left infratemporal fossa, parapharyngeal and retropharyngeal spaces, around the styloid process, around left submandibular salivary gland, around muscles of the tongue on both sides, and floor of the mouth with peripheral enhancement [Figure 3]. In addition, fluid was found in the paravertebral (Danger) space. On both sides of the neck enlarged lymph nodes were present. The diagnosis was DNI.

In the ED, the patient developed acute respiratory distress and was rushed to the operating room and drainage was performed under general anesthesia. A large amount of pus

Figure 3. Computed tomography scan with contrast material, sagittal view, demonstrating extensive liquefaction zones. In the left infratemporal fossa, parapharyngeal, and retropharyngeal spaces, around the styloid process, around left submandibular salivary gland, around muscles of the tongue and floor of the mouth

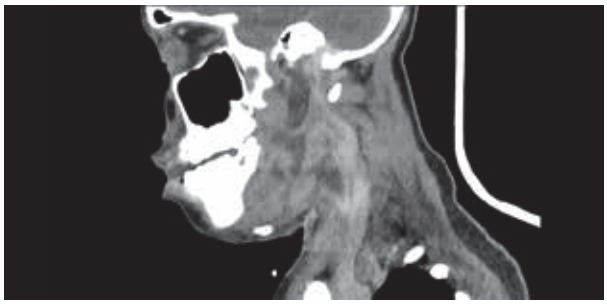

was drained and tooth #37 was extracted. The patient stayed in the ICU while sedated, mechanically ventilated and febrile (38.7°C). Broad spectrum antibiotic therapy of ciprofloxacin 400 mg twice a day and clindamycin 900 mg three times per day was initiated.

As there was no improvement in her condition, an additional CT scan was performed that revealed pus collection near the left lobe of the thyroid gland and mediastinum, just behind the sternum. Fluid accumulation was also observed in the right paratracheal space [Figure 4]. The patient underwent an urgent right thoracotomy and a large amount of pus was drained from the anterior mediastinum and subcarinal space. For the next month, the patient underwent three additional surgical interventions for debridement, drainage and washout of neck wounds. She was discharged from hospitalization in stable and improved condition, 4 weeks after admission.

CASE 5

A 31-year-old man was referred to the ED due to progressive bilateral facial swelling, fever, limitation in mouth opening, dysphagia, and dysphonia for 2 days. Anamnesis revealed that he had a toothache of left lower teeth and received oral Augmentin (amoxicillin and clavulanate potassium) 875 mg twice daily for 2 weeks. The patient was evaluated as a well-nourished, healthy man presented in extreme pain with severe dyspnea.

Extra oral examination revealed a fluctuant submental, left and right submandibular and neck swelling. The skin on the right and left submandibular regions was erythematous, warm to palpation and the patient had a sever trismus. Intraoral examination was impaired due to the trismus. The patient underwent awake intubation in the ED due to respiratory failure. CT examination with contrast material demonstrated bony defect around tooth #36 and hypodense area near the tooth ongoing downward and reaching the submental area. The hypodense area was constructed of several small areas with gentle partitions and it passed the midline to the right, causing displacement of the muscles of the tongue to the right. The diagnosis was DNI.

During surgery under general anesthesia, a large amount of pus was drained and the tooth was extracted. The patient was admitted to the ICU while sedated and mechanically ventilated. He was discharged from hospitalization in stable and improved condition, 11 days after admission.

Figure 4. Computed tomography scan with contrast material, sagittal view, demonstrating liquid collection in the left lobe of the thyroid gland and mediastinum, just behind the sternum

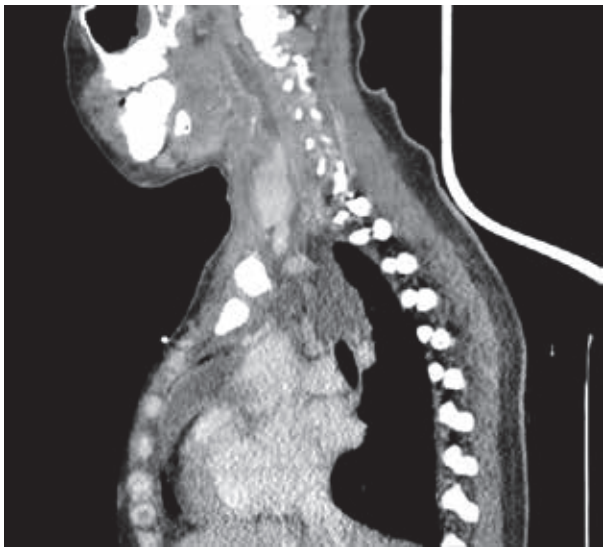

RESULTS

The cause for DNI in our case series was pulp necrosis in four patients, and post-extraction infection in one patient. The DNIs originated from mandibular molars in 80% of the cases and from maxillary molars in 20%. In two of our patients, bacterial cultures of *Streptococcus mutans* and *Staphylococcus aureus* were isolated. The three other patients were infected with *Prevotella intermedia*, *Peptostreptococcus micros*, and *Actinomyces meyeri*. Two of our patients were treated with broad-spectrum antibiotics prior to hospitalization. One patient showed no signs of DNI on admission but developed DNI within a few hours following admission.

In all patients more than one anatomical space was involved [Table 1]. In the analysis of our case series, the submandibular space was the most frequently involved region for DNI (100%) followed by submental space (60%), the neck (60%), buccal space (40%), sublingual space (40%), retropharyngeal space (40%), and temporal, infraorbital, retromandibular, and masseteric spaces (20% each). Of our patients, 60% presented with

Table 1. Summary of patients' evaluation data

Patient	Fluid collection on computed tomography	Trismus	Jaw	Side	Area	Fever	Pain
1	Yes	No	Mandible	Left and right	Submandibular + submental + buccal	No	Yes
2	Yes	Yes	Mandible	Left and right	Submandibular + submental + neck + parotid + parapharyngeal + infraorbital	Yes	Yes
3	Yes	No	Maxilla	Right	Submandibular + buccal + temporal + retromandibular + masseteric + lateral pharyngial + medial pharyngial	No	Yes
4	Yes	Yes	Mandible	Left and right	Submandibular + sublingual + parapharyngeal + retropharyngeal + neck	Yes	Yes
5	Yes	Yes	Mandible	Left and right	Submandibular + submental + neck	Yes	Yes

trismus, dysphagia was present in 80%, dyspnea in 60%, and dysphonia in 40% of our patients.

In the present case series, the duration of clinical signs and symptoms of odontogenic infection ranged from 2 days to 30 days prior to the involvement of the deep neck spaces.

DISCUSSION

Untreated dental caries or even an innocent dental manipulation such as a tooth extraction can cause direct spread of an odontogenic infection and consequently the development of life-threatening sequelae. DNI is the most dangerous dental associated complication. Recent studies showed that dental infections are the most common source of DNI (38–50%) [6,9-13]. The use of wide range antibiotics has reduced the incidence of DNIs; however, it is still considered a life-threatening complication [14]. The treating physician must be familiar with the anatomy of the deep neck spaces for fully understanding the pathophysiology and pathway of the spreading infection.

We presented the cases of four patients with DNI of odontogenic origin from apical lesions and one patient with DNI after teeth extraction (reason for extraction was unknown). All patients were treated in our department between 2015 and 2017.

Although this is a small series compared to the international published literature, it is important to review new local cases and their treatment. In our case series, there was a predominance of males (4:1) similar to previous studies [9,14-18]. The age range in our case series was 21–69 years, with a mean age of 41.4 years, which is compatible with the study of Huang et al. [6] who reported a mean age of 49.5 ± 20.5 years but in contrast with Bakir and colleagues [13], who reported of a mean age of 25.1 ± 15.5 years.

In our case series, 80% of the DNIs originated from mandibular molars and 20% from maxillary molars. Emerging multidrug-resistant bacteria [19-21], specifically *Streptococcus mutans* and *Staphylococcus aureus*, recently were determined to be the most commonly cultured organisms found in deep neck abscesses [5,6,13,14].

Three of our patients had other pathogens that were isolated from the drainage wounds. All of these pathogens are frequently found in oral flora. Case 2 had *Prevotella intermedia*, case 3 had *Peptostreptococcus micros*, and case 4 had *Actinomyces meyeri*. Thus, the need for surgical intervention for drainage and removal of the source of infection is important. Two of our patients were treated with broad-spectrum antibiotics prior to hospitalization. One case showed no signs of DNI on admission but developed DNI within a few hours after admission. The empirical use of broad spectrum antibiotics and anti-inflammatory medications may mask signs of DNI and delay its diagnosis [13].

Our results regarding the involvement of potential spaces of the neck are compatible with previous studies [14,18,22]. Presenting signs and symptoms in our patients were similar to previous reports [10,12,24]. Although dysphonia and dyspnea are less common, their presence is a hazardous sign, just a step before respiratory failure.

DNI spreads quickly, within hours or days. Once infection reaches the deep spaces, it risks affecting the airway. Therefore, close follow-up of the patient by the treating physician is crucial to ensure an early diagnosis of DNI with a timely referral for further medical treatment, if necessary.

In the present case series, two patients developed DNI following dental treatment, in one case following a tooth extraction and in the second case following root canal treatment. Notably, any type of dental treatment, even non-invasive, is a potential risk for severe, life-threatening infections [8].

Contrast CT scan is highly sensitive (91%) [5], and is thus the most appropriate imaging tool for diagnosis and to determine the extent of DNI and for distinguishing abscess from cellulitis. Contrast CT scan must be part of routine examinations of patients suspected for DNI as it is beneficial in differentiating and deciding whether surgical intervention is indicated, and also in evaluation of DNI complications [24]. In the presence of an abscess, surgical treatment is obligatory. CT scan can demonstrate the involved spaces and contribute to a successful outcome of the surgery.

Airway management is crucial and challenging in patients with DNI. Airway assessment should be the first step in evaluating patients with suspected DNI and it should be monitored during the entire process of patient examination. After imaging, it is recommended to re-evaluate the airway. Tracheal intubation might be difficult due to deformation of the airway anatomy, tissue rigidity, and limited access to the mouth, thus tracheotomy must always be considered.

The management of DNI is based on drainage and removal of cause of infection, assisted by administration of broad-spectrum IV antibiotics covering gram positive, gram negative, anaerobic, and β-lactamase producing bacteria. These antibiotics should be subsequently replaced according to culture results. In patients with cellulitis or a small abscess without impending complications, broad-spectrum intravenous antibiotics alone during hospitalization may be sufficient for DNI treatment [11,12,24], while additional surgical exploration might be required if complications occur. Mortality rate from DNI complications can reach as high as 9.3%. [25].

Correspondence
Dr. M. Pesis
Oral and Maxillofacial Surgery unit, Soroka University Medical Center, Beer Sheva 84101, Israel
Phone: (+972-8) 640-0505
email: mp15051982@gmail.com

References

1. Wang LF, Kuo WR, Tsai SM, Huang KJ. Characterization of life threatening deep cervical space infections: a review of one hundred ninety-six cases. *American J Otolaryngol* 2003; 24: 111-17.

2. Prabhu SR, Nirmalkumar ES. Acute fascial space infections of the neck: 1034 cases in 17 years follow up. *Ann Maxillofac Surg* 2019; 9: 118-23.
3. Agarwal AK, Sethi A, Sethi D, Mrig S, Chopra S. Role of socioeconomic factors in deep neck abscess: A prospective study of 120 patients. *Br J Oral Maxillofac Surg* 2007; 45: 553-5.
4. Boscolo RP, Stellin M, Muzzi E. Deep neck space infections: a study of 365 cases highlighting recommendations for management and treatment. *Eur Arch Otorhinolaryngol* 2012; 269: 1241-9.
5. Ungkanont K, Yellon FR, Weissman JL, Casselbrant ML, Gonzalez VH, Bluestone CD. Head and neck space infections in infant and children. *Otolaryngol Head Neck Surg* 1995; 112: 375-82.
6. Huang TT, Liu TC, Chen PR, Tseng FY, Yeh TH, Chen YS. Deep neck infection: analysis of 185 cases. *Head Neck* 2004; 26: 854-60.
7. Hasegava J, Hidaka H, Tateda M. An analysis of clinical risk factors of deep neck infection. *Auris Nasus Larynx* 2011; 38: 101-7.
8. Yilmaz S, Bas B, Ozden B, Selcuk U, Cengel Kurnaz S. Deep neck infection after molar extraction. *J Istanbul Univ Fac Det* 2015; 49 (2): 41-5.
9. Parhiscar A, Harel G: Deep neck abscess. a retrospective review of 210 cases. *Ann Otol Rhinol Laryngol* 2001; 110: 1051-4.
10. Bottin R, Marioni G, Rinaldi R. Deep neck infection: a present day complication. A retrospective review of 83 cases (1998–2001). *Eur Arch Otorhinolaryngol* 2003; 260: 576-9.
11. Marioni G, Rinaldi R, Staffieri C. Deep neck infection with dental origin: analysis of 85 consecutive cases (2000–2006). *Acta Otolaryngol* 2008; 128: 201-6.
12. Eftekharian A, Roozbahany NA, Vaezeafshar R. Deep neck infections: retrospective review of 112 cases. *Eur Arch Otorhinolaryngol* 2009; 266: 273-7.
13. Bakir S, Tanriverdi MH, Gun R, et al. Deep neck space infection: a retrospective review of 173 cases. *Am J Otolaryngol* 2012; 33: 56-63.
14. Kataria G, Saxena A, Bhagat S, et al. Prevalence of odontogenic deep neck space infections (DNSI): a retrospective analysis of 76 cases of DNSI. *Int J Otorhinolaryngol Head Neck Surg* 2015; 1 (1): 11-16.
15. Sethi DS, Stanley RE. Deep neck abscesses: challenging trends. *JLO* 1994; 108: 138-43.
16. Mumtaz RM, Arain AA, Suhail A, Rajput SA, Mohammad A, Nabeel H. Deep neck space infections: retrospective review of 46 patients. *J Cranio Max Dis* 2014; 3 (1): 21-5.
17. Khode SR, Bhat P, Rane S, Dasguota KS. Retrospective analysis of 298 cases of deep neck infections: its diagnosis and management. *Sci J Med Clin Trials* 2013; 103: 1-3.
18. Meher R, Jain A, Sabharwal A, Gupta B, Singh I, Agarwal I. Deep neck abscess: a prospective study of 54 cases. *JLO* 2005; 119: 299-302.
19. Rozkiewicz D, Daniluk T, Sciepuk M, et al. Prevalence rate and antibiotic susceptibility of oral viridans group streptococci (VGS) in healthy children population. *Adv Med Sci* 2006; 51: 191-5.
20. Dwivedi D, Kushwah T, Kushwah M. Antibiotic susceptibility pattern against pathogenic bacteria causing dental caries. *South Asian J Exp Biol* 2011; 1: 31-5.
21. Yadav K, Prakash S, Yadav NP, Sah RS. Multi-drug resistance of bacterial isolates among dental caries patients. *Janaki Med College J Med Sci* 2015; 3: 37-44.
22. Zamiri B, Hashemi SB, Haeshami SH, Rafiee Z, Ehsani S. Prevalence of odontogenic deep head and neck space infection and its correlation with length of hospital stay. *Shiraz Univ Dent* 2012; 13 (1): 29-35.
23. Plaza Mayor G, Martinez-San Millan J, Martinez-Vidal A. Is conservative treatment of deep neck space infections appropriate? *Head Neck* 2001; 23: 126-33.
24. Smith II JL, Hsu JM, Chang J. Predicting deep neck space abscess using computed tomography. *Am J Otolaryngol* 2006; 27: 244-7.
25. Garcia T, Rios M, Paiva J. Predictors of severity in deep neck infections admitted to the intensive care unit. *Anaesth Intensive Care* 2012; 40 (5): 832-7.

Capsule

TRIIM trial to target thymus

Due to the demographic transition, aging human bodies are an increasing liability for health and social systems. The risk of many age-related diseases could be reduced by thymus regeneration to improve immunological protection. In the thymus regeneration, immunorestoration, and insulin mitigation (TRIIM) trial. **Fahy** et al. developed a method to promote thymus function and reverse immunosenescence aging markers in nine men aged 51 to 65 years. The men were treated with recombinant human growth hormone as well as two drugs (dehydroepiandrosterone and metformin) that are used to prevent hyperinsulinemia and the diabetogenic effects of growth hormone. Effects of treatment were measured on immune cells, cytokines, and epigenetic clocks, which monitor changes in DNA methylation and indicate biological age (as distinct from chronological age). Immunological measures improved in the treated men, and epigenetic age regressed by 1.5 years after 1 year of treatment. Larger studies are required to verify the findings.

Aging Cell 2019; 18: e13028

Eitan Israeli

Capsule

Calling healing lesions

Cutaneous leishmaniasis results in skin sores that can be difficult to treat, resulting in further complications. **Farias Amorim** and colleagues performed dual RNA-sequencing of host and parasite gene expression in pretreatment lesional skin biopsies from two cohorts of patients infected with the parasite *Leishmania braziliensis*. A prognostic signature comprising expression of three cytolytic genes plus pathogen load predicted treatment response in both cohorts and could potentially be used to triage patients who are unlikely to respond to conventional treatment as candidates for alternate therapies. This study also provides evidence that inflammasome-mediated interleukin-1β production influences treatment outcome in patients, strengthening the argument that therapies targeting these components could treat cutaneous leishmaniasis.

Sci Transl Med 2019; 11: eaax4204

Eitan Israeli