One Hundred Transhiatal Esophagectomies: A Single-Institution Experience

Guy Pines MD[1], Yoram Klein MD[1], Ehud Melzer MD[2], Efraim Idelevich MD[3], Victor Buyeviz MD[1], Svetlana Machlenkin MD[1] and Hanoch Kashtan MD[1]

[1]Department of Surgery B, [2]Department of Gastroenterology and Liver Diseases and [3]Institute of Oncology, Kaplan Medical Center, Rehovot, affiliated with Hebrew University-Hadassah Medical School, Jerusalem, Israel

ABSTRACT: **Background:** Surgery is considered the mainstay of treatment for esophageal carcinoma. Transhiatal esophagectomy with cervical esophagogastric anastomosis is considered relatively safe with an oncological outcome comparable to that using the transthoracic approach.

Objectives: To review the results of the first 100 transhiatal esophagectomies performed in a single Israeli center.

Methods: The records of all patients who had undergone transhiatal esophagectomy during the period 2003–2009 were reviewed. The study group comprised the first 100 patients. All patients who had undergone colon or small bowel transposition were excluded. Indications for surgery included esophageal cancer, caustic injury and achalasia.

Results: The median follow-up period was 19.5 months. The anastomotic leakage rate was 15% and all were managed successfully with local wound care. The benign stricture rate was 10% and all were managed successfully with endoscopic balloon dilation. Anastomotic leakage was found to be a risk factor for stricture formation. Overall survival was 54%. Response to neoadjuvant therapy was associated with a favorable prognosis.

Conclusions: Transhiatal esophagectomy is a relatively safe approach with adequate oncological results, as long as it is performed in a high volume center.

IMAJ 2011; 13: 428–433

KEY WORDS: transhiatal esophagectomy, esophageal cancer, surgical technique, prognostic factors, neoadjuvant therapy

Surgery is considered the mainstay of treatment for esophageal carcinoma [1]. It is a major procedure that carries a high rate of perioperative morbidity and mortality. Results of esophagectomy are greatly influenced by institution volume [2]. The two most common approaches are the transhiatal and the transthoracic esophagectomy with esophagogastric anastomosis; both are considered relatively safe and have a comparable oncological outcome [3]. The aim of this study was to review the results of the first 100 transhiatal esophagectomies performed in a single Israeli center.

PATIENTS AND METHODS

Since 2003, data of all patients undergoing esophagectomy are being collected in a prospective database. A retrospective analysis of the data was performed.

Institutional review board approval was obtained. We reviewed the records of all patients who had undergone transhiatal esophagectomy during the period 2003–2009. The first 100 patients comprised the study group. Patients who had undergone colon or small bowel transposition were excluded. Indications for surgery included esophageal cancer, caustic injury, and grade IV achalasia.

PREOPERATIVE ASSESSMENT

The preoperative workup for esophageal cancer included clinical examination, endoscopy with biopsies, endoscopic ultrasonography, thoraco-abdominal computerized tomography, and 18F-fluorodeoxyglucose positron emission tomography. Staging was performed according to the 6th American Joint Committee on Cancer/International Union Against Cancer (AJCC/UICC) TNM classification [4].

Patients who presented with locally advanced disease (defined as either uT3 or uN1 disease) were assigned for neoadjuvant therapy. These patients received two cycles of chemotherapy, consisting of cisplatin 80 mg/m^2 as intravenous infusion on day 1 followed by 5-fluorouracil 1000 mg/m^2 as 96-hour continuous infusion on days 1–4, separated by a 3 week interval.

Response to neoadjuvant treatment was assessed after the second treatment cycle. Assessments included endoscopy, EUS, thoraco-abdominal CT scan, and PET-CT imaging. Our routine use of EUS has declined since 2009 due to its poor diagnostic value among patients who had undergone neoadjuvant therapy [5]. Response was evaluated using the standard RECIST protocol (**r**esponse **e**valuation **c**riteria **i**n **s**olid **t**umors) [6]. Patients with either progressive disease or

EUS = endoscopic ultrasonography
PET = positron emission tomography

stable disease were grouped as non-responders. Patients who had either partial response or complete pathological response were grouped as responders. Some patients opted for surgery without preoperative neoadjuvant therapy.

Patients who were operated for non-oncological reasons underwent clinical examination, gastroscopy with biopsies as needed and thoraco-abdominal CT scan. In addition, patients with achalasia underwent upper gastrointestinal series and esophageal manometry.

SURGICAL TECHNIQUE

Patients are positioned supine. A roll created from operative drapes placed transversely across the shoulders helps to extend the neck and improves cervical exposure. A single lumen endotracheal tube is used, and nasogastric tube and Foley catheter are inserted. Central venous access and an arterial line are placed. The patient's neck, chest and abdomen are prepped and draped. An upper midline laparotomy incision is performed. The abdomen is explored. Any suspicious nodules are sent for frozen section analysis to rule out metastatic disease.

Gastric mobilization is performed preserving only the right gastroepiploic arcade. The left gastric vessels are exposed and ligated posteriorly through the lesser sac, or anteriorly through the divided gastrohepatic ligament. Once the stomach is completely mobilized, a Kocher maneuver is performed to ensure the gastric conduit reaches the neck. A gastric tube is fashioned by resecting the lesser curvature using a liner stapler while maintaining the right gastroepiploic arcade. A 5–6 cm width tube is then created. A continues absorbable suture (Vicryl®, Ethicon, Somerville, NJ, USA) is made over the staples line.

The major part of the esophageal mobilization is performed from the abdominal incision, through a widened esophageal hiatus. A blunt dissection is performed to free the thoracic esophagus. The previously placed nasogastric tube aids in staying in the right plane while dissecting the esophagus. The upper portion of the esophageal mobilization is completed after a left cervical incision is created along the anterior aspect of sternocleidomastoid muscle, and the distal cervical esophagus is encircled. The esophagus is divided and the anvil of a circular stapler (CDH® 25 or 29 circular stapler, Ethicon Endo-Surgery, Cincinnati, OH, USA) is secured to the proximal end with a purse-string suture. The esophagus is delivered through the abdominal incision.

After esophagectomy and tubulization of the stomach, the stomach is mobilized through the posterior mediastinum up to the neck. Esophagogastric anastomosis is done end-to-side by using a circular stapler. A 2–2.5 cm gastrostomy is made on the anterior gastric wall. The anvil of the stapler is placed in the proximal esophageal stump and secured with a purse-string suture. The shaft of the stapler is inserted through the gastrostomy and the anastomosis is performed [Figure 1]. The gastrostomy is then closed using a liner stapler (TCL® 55, Ethicon, Stockholm, Sweden). This stapler line is buttressed with Lambert-type interrupted sutures with 3-0 vicryl. In selected cases in which this technique is thought to cause excessive tension, hand-sewn, one-layer, end-to-end anastomosis is performed using interrupted absorbable sutures (Monocryl or Vicryl, Ethicon).

Figure 1. The body of a circular stapler is introduced through the previously fashioned gastrotomy, and the anastomosis is completed by firing the staple

A Jackson-Pratt drain is routinely placed near the anastomosis. A 16 F nasogastric tube is passed by the anesthetist and advanced downward with the surgeon's manual guidance through the intrathoracic stomach to the antrum for postoperative gastric decompression. Patients underwent either pyloromyotomy, pyloroplasty or no pyloric intervention at the surgeon's discretion. A feeding jejunostomy is routinely placed at the end of the surgery. All operations were performed by a single surgical team.

POSTOPERATIVE MANAGEMENT AND OUTCOME ASSESSMENT

Patients are gradually given enteral nutrition on the first day following surgery. The nasogastric tube is removed on the fifth postoperative day and oral feeding is gradually instituted. Patients are discharged when they are able to tolerate oral feeding with adequate caloric intake. The feeding jejunostomy is removed at the first clinic visit.

Data regarding major postoperative complications were collected. The major surgical complications included anastomotic leak, chylothorax, empyema and any other complication requiring reoperation. Major non-surgical complications included respiratory failure, myocardial infarction, and pulmonary emboli.

Leakage was either diagnosed radiologically by an upper gastrointestinal series or clinically by appearance of turbid

fluid in the cervical drain with high amylase levels. We performed routine upper gastrointestinal series on the 5th or 6th postoperative day in all patients for occult anastomotic leak until 2008. This routine was abandoned by our team due to poor diagnostic value [7].

Upper gastrointestinal series is performed in patients in whom delayed gastric emptying is suspected either due to a large amount of non-bilious content via the nasogastric tube or to recurrent vomiting. When gastric outlet obstruction is diagnosed an upper endoscopy is performed with four-quadrant botulinum toxin injection to the pylorus. In the event of delayed gastric emptying, the patient is started on pro-kinetics (erythromycin base). Perioperative mortality was defined as either 30 day mortality or in-hospital mortality.

Patients with microscopic surgical margin involvement (R1) underwent postoperative chemoradiotherapy. The total dose of radiation was 6000 cGy, 30 fractions of 200 cGy each, 5 days a week for 6 weeks (6000 cGy/200 cGy/30/5weeks). Patients who had undergone R0 resection received no adjuvant therapy.

In addition to the TNM staging we calculated the metastatic lymph node ratio by dividing the number of metastatic lymph nodes and the total number of lymph nodes harvested.

A benign anastomotic stricture was defined as a symptomatic stenosis in the absence of recurrent tumor that necessitated dilatation [8]. Dilatations were performed using a pneumatic balloon dilator that was passed through an endoscope (Controlled Radial Expansion Dilatation Balloon) (Boston Scientific Microvasive, Cork, Ireland).

STATISTICAL ANALYSIS

Associations between dichotomies were tested by Fisher's exact test. Kaplan-Meier functions were constructed and differences in survival were tested by log rank test. Logistic regression was used for the effect of the lymph node ratio – the ratio of positive lymph nodes to the total number of nodes removed over survival, as a continuous variable. Chi-square test was used after subgrouping lymph node ratios. A Cox regression model including the variables with a statistically significant univariate association with survival was constructed in a backwards stepwise likelihood ratio.

RESULTS

Patients' characteristics are presented in Table 1. The median follow-up period was 19.5 months. The overall long-term survival rate was 54%. The perioperative mortality rate was 5% [Table 2]. The mean number of harvested lymph nodes was 11.7 ± 7.7. Sixty-two patients had undergone R0 resection. Five patients had microscopic involvement of the surgical margins (R1) and 27 patients had microscopic involvement of the circumferential margins. These patients were assigned to adjuvant therapy.

The overall major non-surgical and surgical complications rate was 42% (13% and 34% respectively). Anastomotic leakage occurred in 15% of the study population. Only one patient was reoperated due to anastomotic leak because of mediastinitis and septic shock. He was discharged from the hospital without sequelae after a complicated postoperative course, with prolonged mechanical ventilation. All other patients were managed successfully by local wound care and supportive treatment.

The gastric outlet obstruction rate was 4%. All patients were treated with botulinum toxin injection, but one patient underwent pneumatic pyloric dilation due to failure of this procedure. The delayed gastric emptying rate was 9% and all managed successfully with pro-kinetics. No correlation was found between pyloric drainage procedure and either gastric outlet obstruction or delayed gastric emptying.

The median hospital stay was 15 days (mean 20 ± 14.5 days). Of the 100 patients 41 died during the study period

Table 1. Patient characteristics

N	**100**
Male/Female ratio	71/29
Age (yrs, mean)	64
Surgical indication	
Cancer	
Squamous cell carcinoma	26
Adenocarcinoma	69
Caustic injury	3
Achalasia	2
Lymph nodes	
No. of harvested lymph nodes+	11.7 ± 7.7
Pathological stage	
0	4
I	21
IIa	28
IIb	7
III	32
Neoadjuvant therapy*	53
Progressive disease	2
Stable disease	26
Partial response	20
Complete response	3
Adjuvant Therapy	5

*Response to neoadjuvant therapy was defined according to standard RECIST protocol. Data were unavailable for 2 patients

Table 2. Summary of mortality causes and risk factors

Patient	Age (yrs)	Risk factors	Oncological stage	S/P Neoadjuvant therapy	Postoperative complications	Leak	Cause of death	Postoperative day of death
I	82	Hypertension, NIDDM	III	No	Pneumonia	Yes§	Lethal arrhythmias	17
II	85	–	IIa	No	Septic shock, pneumonia	No	Respiratory failure	26
III	82	Hypertension, asthma	IIb	Yes	Chylothorax, conservative Tx	No	M/P massive pulmonary embolism	17
IV	70	Heavy smoker, COPD†, hypertension	IIa	Yes	Prolonged mechanical ventilation due to COPD	No	Sudden cardiac arrest	10
V	70	Hypertension	I	No	Suspected pancreatico-pleural fistula	No	Respiratory failure	31

NIDDM = non-insulin-dependent diabetes mellitus, COPD = chronic obstructive pulmonary disease
§The leak was controlled and drained completely through the cervical drain. Sepsis workup did not reveal any signs of mediastinitis
†Patient had a mild obstructive pattern in preoperative lung function tests

(perioperative mortality excluded), 40 of whom were operated for cancer. The median survival was 14.8 months in this group. Median follow-up was 25 months among the patients who survived.

A total of 53 patients had undergone neoadjuvant chemotherapy. Data were unavailable for two patients. Twenty-three patients responded to neoadjuvant therapy versus 28 patients who did not [Table 1]. Response to neoadjuvant therapy was associated with better prognosis [Figure 2]. Twenty-three of the patients who did not respond to neoadjuvant therapy died during the study period versus 5 of the patients who responded ($P < 0.05$).

Mean metastatic lymph node ratio was lower among patients who responded to neoadjuvant therapy compared to patients who did not (0.13 ± 0.2 vs. 0.35 ± 0.3, $P < 0.05$).

Recurrent laryngeal nerve paralysis accounted for 12 cases, all of which were unilateral (left). All managed successfully with expectant therapy. Benign anastomotic stricture rate was 10%; all of these patients were operated for cancer. Of the patients who suffered from anastomotic leakage 33% developed anastomotic stricture compared to 6% of patients without anastomotic leakage ($P = 0.01$). All were managed successfully with endoscopic balloon dilation.

Figure 2. Survival curves of patients who responded to neoadjuvant therapy compared with patients who did not respond ($P = 0.002$)

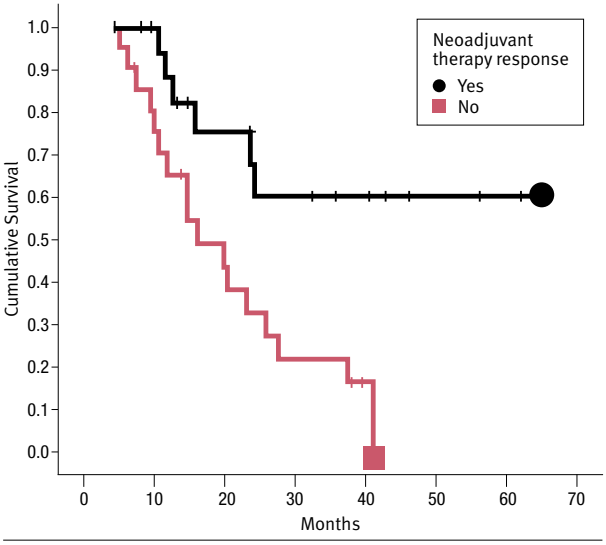

DISCUSSION

Esophagectomy is a major procedure that carries a high morbidity and mortality rate. Institutional outcome of this procedure has been shown to be volume-dependent [2], with 9.4% difference of adjusted mortality between low volume centers (two to four esophagectomies per year, 17.8% mortality) and very high volume centers (> 19 esophagectomies per year, 8.4% mortality). The perioperative mortality rate in our institution is consistent with very high volume centers.

Anastomotic failure is considered the most common major surgical complication after transhiatal esophageal resection, with leakage rates of up to 25% [9]. In our series the anastomotic leakage rate was 15%. No association was found between leakage rates and anastomotic technique, TNM stage or any other preoperative risk factor. Several factors may contribute to the development of anastomotic leak, but technical errors and gastric tip ischemia are considered to be the most important [10,11]. Jacobi and team [12] reported progressively diminishing gastric submucosal tissue oxygen tension with each step of gastric mobilization: ligation of the short gastric and gastroepiploic vessels, ligation of the left gastric artery, and pull-up of the gastric tube. Several authors have proposed different strategies in an attempt to minimize the gastric conduit ischemia and thus reduce the leakage rate and late stricture formation [13], including selection of patients with preoperative albumin > 32 g/L, minimizing intraoperative blood loss by using an interrupted suture technique, and insertion of feeding jejunostomy for immediate postoperative enteral nutrition. Preoperative ischemic gastric conditioning has been described to reduce anastomotic leakage rates [14]. Others have suggested that

retaining as much stomach as possible is preferred to creating a gastric tube [15]. In our opinion, mechanical staplers, compared to hand-sewn anastomosis, simplify the technical performance of creating the esophagogastric anastomosis and may reduce the number of technical errors, although they do not influence the leakage rate.

Delayed gastric emptying occurred in 13% of this patient group. Delayed gastric emptying is a fairly common complication after esophagectomy with gastric conduit (13%–15.3%) [16,17]. The pylorus drainage procedure does not seem to reduce the incidence of this complication [16] and is associated with a small but definable morbidity, such as leakage and dumping syndrome. Delayed gastric emptying can usually be managed endoscopically with either balloon dilation or intrapyloric botulinum toxin injection [18]. In rare cases these measures fail and a pyloroplasty is required. Our experience shows that the pylorus drainage procedure does not influence the delayed gastric emptying rate, and with an effective and safe postoperative endoscopic treatment may not be warranted. In cases of delayed gastric emptying due to postoperative gastroparesis, pro-kinetic agents, such as erythromycin, are an effective treatment [19].

The most important long-term sequel of cervical esophagogastric anastomosis is benign anastomotic stricture, whose rate is much higher than with intrathoracic anastomosis. According to our data, anastomotic leakage was found to be a risk factor for late stricture development, as found also by other authors [20,21]. Briel et al. [22] reported a randomized controlled trial of 393 patients who underwent esophagectomy. Reconstruction was done using gastric conduit (n=230) or colon interposition (n=163). The stomach or colon was anastomosed to the cervical esophagus using a hand-sewn technique. Three major risk factors for anastomotic stricture were found: conduit ischemia, anastomotic leak, and overweight. All patients who developed anastomotic stricture were treated successfully with endoscopic balloon dilations. Some patients underwent repeated dilations due to persistent stricture. None of these patients had undergone surgical intervention.

Controversy exists regarding the management of patients who present with locally advanced disease. Bedenne et al. [23] reported a randomized controlled trial (FFCD 9201 trial) comparing chemoradiation alone versus chemoradiation following surgery among 259 patients with locally advanced esophageal carcinoma (T3N0-N1M0) who were eligible for surgery. No oncological benefit from the addition of surgery following chemoradiation was found in this patient group. Stahl and co-authors [24] reported on 172 patients with squamous cell carcinoma who were treated with induction chemotherapy followed by either chemoradiation or surgery. All patients, not only the responding patients, were randomly assigned. Surgery in non-responders to chemoradiotherapy was associated with long-term survival in some patients, indicating the potential utility of surgery as a salvage procedure. Alum and collaborators [25] reported a randomized controlled trial of preoperative chemotherapy followed by surgery and surgery alone among 802 patients with esophageal carcinoma. A 5 year survival benefit was observed in the neoadjuvant arm (23% vs. 17.1%), regardless of histological tumor type. The effect of preoperative chemotherapy appears to specifically influence the extent of surgery by reducing tumor volume and increasing potential for curative (R0) resection. Our data indicate that response to neoadjuvant therapy is associated with better prognosis. In our opinion, surgery is still the mainstay of treatment for esophageal carcinoma. Patients with locally advanced disease should be assigned to neoadjuvant therapy.

CONCLUSIONS

Esophageal carcinoma is a relatively rare and lethal disease. Transhiatal esophagectomy offers a relatively safe approach with adequate oncological results, as long as it is performed in a high volume center. In our opinion, patients presenting with locally advanced disease should be assigned to neoadjuvant therapy.

Acknowledgment

The authors wish to thank Mario Baras, PhD, for his assistance in the statistical analysis.

Corresponding author:
Dr. H. Kashtan
Dept. of Surgery B, Kaplan Medical Center, P.O. Box 1, Rehovot 76100, Israel
Phone: (972-8) 944-1293
Fax: (972-8) 944-1790
email: hkashtan@clalit.org.il

References

1. Wu PC, Posner MC. The role of surgery in the management of oesophageal cancer. *Lancet Oncol* 2003; 4 (8): 481-8.
2. Birkmeyer JD, Siewers AE, Finlayson EV, et al. Hospital volume and surgical mortality in the United States. *N Engl J Med* 2002; 346 (15): 1128-37.
3. Chang AC, Ji H, Birkmeyer NJ, Orringer MB, Birkmeyer JD. Outcomes after transhiatal and transthoracic esophagectomy for cancer. *Ann Thorac Surg* 2008; 85 (2): 424-9.
4. Sobon LH WC, ed. UICC TNM Classification of Malignant Tumors. 6th edn. New York: Wiley, 2002.
5. Machlenkin S, Melzer E, Idelevich E, Ziv-Sokolovsky N, Klein Y, Kashtan H. Endoscopic ultrasound: doubtful accuracy for restaging esophageal cancer after preoperative chemotherapy. *IMAJ Isr Med Assoc J* 2009; 11 (3): 166-9.
6. Eisenhauer EA, Therasse P, Bogaerts J, et al. New response evaluation criteria in solid tumours: revised RECIST guideline (version 1.1). *Eur J Cancer* 2009; 45 (2): 228-47.
7. Pines G, Buyeviz V, Machlenkin S, Klein Y, Laor A, Kashtan H. The use of circular stapler for cervical esophagogastric anastomosis after esophagectomy: surgical technique and early postoperative outcome. *Dis Esophagus* 2009; 22 (3): 274-8.
8. Berrisford RG, Page RD, Donnelly RJ. Stapler design and strictures at the esophagogastric anastomosis. *J Thorac Cardiovasc Surg* 1996; 111 (1): 142-6.
9. Hsu HH, Chen JS, Huang PM, Lee JM, Lee YC. Comparison of manual and mechanical cervical esophagogastric anastomosis after esophageal resection

for squamous cell carcinoma: a prospective randomized controlled trial. *Eur J Cardiothorac Surg* 2004; 25 (6): 1097-101.

10. Urschel JD. Esophagogastrostomy anastomotic leaks complicating esophagectomy: a review. *Am J Surg* 1995; 169 (6): 634-40.
11. Urschel JD. Gastric conditioning. *Recent Results Cancer Res* 2000; 155: 135-44.
12. Jacobi CA, Zieren HU, Zieren J, Muller JM. Is tissue oxygen tension during esophagectomy a predictor of esophagogastric anastomotic healing? *J Surg Res* 1998; 74 (2): 161-4.
13. Dewar L, Gelfand G, Finley RJ, Evans K, Inculet R, Nelems B. Factors affecting cervical anastomotic leak and stricture formation following esophagogastrectomy and gastric tube interposition. *Am J Surg* 1992; 163 (5): 484-9.
14. Varela E, Reavis KM, Hinojosa MW, Nguyen N. Laparoscopic gastric ischemic conditioning prior to esophagogastrectomy: technique and review. *Surg Innov* 2008; 15 (2): 132-5.
15. Collard JM, Tinton N, Malaise J, Romagnoli R, Otte JB, Kestens PJ. Esophageal replacement: gastric tube or whole stomach? *Ann Thorac Surg* 1995; 60 (2): 261-6; discussion 267.
16. Lanuti M, de Delva PE, Wright CD, et al. Post-esophagectomy gastric outlet obstruction: role of pyloromyotomy and management with endoscopic pyloric dilatation. *Eur J Cardiothorac Surg* 2007; 31 (2): 149-53.
17. Fok M, Cheng SW, Wong J. Pyloroplasty versus no drainage in gastric replacement of the esophagus. *Am J Surg* 1991; 162 (5): 447-52.
18. Tcherniak A, Kashtan DH, Melzer E. Successful treatment of gastroparesis following total esophagectomy using botulinum toxin. *Endoscopy* 2006; 38 (2): 196.
19. Burt M, Scott A, Williard WC, et al. Erythromycin stimulates gastric emptying after esophagectomy with gastric replacement: a randomized clinical trial. *J Thorac Cardiovasc Surg* 1996; 111 (3): 649-54.
20. Rice TW. Anastomotic stricture complicating esophagectomy. *Thorac Surg Clin* 2006; 16 (1): 63-73.
21. Orringer MB, Marshall B, Iannettoni MD. Eliminating the cervical esophagogastric anastomotic leak with a side-to-side stapled anastomosis. *J Thorac Cardiovasc Surg* 2000; 119 (2): 277-88.
22. Briel JW, Tamhankar AP, Hagen JA, et al. Prevalence and risk factors for ischemia, leak, and stricture of esophageal anastomosis: gastric pull-up versus colon interposition. *J Am Coll Surg* 2004; 198 (4): 536-41; discussion 541-2.
23. Bedenne L, Michel P, Bouche O, et al. Chemoradiation followed by surgery compared with chemoradiation alone in squamous cancer of the esophagus: FFCD 9102. *J Clin Oncol* 2007; 25 (10): 1160-8.
24. Stahl M, Stuschke M, Lehmann N, et al. Chemoradiation with and without surgery in patients with locally advanced squamous cell carcinoma of the esophagus. *J Clin Oncol* 2005; 23 (10): 2310-17.
25. Allum WH, Stenning SP, Bancewicz J, Clark PI, Langley RE. Long-term results of a randomized trial of surgery with or without preoperative chemotherapy in esophageal cancer. *J Clin Oncol* 2009; 27 (30): 5062-7.