Jejuno-Ileal Diverticulosis with Complications: Computed Tomography Imaging

Osnat Halshtok MD and Michal Amitai MD

Department of Diagnostic Imaging, Sheba Medical Center, Tel Hashomer, affiliated with Sackler Faculty of Medicine, Tel Aviv University, Ramat Aviv, Israel

KEY WORDS: diverticulosis, diverticulitis, small bowel, jejunum, ileum

IMAJ 2011; 13: 384–385

A 63 year old woman was admitted to the emergency room with abdominal pain. Physical examination revealed tenderness in the lower abdomen, mainly on the right side. There was no fever or leukocytosis. A computed tomography scan performed for suspected appendicitis showed a normal appendix and several distal jejunal diverticula in close proximity to each other in the left abdomen [Figure 1]. Thickening of the intestinal wall and free air bubbles were observed adjacent to the diverticulum [Figures 2 and 3]. Apparently one or more of the diverticula had perforated. The patient was conservatively treated, and a CT scan performed two and a half weeks later disclosed the presence of the diverticula, but without wall thickening or free air.

Non-Meckelian diverticulosis of the small bowel comprises thin-walled sacculations that consist of mucosa, submucosa and occasionally a thin layer of serosa without muscle, classifying it as a pseudodiverticulum [1]. These diverticula are almost always located on the mesenteric border, at the site of entry of the vasa recta, which is a locus minoris resistentiae due to intraluminal pressure. Their prevalence decreases distally, further away from the ligament of Treitz. Nearly 80% of these diverticula occur in the jejunum, 15% in the ileum and 5% in both [2]. They can present either as solitary or as multiple lesions; the latter are more common.

The cause of the condition is unknown and is perhaps multifactorial. It may be the result of smooth-muscle abnormalities, abnormalities in peristalsis, or high segmental intraluminal pressures. The condition is rare and the exact prevalence is unknown, but its complications are not infrequent [3]. When comparing jejunal with duodenal diverticulosis, jejunal diverticulosis is nearly four times more likely to develop complications and nearly 18 times more likely to perforate and develop abscesses [2].

Most patients are asymptomatic. When symptoms appear, they usually reflect associated complications. The most common symptoms are non-specific epigastric or peri-umbilical pain or a bloating sensation [2]. Complications include abdominal pain in the absence of other complications, hematochezia, melena, or obscure bleeding that leads to iron deficiency anemia. Diverticulitis, such as in this case, with perforation or localized abscess, may lead to intestinal obstruction, strictures and adhesions [1].

Figure 1. Small bowel diverticula: A 63 year old woman presented with abdominal pain. Axial CT shows a soft tissue window. The white arrow indicates a small bowel diverticulum, and the black arrowheads point to the neck of the diverticulum

Figure 2. Perforated small bowel diverticula in the same patient. Axial CT shows a soft tissue window. The black arrow demonstrates a small bowel diverticulum and the white arrows show free air due to perforation

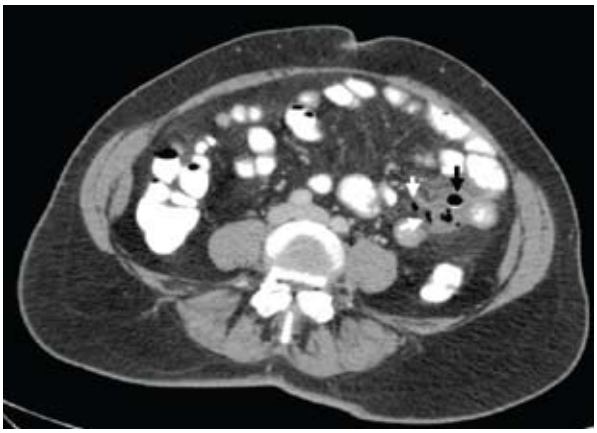

Figure 3. Perforated small bowel diverticula in the same patient. Coronal CT shows a soft tissue window. The white arrow indicates a small bowel diverticulum and the white arrowheads show free air due to perforation

The treatment of complications consists of surgical resection with primary anastomosis. Other available procedures are simple closure or excision, but they are associated with a threefold mortality rate. Even after successful conservative treatment, such as in the case presented, resection is still recommended to prevent recurrence or other complications [1,2].

Corresponding author:
Dr. O. Halshtok
Dept. of Diagnostic Imaging, Sheba Medical Center, Tel Hashomer 52621, Israel
Phone: (972-3) 530-2530
Fax: (972-3) 535-7315
email: osnatx@gmail.com

References

1. Makris K, Tsiotos GG, Stafyla V, et al. Small intestinal nonmeckelian diverticulosis. *J Clin Gastroenterol* 2009; 43 (3): 201-7.
2. Kassahun WT, Fangmann J, Harms J, et al. Complicated small-bowel diverticulosis: a case report and review of the literature. *World J Gastroenterol* 2007; 13 (15): 2240-2.
3. Leiba M, Konen E, Sidi Y. Extensive diverticulosis of the small intestine. *IMAJ Isr Med Assoc J* 2003; 5 (10): 756.