IMAJ • VOL 13 • MARCH 2011

Magnetic Resonance Enterography: 4 Years Experience in a Tertiary Medical Center

Shai Shrot MD, Eli Konen MD, Marjorie Hertz MD and Michal Amitai MD

Department of Diagnostic Imaging, Sheba Medical Center, Tel Hashomer, affiliated with Sackler Faculty of Medicine, Tel Aviv University, Ramat Aviv, Israel

ABSTRACT: **Background:** Assessment of small intestinal disease remains a challenge for both clinicians and radiologists. Modern magnetic resonance enterography (MRE) is a non-radiation modality that can demonstrate both intestinal wall pathologies and extraluminal lesions.

Objectives: To analyze the results of 213 MRE scans performed since 2005.

Methods: Consecutive MRE scans performed in our academic medical center between December 2005 and November 2009 were reviewed for patients' demographic data, indications for the examination, and main imaging findings. The imaging signs recorded were mural changes, intraluminal filling defects as well as mesenteric and extraintestinal inflammatory findings.

Results: During the study period 213 MRE scans were performed; 70% of them for proven or suspected Crohn's disease (CD) of the small bowel. Another indication was small bowel neoplasm (6% of the scans). Bowel wall thickening and enhancement were seen in 60% and 53% of MRE scans, respectively. Mesenteric involvement was found in 52% of the patients. Incidental extraintestinal findings were detected in 17% of the scans. In 22% of the scans there was no pathological finding.

Conclusions: In our 4-year clinical experience with MRE this non-invasive and non-radiating modality proved to be a reliable technique for the evaluation and long-term follow-up of small bowel pathologies. The most common clinical indication was the evaluation of Crohn's disease. With physicians' increased awareness, the use of MRE in the evaluation of other small bowel pathologies such as neoplasm and celiac disease will increase.

IMAJ 2011; 13: 172–177

KEY WORDS: small bowel, Crohn's disease, celiac disease, magnetic resonance enterography, lymphoma

Accurate assessment of small intestinal disease remains a challenge for both clinicians and radiologists. Until a decade ago, the modality most used to examine the small bowel in its entirety was barium-based techniques, such as small bowel follow-through. Advances in technology have allowed cross-sectional imaging techniques to play a larger role in small bowel imaging. Computed tomography and magnetic resonance imaging, both non-invasive techniques, can demonstrate intestinal wall pathology and extraluminal lesions.

CT enterography can obtain high-resolution images and is widely used today for small bowel imaging. However, it exerts a not insignificant cumulative amount of lifetime radiation exposure dose in patients in need of repeated studies over years. Recently, the impact of CT radiation dose on malignancy in the overall population and especially in children was found to be rising [1].

The absence of ionizing radiation is an important advantage of magnetic resonance enterography, especially in younger patients with Crohn's disease and polyposis syndromes who may require frequent imaging for surveillance. Other important advantages of MR as compared to CT are better soft tissue contrast resolution, the ability to acquire multiplanar images (necessary for imaging the small bowel), and the fact that it can be performed in pregnant women without concern for radiation insult to the fetus. Another advantage is the use of gadolinium contrast agents in patients who have iodine contrast allergy or mild to moderate renal insufficiency [2]. Gastrointestinal MRI (MRE) is accepted today as a complementary study to endoscopic techniques that include double balloon endoscopy and wireless capsule endoscopy. Both modalities (DBE and WCE) are able to demonstrate mucosal lesions; however, WCE is limited in estimating the location of a lesion along the small bowel and is contraindicated in patients suspected of bowel stricture or obstruction, while DBE has limited ability to visualize mid-small bowel segments distant from proximal jejunum or terminal ileum.

We present our experience with MRE, discuss the main clinical indications and imaging findings and review the literature to date.

PATIENTS AND METHODS

The study protocol was approved by our institutional review board. All patients who underwent MRE in our academic medi-

MRE = magnetic resonance enterography

DBE = double balloon endoscopy
WCE = wireless capsule endoscopy

cal center between December 2005 and November 2009 were included in the study. Patients' demographic data, indications for the examination and imaging findings were recorded. These findings included mural changes such as thickening of the wall of the small and large bowel (> 3 mm), post-gadolinium bowel wall enhancement, pre-stenotic dilatation (> 3 cm), and intraluminal filling defects or intussusception. Mesenteric findings such as mesenteric fat hypertrophy, hyperemia and lymphadenopathy and the presence of extraintestinal inflammatory findings such as sinus tract, fistula, phlegmon and intra-abdominal abscess were also recorded. All data were processed in SPSS version 14. Discrete variables are presented as mean and percentage.

MRE was performed on a 1.5T GE Sigma HDx MR System version 14. Patients were asked to drink 1000 ml of mannitol 5% 60 minutes prior to the examination, followed by intravenous injection of glucagon (1 mg; GlucaGen® HypoKit, Novo Nordisk A/S, Denmark) and gadolinium (0.1 mmol/kg; gadoterate dimeglumine, Dotarem®, Guerbet, France). The MRE protocol included axial, coronal and sagittal FIESTA (TR/TE 4.3/1.9 ms), axial and coronal 2D SSFSE T2W (TR/TE 1680-3200 /92.7 ms), axial and coronal FSPGR FS BH (TR/TE 150/1.3 ms), and coronal LAVA (TR/TE 4.2/2.1 ms) pre- and post-gadolinium injection. Field of view 32–40 cm with slice width 3.6–6 mm was used.

RESULTS

A total of 213 MRE scans were performed in 195 patients (97 males and 98 females). Mean patient age was 31 years (range 7–78 years, SD 13.2). Two-thirds of the subjects were outpatients and one-third inpatients.

INDICATIONS FOR MRE

Clinical indications are presented in Table 1. The major indication was evaluating patients with known Crohn's disease (114 examinations, 53%) and patients with suspected CD (37 examinations, 17%). Other important indications were suspected space-occupying lesions in the small bowel, with or without polyposis syndrome (12 examinations, 5.6%).

MRE FINDINGS

The main finding was small and/or large bowel wall thickening (127/213 scans, 60%). The small bowel was affected twice as often as the large bowel, causing pre-stenotic dilatation in 38%. The second most common finding was post-gadolinium enhancement of the diseased segments [Figure 1A]. Mesenteric involvement, which included fat hypertrophy, lymphadenopathy or hyperemia, was found in 52% of the scans. Mesenteric fat hypertrophy and lymphadenopathy were seen equally often. Extraintestinal inflammatory findings such as sinus tract, fistula, phlegmon or abscess were seen in 22% of scans [Table 2]. Forty-six of the 213 examinations (22%) were normal.

CD = Crohn's disease

Table 1. Clinical indications for MRE, 213 scans (195 patients)

Clinical indication	No. of examination (%)	
Evaluation of Crohn's disease	114	(53)
Suspected Crohn's disease	37	(17)
Abdominal pain – investigation	12	(6)
Polyposis syndrome	6	(3)
Suspected space-occupying lesion	6	(3)
Suspicion/evaluation of ulcerative colitis	5	(2)
Post-surgery investigation	3	(1)
Bowel obstruction	3	(1)
Cystic fibrosis	2	(1)
Celiac disease	1	(<1)
Protein-losing enteropathy	1	(<1)
Rectal bleeding	1	(<1)
Investigation for recurrent intussusception	1	(<1)
Internal hernia	1	(<1)
Suspected angioedema	1	(<1)
Colonic SOL surveillance (patient with iodine allergy)	1	(<1)
Suspected appendicitis	1	(<1)
Unknown (no clinical data were available)	17	(8)
Total	213	(100)

SOL = space-occupying lesion

In the CD patient group (151 examinations) we found more cases of small bowel wall thickening (72%) and post-gadolinium mural enhancement (65%) than in the non-CD group (32% and 21%, respectively, for both differences, chi-square test, $P < 0.001$). Evidence of mesenteric involvement was significantly more frequent in CD patients compared to non-CD patients (63% vs. 36%, chi-square test, $P < 0.001$). Complications of CD, including fistulas, phlegmons and intra-abdominal abscesses, were seen in 45 examinations in the CD group (30%), significantly more often than extra-intestinal inflammatory findings in the non-CD group (5%, chi-square test, $P < 0.001$). The main imaging findings in CD patients are demonstrated in Figure 1.

In patients suspected of having small bowel space-occupying lesions (n=12) we found several intraluminal filling defects in three scans [Figure 2A], and small bowel thickening proved to be a tumor in another six MRE scans [Figure 2B]. In three of these patients mesenteric lymphadenopathy was found. In three scans no space-occupying lesions were detected.

Eight patients underwent MRE during pregnancy, five of whom were referred for abdominal pain and two for

Figure 1. MRE of a 33 year old woman with Crohn's disease. **[A and B]** Coronal T1 images after gadolinium injection with fat suppression demonstrate intense enhancement of involved jejunal wall (arrowhead) and mesenteric hyperemia "comb sign" (arrow). **[C]** Coronal T2 image demonstrates jejunal wall thickening with significant narrowing of the lumen (dotted arrow). **[D]** Coronal T1 images with fat suppression demonstrate reactive lymph nodes with intense enhancement post-gadolinium injection in the mesenteric root (*)

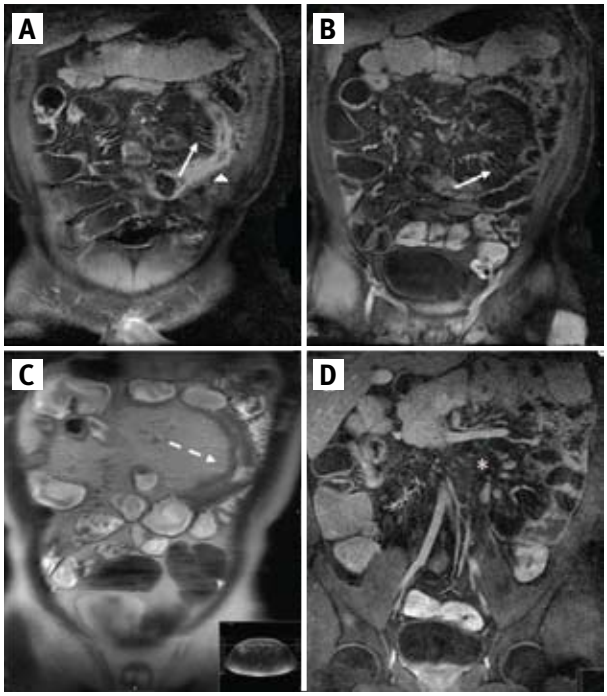

CD evaluation. The main findings in CD pregnant women were phlegmon, abscess and bowel wall thickening. Among the patients with abdominal pain, one post-appendectomy patient was referred for suspected phlegmon and the other four to rule out appendicitis. Appendicitis was not detected in any of these patients, but marked right-sided hydronephrosis was seen in three of them, probably secondary to pregnancy and perhaps the cause of the abdominal pain. The last patient had MRE for exacerbation of ulcerative colitis.

Incidental extraintestinal findings were detected in 37 studies (17% of 213 scans), of which 13 were in the urinary tract (hydronephrosis, renal cysts, bladder diverticula), 11 were in the female genital organs (ovarian cysts, adenomyosis and uterine myoma), 7 scans showed gallbladder stones and 6 scans demonstrated liver hemangiomas or cysts.

DISCUSSION

In recent years MRE has emerged as a useful imaging technique in small bowel diseases. The main clinical indication for MRE in our study group was suspected or proven Crohn's disease. This is consistent with a previous report in which CD was the indication for MRE scan in 62% of patients [3]. However, McKenna et al. [4], reported that proven or suspected CD was the indication for MRE in only 37% of their patients. The second most common indication for MRE in our series was suspected small bowel neoplasm (6% of scans). This indication was significantly lower than in other series (15% and 27%, respectively) [3,4]. Lohan and colleagues [5] reported that in 4.4% of 225 consecutive MRE scans the patients suffered from small bowel lymphoma, half of them secondary to celiac disease.

Table 2. Main imaging findings in 213 MRE scans (195 patients)

Main finding	Frequency (of 213 examinations)	(%)
Small bowel wall thickening	127	(60)
Post- contrast increased enhancement of the bowel wall	114	(53)
Pre-stenotic dilatation	80	(38)
Mesenteric fat hypertrophy	64	(30)
Mesenteric lymphadenopathy	61	(29)
Large bowel wall thickening	54	(25)
Intraabdominal sinus tract or fistula	39	(18)
Mesenteric hyperemia	36	(17)
Phlegmon	20	(9)
Intraabdominal abscess	16	(7)
Intraluminal filling defects	5	(2)
Intussusception	4	(2)
Stomach or duodenal wall thickening	3	(1)

Only one of the 195 patients in our study was referred for celiac disease, in contrast to other reports (11–15%) [3,4]. In Israel celiac disease may be under-diagnosed, as pointed out in a study of 850 healthy subjects in whom overt celiac disease was diagnosed prior to recruitment in 0.12% and positive serology was found in 1.1% [6]. This lack of awareness regarding the possibility of celiac disease may be the reason for the rare referral of celiac patients to MRE in Israel. Another reason may be the limited availability of MR equipment and the relatively high cost of examination.

Regarding small bowel obstruction, none of our patients underwent MRE during acute presentation (although they had MRE later on) to evaluate the cause of their SBO. Only a few studies have shown the role of MRE in detecting SBO. Beall et al. [7] conducted a prospective evaluation of patients with clinical evidence of bowel obstruction using MRI and CT. The cause of obstruction was correctly diag-

SBO = small bowel obstruction

nosed by MRI in 95% and by CT in only 71% of the cases. MRI has also been shown to have a high sensitivity for characterization of malignant versus benign strictures in the small bowel as the cause of the SBO [8]. Findings suggestive of malignant obstruction included the presence of an obstructing mass, focal mural thickening, and peritoneal thickening and enhancement.

Bowel wall thickening and enhancement were very common MRE imaging findings in our study, as also previously reported [2]. Luminal narrowing and associated prestenotic dilatation were the third most common finding, easily recognized in all sequences of MRE.

In CD patients, patchy areas of wall thickening and high signal intensity were seen along affected small bowel segments with a pattern similar to "cobblestoning." Mesenteric involvement, which includes mesenteric fat hypertrophy, hyperemia or lymphadenopathy, was quite common; hyperemia was demonstrated as increased blood flow in the vasa recta in areas of active inflammation ("comb sign") [Figure 1B]. MRE was also highly sensitive in assessing complications of CD, either of penetrating disease such as fistulas, phlegmons or abscesses, or of fibrostenotic disease such as stenotic segments with pre-stenotic dilatation. These findings indicate inflammatory activity, which is an important guideline to determine whether the treatment should be medical or surgical. Although wall thickening and enhancement can appear as fibrotic changes without any active inflammation, the presence of hyperemia, intramural edema (high T2 signal of bowel wall), transmural ulceration, and wall thickening with enhancement indicate inflammatory activity [9-11].

In evaluating patients with CD, MRE has proven to have better sensitivity and specificity compared to conventional small bowel follow-through studies [12,13]. MRE was found to have a clear advantage over conventional SBFT studies in demonstrating extra-bowel manifestations such as phlegmons and abscesses [2]. The sensitivity and specificity of MRE for diagnosing inflammatory bowel disease, particularly CD, is 96% and 92% respectively (using histological correlation as the gold standard for diagnosis). In comparison, endoscopy was found to be less sensitive (57%) but more specific (100%) in diagnosing inflammatory bowel disease [14]. The concordance of MRE detection of stenosis, thickening and hyperemia of bowel wall, with endoscopy, was 90%, the only drawback being its inability to demonstrate superficial ulceration [15].

A few published studies have compared CT enterography and MR enterography imaging in the assessment of patients with CD. Ippolito et al. [16] found similar accuracy for CTE and MRE in the identification of active disease. Whereas Low and co-workers [17] reported that depiction of mural thickening and enhancement was superior on MRE, which showed 80–85% of abnormal segments compared with only 60–65% found by CT, Schmidt et al. [18] found that CT had better sensitivity in detecting bowel wall thickening, bowel wall enhancement and lymphadenopathy with higher interobserver agreement. MRE was found to be more accurate than CT enterography in the detection of enteric fistulas and sinus tracts [16,18].

Several prospective studies comparing MR and wireless capsule endoscopy imaging of small bowel were recently published. Both MRE and WCE showed a good correlation in the detection and localization of inflammatory bowel disease. WCE sensitivity for detecting small mucosal lesions is better than that of MRE, while WCE can readily depict and characterize subtle mucosal lesions missed by MRE. Since MRE yields additional mural and extraluminal information, WCE and MRE can be complementary methods that, in conjunction, may better characterize suspected small bowel disease [19,20].

In small bowel neoplasm MRE demonstrates either a filling defect [Figure 2A] or focal wall thickening [Figure 2B]. Most of the small bowel tumors are benign, but symptomatic lesions are often malignant. Adenocarcinomas, which

Figure 2. Space-occupying lesion in small bowel. **[A]** MRE axial T2 image of a 17 year old girl with rectal bleeding and familial polyposis showing polypoid lesion (arrow). **[B]** MRE coronal T2 images of a 74 year old woman with celiac disease suspected of having small bowel malignancy. Localized thickening of jejunal wall is apparent (dotted arrow) and suspected of being malignant.

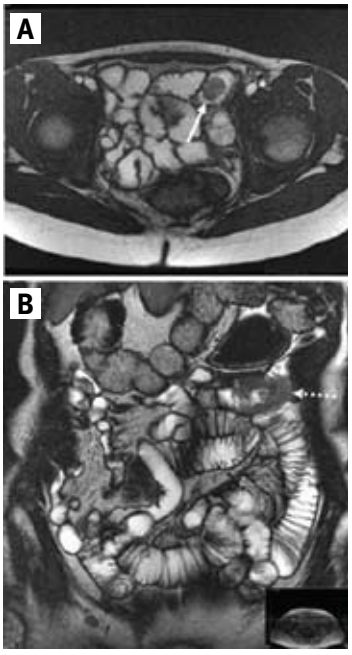

SBFT = small bowel follow-through

account for 50% of all small bowel malignancies, typically appear as a focal mass with intra- and extraluminal growth or with circumferential constricting lesions that narrow the bowel lumen [21] [Figure 2B]. Moreover, MRE can evaluate regional mesenteric lymphadenopathy, as shown in three of our patients.

There is a paucity of data comparing the sensitivity of MRE imaging, CTE and fluoroscopic techniques in the detection of small bowel masses. The sensitivity and specificity of MRE in identifying patients with small bowel lesions were 86% and 98%, respectively [22]. MRE imaging can be useful in the surveillance of patients who have polyposis syndromes and a higher risk of developing small bowel malignancies. When comparing MRE and WCE, polyps larger than 15 mm were detected similarly in patients who had polyposis syndromes. Smaller polyps were seen much more often with WCE. However, location of the detected polyps and determination of their exact size was more accurate with MRE [23].

Although only one of our patients was referred for celiac disease evaluation, MRE clearly showed fold-pattern abnormalities characteristic of this disease. A reversed jejuno-ileal fold pattern, which presumably is caused by a compensatory response of the ileum to severe villous atrophy of the proximal small bowel, is highly suggestive of celiac disease and is very well depicted on MRE. MRE can demonstrate extraluminal manifestations such as intussusception and mesenteric lymphadenopathy, as well as non-Hodgkin's lymphoma, which occur in higher incidence in celiac patients [5,24].

Regarding incidental findings, MRE has the advantage of visualizing disease extension beyond the intestinal wall. Some of these findings are unexpected and not related to the patient's disease. In our series incidental extraintestinal findings were present in 17% of all scans performed, most of which were not clinically significant. Similar results were reported by Jensen et al. [25].

CONCLUSIONS

In our 4-year clinical experience with MRE this non-invasive modality has proven to be a reliable and promising technique for the evaluation and long-term follow-up of small bowel pathologies. In this study we have shown that MRE has the capabilities to demonstrate luminal, mural and extraluminal pathology in diseases of the small bowel without the use of ionizing radiation. The most common clinical indication was the evaluation of Cohn's disease. MRE should become the imaging modality of choice in these patients, gradually replacing modalities involving high radiation exposure such as SBFT or CT. In Crohn's patients MRE was proven to be highly sensitive for the evaluation of inflammatory changes in the bowel as well as extraluminal complications. It is also useful for the detection of small bowel neoplasm and small bowel obstruction. MRE might efficiently assess the cause for SBO as well as define neoplasm characteristics. It can also be useful for the evaluation of celiac disease, a disease that is probably clinically under-diagnosed in Israel. With physicians' increased awareness, the future use of MRE in the evaluation of other small bowel pathologies such as neoplasm and celiac disease will increase.

Corresponding author:
Dr. M. Amitai
Dept. of Diagnostic Imaging, Sheba Medical Center, Tel Hashomer 52621, Israel
Phone: (972-3) 530-2530
Fax: (972-3) 535-7315; 972-3-530-5808
email: michal.amitai@sheba.health.gov.il

References

1. Brenner DJ, Hall EJ. Computed tomography – an increasing source of radiation exposure. *N Engl J Med* 2007; 357 (22): 2277-84.
2. Fidler J. MR imaging of the small bowel. *Radiol Clin North Am* 2007; 45 (2): 317-31.
3. Cronin CG, Lohan DG, Browne AM, Roche C, O'Keeffe D, Murphy JM. MR small-bowel follow-through for investigation of suspected pediatric small-bowel pathology. *AJR Am J Roentgenol* 2009; 192 (5): 1239-45.
4. McKenna DA, Roche CJ, Murphy JM, McCarthy PA. Polyethylene glycol solution as an oral contrast agent for MRI of the small bowel in a patient population. *Clin Radiol* 2006; 61 (11): 966-70.
5. Lohan DG, Alhajeri AN, Cronin CG, Roche CJ, Murphy JM. MR enterography of small-bowel lymphoma: potential for suggestion of histologic subtype and the presence of underlying celiac disease. *AJR Am J Roentgenol* 2008; 190 (2): 287-93.
6. Israeli E, Hershcovici T, Grotto I, Rouach Z, Branski D, Goldin E. Prevalence of celiac disease in an adult Jewish population in Israel. *IMAJ Isr Med Assoc J* 2010; 12 (5): 266-9.
7. Beall DP, Fortman BJ, Lawler BC, Regan F. Imaging bowel obstruction: a comparison between fast magnetic resonance imaging and helical computed tomography. *Clin Radiol* 2002; 57 (8): 719-24.
8. Low RN, Chen SC, Barone R. Distinguishing benign from malignant bowel obstruction in patients with malignancy: findings at MR imaging. *Radiology* 2003; 228 (1): 157-65.
9. Gourtsoyiannis N, Papanikolaou N, Grammatikakis J, Papamastorakis G, Prassopoulos P, Roussomoustakaki M. Assessment of Crohn's disease activity in the small bowel with MR and conventional enteroclysis: preliminary results. *Eur Radiol* 2004; 14 (6): 1017-24.
10. Koh DM, Miao Y, Chinn RJ, et al. MR imaging evaluation of the activity of Crohn's disease. *AJR Am J Roentgenol* 2001; 177 (6): 1325-32.
11. Maccioni F, Viscido A, Broglia L, et al. Evaluation of Crohn disease activity with magnetic resonance imaging. *Abdom Imaging* 2000; 25 (3): 219-28.
12. Umschaden HW, Szolar D, Gasser J, Umschaden M, Haselbach H. Small-bowel disease: comparison of MR enteroclysis images with conventional enteroclysis and surgical findings. *Radiology* 2000; 215 (3): 717-25.
13. Rieber A, Wruk D, Potthast S, et al. Diagnostic imaging in Crohn's disease: comparison of magnetic resonance imaging and conventional imaging methods. *Int J Colorectal Dis* 2000; 15 (3): 176-81.
14. Darbari A, Sena L, Argani P, Oliva-Hemker JM, Thompson R, Cuffari C. Gadolinium-enhanced magnetic resonance imaging: a useful radiological tool in diagnosing pediatric IBD. *Inflamm Bowel Dis* 2004; 10 (2): 67-72.
15. Magnano G, Granata C, Barabino A, et al. Polyethylene glycol and contrast-enhanced MRI of Crohn's disease in children: preliminary experience. *Pediatr Radiol* 2003; 33 (6): 385-91.
16. Ippolito D, Invernizzi F, Galimberti S, Panelli MR, Sironi S. MR enterography with polyethylene glycol as oral contrast medium in the follow-up

of patients with Crohn disease: comparison with CT enterography. *Abdom Imaging* 2010; 35 (5): 563-70.

17. Low RN, Francis IR, Politoske D, Bennett M. Crohn's disease evaluation: comparison of contrast-enhanced MR imaging and single-phase helical CT scanning. *J Magn Reson Imaging* 2000; 11 (2): 127-35.
18. Schmidt S, Lepori D, Meuwly JY, et al. Prospective comparison of MR enteroclysis with multidetector spiral-CT enteroclysis: interobserver agreement and sensitivity by means of "sign-by-sign" correlation. *Eur Radiol* 2003; 13 (6): 1303-11.
19. Crook DW, Knuesel PR, Froehlich JM, et al. Comparison of magnetic resonance enterography and video capsule endoscopy in evaluating small bowel disease. *Eur J Gastroenterol Hepatol* 2009; 21 (1): 54-65.
20. Tillack C, Seiderer J, Brand S, et al. Correlation of magnetic resonance enteroclysis (MRE) and wireless capsule endoscopy (CE) in the diagnosis of small bowel lesions in Crohn's disease. *Inflamm Bowel Dis* 2008; 14 (9): 1219-28.
21. Semelka RC, John G, Kelekis NL, Burdeny DA, Ascher SM. Small bowel neoplastic disease: demonstration by MRI. *J Magn Reson Imaging* 1996; 6 (6): 855-60.
22. Masselli G, Polettini E, Casciani E, Bertini L, Vecchioli A, Gualdi G. Small-bowel neoplasms: prospective evaluation of MR enteroclysis. *Radiology* 2009; 251 (3): 743-50.
23. Caspari R, von Falkenhausen M, Krautmacher C, Schild H, Heller J, Sauerbruch T. Comparison of capsule endoscopy and magnetic resonance imaging for the detection of polyps of the small intestine in patients with familial adenomatous polyposis or with Peutz-Jeghers' syndrome. *Endoscopy* 2004; 36 (12): 1054-9.
24. Masselli G, Picarelli A, Gualdi G. Celiac disease: MR enterography and contrast enhanced MRI. *Abdom Imaging* 2010; 35 (4): 399-406.
25. Jensen MD, Nathan T, Kjeldsen J, Rafaelsen SR. Incidental findings at MRI-enterography in patients with suspected or known Crohn's disease. *World J Gastroenterol* 2010; 16 (1): 76-82.