Chilblains in a Patient with Systemic Lupus Erythematosus: Another Manifestation of the Great Masquerader

Uri Manor MD[2,4], Nir Dankovich MD[2], Daniel Boleslavsky MD[2], Shaye Kivity MD[1,3,4] and Shmuel Stienlauf MD[2,4]

Departments of Internal Medicine [1]A and [2]C, and [3]Rheumatic Disease Unit, Sheba Medical Center, Tel Hashomer, Israel
[4]Sackler Faculty of Medicine, Tel Aviv University, Tel Aviv, Israel

KEY WORDS: chilblain lupus erythematosus (CHLE), cutaneous lupus erythematosus (CLE), discoid lupus erythematosus (DLE), rash, systemic lupus erythematosus (SLE)

IMAJ 2019; 21: 761–762

PATIENT DESCRIPTION

A 20-year-old male was admitted to our department due to several weeks of intermittent fevers, night sweats, anorexia, weight loss, and exacerbation of a chronic rash. Previous medical history consisted of chronic immune thrombocytopenic purpura (ITP) when he was 9 years old, for which he receives 5 mg of prednisone on a day-on/day-off basis. Family history includes a sister with type I diabetes mellitus, a sister with Raynaud's syndrome, and cousins with systemic lupus erythematosus (SLE).

Physical examination was significant for a papular, violaceous, non-tender rash on the palmar and plantar aspects of his fingers and toes [Figure 1B]. The patient described a similar rash at the age of 13 years, which resolved without specific treatment. In the submental area, a circular plaque with central alopecia and hyperkeratosis was found. It had existed for several years and was worsening lately [Figure 1A].

Laboratory tests were significant for mild pancytopenia and elevation of liver function tests. Complement levels showed mildly decreased C3 and normal C4. Blood cultures were sterile, and assays for cryoglobulinemia were negative. Autoimmunity profiles revealed elevated titers of homogenous antinuclear antibodies ([ANA] 1:2,560), anti-histone, anti-Ro, and anti-ribonucleoprotein (anti-RNP) antibodies. Antibodies associated with the anti-phospholipid syndrome (APS) had borderline elevations. Antibodies against double-strand DNA (dsDNA) were notably absent. Lesion biopsies were waived due to the patient's reluctance and to our concern of eliciting the Köebner phenomenon, which is a nonspecific stimulus eliciting a disease skin reaction that is linked to cutaneous lupus erythematosus (CLE), among other diseases [1]. A transthoracic echocardiography (TTE) was negative for potentially emboligenic valvular lesions and whole body computed tomography (CT) was insignificant.

The patient was diagnosed with SLE due to hematologic, immunologic, and cutaneous criteria. Substantial symptomatic and clinical improvement was achieved by treatment with systemic corticosteroids and anti-malarials (200 mg hydroxychloroquine twice daily). His disease has remained in remission for the past year following slow tapering of corticosteroids to a current dose of 4 mg prednisone daily.

COMMENT

This case reports on the co-existence of two types of chronic CLE (CCLE) rashes in a young male with newly diagnosed SLE. Localized discoid lupus erythematosus (DLE), as demonstrated in Figure 1B, is the classic and most common clinical manifestation of CLE [2]. Chilblains (also,

Figure 1. Cutaneous manifestations of a patient diagnosed with lupus erythematosus
[A] Discoid lupus erythematosus inferior to the chin
[B] Chilblain lupus erythematosus on the feet

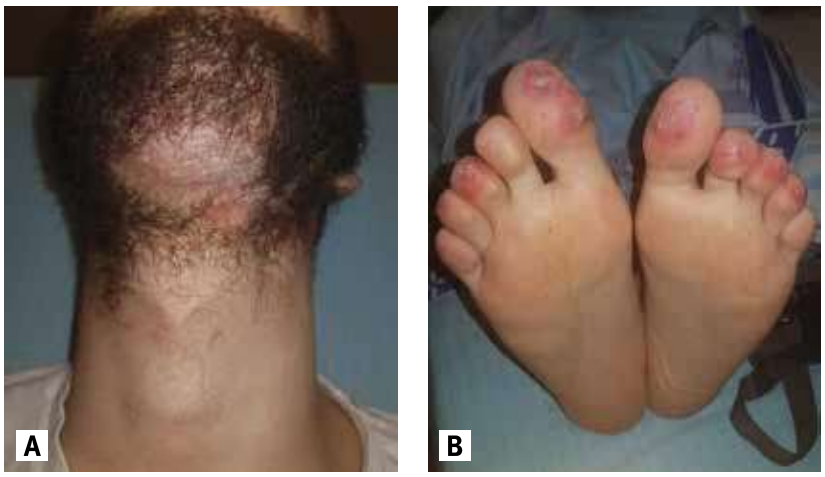

perniosis) are cutaneous inflammatory lesions that usually occur in response to repeated exposure to cold. Chilblain lupus erythematosus (CHLE), shown in Figure 1B, is a rare type of CLE. Lesions are usually papuloerythematous and pruritic, but may also have plaque-like, hyperkeratotic, and ulcerative components. They are mostly located on acral surfaces, and may be accompanied by other lupus-related rashes, such as DLE or Raynaud's phenomenon. The pathogenesis of CHLE probably consists of a cold-induced microvascular injury, coupled with the immunological anomalies of SLE patients. A relationship to the presence of anti-Ro antibodies has also been described. An autosomal dominant familial variant, in contrast to the sporadic form, has been linked to mutations of the *TREX1* gene [3]. Diagnostic criteria have been suggested, consisting of two major criteria (characteristic skin lesions and positive biopsy) and three minor criteria (coexistence of SLE or DLE, response to anti-LE therapy, negative cryoglobulin, and cold agglutinin studies). Treatment includes physical protection from cold, topical or systemic corticosteroids, and more advanced immunosuppressants if the other treatments are insufficient [3].

When compared to published case series of CHLE, this patient is unique for being young and male. Nevertheless, CHLE following a chronic course, especially when associated with autoimmune abnormalities, may imply concurrent rheumatologic disease [4]. Commonly dubbed as a "great masquerader," SLE is a severe disease with variable manifestations. In this case, lupus-specific cutaneous lesions heralded "full-blown" SLE by years. Studies have consistently shown that rapid diagnosis and treatment is essential for increased survival and quality of life [5].

CONCLUSIONS

Clinician familiarity with the spectrum of cutaneous lupus erythematosus lesion may help to raise the index of suspicion to this disease and shorten the time to diagnosis.

Correspondence
Dr. S. Stienlauf
Dept. of Internal Medicine C, Sheba Medical Center, Tel Hashomer 5265601, Israel
Phone: (972-3) 530-2464
Fax: (972-3) 530-2472
email: shmuel.stienlauf@sheba.health.gov.il

References:

1. Ueki H. Koebner phenomenon in lupus erythematosus with special consideration of clinical findings. *Autoimmun Rev* 2005; 4 (4): 219-23.
2. Ribero S, Sciascia S, Borradori L, Lipsker D. The cutaneous spectrum of lupus erythematosus. *Clin Rev Allergy Immunol* 2017; 53 (3): 291-305.
3. Hedrich CM, Fiebig B, Hauck FH, et al. Chilblain lupus erythematosus - a review of literature. *Clin Rheumatol* 2008; 27 (8): 949-54.
4. Viguier M, Pinquier L, Cavelier-Balloy B, et al. Clinical and histopathologic features and immunologic variables in patients with severe chilblains: a study of the relationship to lupus erythematosus. *Medicine (Baltimore)* 2001; 80 (3): 180-8.
5. Sebastiani GD, Prevete I, Iuliano A, Minisola G. The importance of an early diagnosis in systemic lupus erythematosus. *IMAJ* 2016; 18 (3-4): 212-15.

Capsule

Autoimmunity shows its CARDs

Both the adaptor protein CARD9 and loss of the kinase Lyn are associated with autoimmune disease, notably colitis and inflammatory bowel disease. **Ma** et al. found in mice that CARD9 amplified Toll-like receptor signaling and cytokine production in Lyn-deficient dendritic cells but not macrophages. Deleting the *Card*9 gene or genes encoding Src-family kinases in dendritic cells prevented the development of Lyn deficiency–associated colitis in mice. Targeting CARD9 or its associated kinases may be a way to relieve inflammation in patients with autoimmune disease.

Sci Signal 2019; 12: eaao3829

Eitan Israeli

Capsule

The landscape of somatic mutation in normal colorectal epithelial cells

The colorectal adenoma–carcinoma sequence has provided a paradigmatic framework for understanding the successive somatic genetic changes and consequent clonal expansions that lead to cancer. However, our understanding of the earliest phases of colorectal neoplastic changes, which may occur in morphologically normal tissue, is comparatively limited, as for most cancer types. **Lee-Six** et al. used whole-genome sequencing to analyze hundreds of normal crypts from 42 individuals. Signatures of multiple mutational processes were revealed; some of these were ubiquitous and continuous, whereas others were only found in some individuals, in some crypts or during certain periods of life. Probable driver mutations were present in around 1% of normal colorectal crypts in middle-aged individuals, indicating that adenomas and carcinomas are rare outcomes of a pervasive process of neoplastic change across morphologically normal colorectal epithelium. Colorectal cancers exhibit substantially increased mutational burdens relative to normal cells. Sequencing normal colorectal cells provides quantitative insights into the genomic and clonal evolution of cancer.

Nature 2019; 574: 532

Eitan Israeli