

Phototoxic Response to *Ficus carica* Leaf and Shoot Saps

Amer Hussein MD¹ and Inna Shugaev MD²

¹Department of Emergency Medicine, Ziv Medical Center and Bar Ilan Faculty of Medicine, Safed, Israel

²Department of Internal Medicine B, Bnai-Zion Medical Center, Haifa, Israel

KEY WORDS: fig, *Ficus carica*, photocontact dermatitis, erythema, phytophotodermatitis, furocoumarins
IMAJ 2012; 14: 399-400

Photocontact dermatitis due to figs, though well known by dermatologists, is poorly recognized by the general physician. The approach to a patient presenting to the Emergency Department with a skin reaction is based on the pathogenesis of his or her reaction. In the case described here, the contact with shoot and leaf sap, rich in photoactive psoralens, was the cause of the severe phototoxic response.

PATIENT DESCRIPTION

A 55 year old white male presented to the Emergency Department with a 3 day history of generalized erythematous and edematous rash with vesicles and bullae especially on the trunk and extremities. These symptoms emerged several hours after the patient had pruned the branches of a fig tree while working in his garden without a shirt. He denied eating any figs or coming into contact with any other fruit or plant. His past medical history was not clinically significant.

On physical examination the patient was alert. Vital signs were normal. Examination of head, eyes, ears, nose and throat were normal with no swelling of the lips, palate, uvula, face or neck. Examination of the chest, abdomen, back and extremities showed patches of erythema, with clear vesicles

and bullae [Figure]. Cardiac, pulmonary and neurological examinations were normal. The results of chest X-ray examination and laboratory investigations were normal.

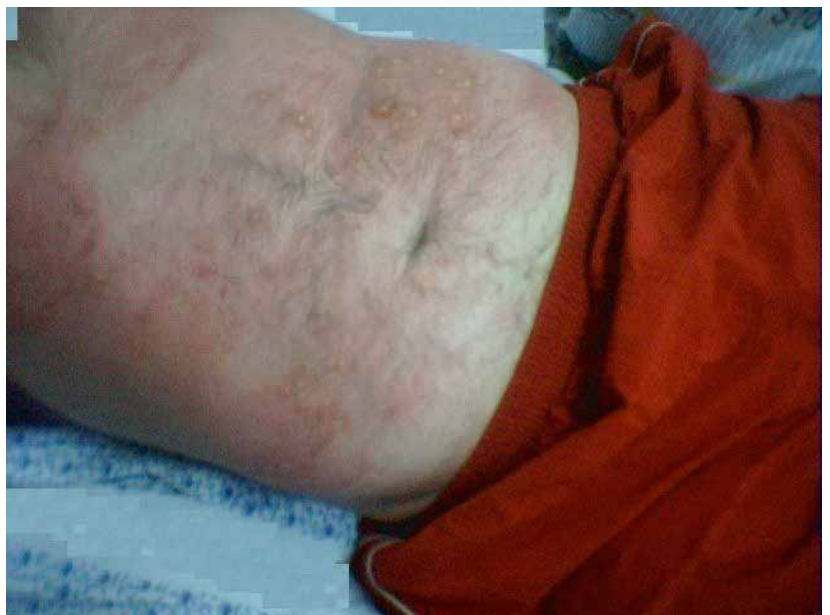The differential diagnosis of the patient's illness was allergic contact dermatitis (phytophoto) or chemical burn. He was therefore treated with intravenous promethazine 50 mg to alleviate pruritus, and intravenous hydrocortisone 300 mg, administered over 30 minutes, to suppress progression and later recurrence of symptoms.

The patient was admitted to the Internal Medicine ward for continued treatment and follow-up. The drug regimen included oral antihistamine and prednisone 40 mg per day. The patient's general condition improved:

the erythema, vesicles and bullae regressed and the pruritus subsided. He was discharged on prednisone tablets in a tapering dosage, with recommendations to avoid scratching and secondarily infecting the skin lesion and also to avoid exposure of the afflicted body parts to sunlight.

COMMENT

A literature survey revealed a wide spectrum of reactions. These include a relatively self-limited reaction of oral allergy syndrome [1], and photocontact dermatitis as an acute skin reaction that may be easily confused with other causes of contact dermatitis and is termed phytophotodermatitis. It is characterized by sunburn, blis-



Patches of erythema, with clear vesicles and bullae on the abdomen

ters, and/or hyperpigmentation. The reaction occurs when certain plant substances, after being activated by ultraviolet light from the sun, come in contact with the skin [2].

Airborne contact dermatitis is an allergic contact dermatitis. The disease usually manifests as itchy erythematous, papular, papulovesicular and plaque lesions on exposed areas of the body. The rash does not spare photo-protected areas in shaded areas. The severe reaction referred to is a systemic life-threatening response of anaphylaxis after inhalation or ingestion [3].

Photosensitizers are chemicals that have the ability to absorb radiation in the ultraviolet and visible ranges of light. Photo-irritant contact dermatitis is a toxic response to photosensitizers. Furocoumarins are photosensitizing chemicals present in plants, therapeutic agents and perfumes [4]. The toxic reaction to furocoumarins that are present in plants and in plant products is termed phytophotodermatitis. Furocoumarins are chemical components common to the plant family's compositae (e.g., milfoil, yarrow), umbelliferae (e.g., parsley, celery, parsnip, carrot), leguminosae (scurf pea), rutaceae (e.g., lime, bitter orange), and moraceae [Figure]. The moraceae comprise 53 genera with about 1400 species, approximately 800 of which are of the genus *Ficus*. Furocoumarins

have been detected in all parts of *Ficus carica*, including the milky sap. The leaf and shoot saps contain two photoactive furocoumarine compounds: psoralen and bergapten. The main phototoxic compound is psoralen, whose concentration is greater and its photoactivity is at least four times greater than that of bergapten. Heat and humidity may increase the toxicity.

The approach to a patient presenting to the Emergency Department with a skin reaction is based on the pathogenesis of this reaction. Firstly the physician needs to determine whether the reaction was to a systemic agent (by ingestion or injection) or through skin contact. This distinction can be made primarily by anamnesis. Secondly, the physician needs to differentiate between a toxic and an allergic mechanism. This can be done by considering several characteristics of the response: whether it occurred on the very first exposure (toxic) or if there was a delay between ultraviolet exposure and this reaction (there is almost no delay when the reaction is toxic), and the clinical morphology (eczematous for an allergic response versus edema, bullae and vesicles in the case of a toxic response). Photo patch testing [5] is non-discriminating (photocontact dermatitis). In our case, the history and clinical appearance of areas that were exposed to

the sun were both characteristic of phototoxic dermatitis.

Treatment is primarily symptomatic; severe cases are hospitalized and treated with wet compresses and paraffin gauze dressings and analgesia as needed. Corticosteroids can be given if the eruption is edematous. Sun protection and avoidance of ultraviolet radiation exposure for several months is advisable, as affected areas may continue to be photosensitive (phytophotodermatitis).

Corresponding author:

Dr. A. Hussein

Head, Dept. of Emergency Medicine, Ziv Medical Center, Safed 13100, Israel

Fax: (972-4) 692-8746

email: amer.h@ziv.health.gov.il

References

1. Antico A, Zoccatelli G, Marcotulli C, Curioni A. Oral allergy syndrome to fig. *Int Arch Allergy Immunol* 2003; 131: 138-42.
2. Bonamonte D, Foti C, Lionetti N, Rigano L, Angelini G. Photoallergic contact dermatitis to 8-methoxypsoralen in *Ficus carica*. *Contact Dermatitis* 2010; 62 (6): 343-8.
3. Dechamp C, Bessot JC, Pauli G, Deviller P. First report of anaphylactic reaction after fig (*Ficus carica*) ingestion. *Allergy* 1995; 50: 514-16.
4. Pathak MA, Daniels F, Fitzpatrick TB. The presently known distribution of furocoumarins (psoralens) in plants. *J Invest Dermatol* 1962; 39: 225-39.
5. Deleo VA. Photocontact dermatitis. *Dermatol Ther* 2004; 17 (4): 279-88.

Capsule

The leukocyte integrin antagonist Del-1 inhibits IL-17-mediated inflammatory bone loss

Aging is linked to greater susceptibility to chronic inflammatory diseases, several of which, including periodontitis, involve neutrophil-mediated tissue injury. Eskin and fellow researchers found that aging-associated periodontitis was accompanied by lower expression of Del-1, an endogenous inhibitor of neutrophil adhesion dependent on the integrin LFA-1, and by reciprocal higher expression of interleukin 17 (IL-17). Consistent with that, IL-17 inhibited gingival endothelial cell expression of Del-1, thereby promoting LFA-1-dependent recruitment of neutrophils. Young Del-1-deficient mice developed

spontaneous periodontitis that featured excessive neutrophil infiltration and IL-17 expression; disease was prevented in mice doubly deficient in Del-1 and LFA-1 or in Del-1 and the IL-17 receptor. Locally administered Del-1 inhibited IL-17 production, neutrophil accumulation and bone loss. Therefore, Del-1 suppressed LFA-1-dependent recruitment of neutrophils and IL-17-triggered inflammatory pathology and may thus be a promising therapeutic agent for inflammatory diseases.

Nature Immunol 2012; 13: 465

Eitan Israeli

Erdheim-Chester Disease in a 49 Year Old Man

Ilan Asher MD¹, Irena Rabinovith MD², Miriam Katz MD³ and Zev Sthoeger MD^{1,2}

¹Dept. of Allergy, Clinical Immunology and Neve-Or AIDS center, ²Internal Medicine B, and ³Imaging, Kaplan Medical Center, Rehovot, affiliated with Hebrew University-Hadassah Medical School, Jerusalem, Israel

KEY WORDS: Erdheim-Chester disease, perirenal fibrosis, osteosclerosis, hydronephrosis, periaortic infiltration

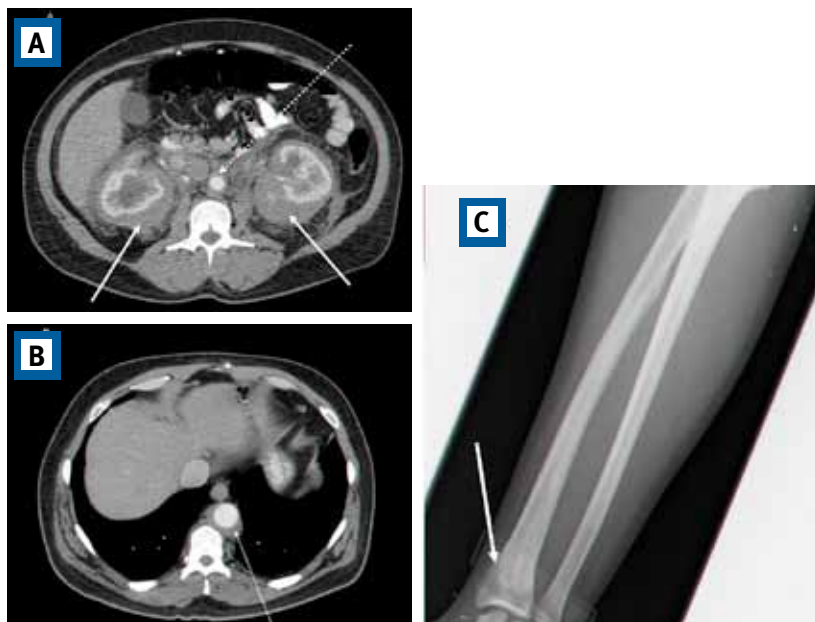
IMAJ 2012; 14: 401

For Editorial see page 388

A 49 year old male with non-specific abdominal pain underwent computed tomography scan, which demonstrated bilateral perirenal soft tissue infiltrates with mild hydronephrosis [Figure A] and periaortic infiltrates [Figure A & B, dotted arrows]. Skeletal studies showed symmetric osteosclerotic lesions in the distal radius [Figure C, arrow]. Blood tests revealed anemia (11.4 g/dl), thrombocytosis (427,000/mm³), elevated erythrocyte sedimentation rate (84/hr) and C-reactive protein (40, normal < 0.8). Liver, renal, electrolytes and serological tests were all normal. Biopsy of the perirenal mass demonstrated foamy histiocytic aggregates (CD68 positive, S-100 negative) indicating macrophage but not dendritic/Langerhans cell lineage histiocytosis, establishing the diagnosis of Erdheim-Chester disease [1,2].

Erdheim-Chester disease is a rare non-Langerhans cell histiocytosis of unknown etiology, with bone, perirenal (“hairy kidneys”) and periaortic (“coated aorta”) infiltrates. Cardiac, orbital, pituitary (presenting as diabetes insipidus), pulmonary and skin infiltrations were also reported [3].

Clinical manifestations and prognosis depend on the organs involved. Patients with systemic involvement without treatment have a poor prognosis with a mean survival of 2–3 years after diagnosis [4]. Corticosteroids, vincris-



Abdominal CT scan demonstrating bilateral perirenal soft tissue infiltrates with mild hydronephrosis [A, arrow] and periaortic infiltrates [A & B, dotted arrows]. Skeletal studies demonstrating symmetric osteosclerotic lesions in distal radius [C, arrow]

tine, interferon-alpha, imatinib mesylate (Glivec[®], Novartis, Switzerland) and bisphosphonates were reported to be beneficial in the treatment of patients with Erdheim-Chester disease [5]. Our patient was treated with interferon-alpha and bisphosphonates, which led to the normalization of his abnormal blood tests (hemoglobin, thrombocytes, erythrocyte sedimentation rate, C-reactive protein) and to the partial resolution of his bone, perirenal and periaortic lesions.

Corresponding author:
Dr. Z. Sthoeger

Head, Depts. of Internal Medicine B and Allergy, Clinical Immunology and Neve-Or AIDS Center, Kaplan Medical Center, Rehovot 76100, Israel

Phone: (972-8) 944-1403 **Fax:** (972-8) 944-1826
email: Zev_s@clalit.org.il

References

1. Veyssier-Belot C, Cacoub P, Caparros-Lefebvre D et al. Erdheim-Chester disease. Clinical and radiological characteristics of 59 cases. *Medicine (Baltimore)* 1996; 75 (3): 157-69.
2. Dion E, Graef C, Miquel A, et al. Bone involvement in Erdheim-Chester disease: imaging findings including periostitis and partial epiphyseal involvement. *Radiology* 2006; 238 (2): 632-9.
3. Haroche J, Amaud L, Amoura Z. Erdheim-Chester disease. *Curr Opin Rheumatol* 2012; 24 (1): 53-9.
4. Arnaud L, Hervieu B, Neel A, et al. CNS involvement and treatment with interferon-α are independent prognostic factors in Erdheim-Chester disease: a multicenter survival analysis of 53 patients. *Blood* 2011; 117: 2778-82.
5. Wilejto M, Abl O. Langerhans cell histiocytosis and Erdheim-Chester disease. *Curr Opin Rheumatol* 2012; 24 (1): 90-6.