

“Trap” the Diagnosis: A Man with Recurrent Episodes of Febrile Peritonitis, Not Just Familial Mediterranean Fever

Uri Arad MD PhD¹, Eva Niv MD², Dan Caspi MD¹ and Ori Elkayam MD¹

Departments of ¹Rheumatology and ²Gastroenterology, Tel Aviv Sourasky Medical Center, Tel Aviv, affiliated with Sackler Faculty of Medicine, Tel Aviv University, Ramat Aviv, Israel

ABSTRACT: Monogenic periodic fever syndromes are characterized by recurrent episodes of fever, accompanied by localized inflammatory manifestations. Among them, familial Mediterranean fever (FMF) is the most studied and is by far the most prevalent periodic fever syndrome in Israel. We present a diagnostic workup of a patient suffering from a periodic fever syndrome, initially thought to be FMF and characterized by attacks of fever, severe abdominal pain, a migratory erythematous rash and conjunctivitis. The development of periorbital edema presenting as diplopia led to consideration of tumor necrosis factor receptor-1-associated periodic syndrome (TRAPS). Genetic tests confirmed the diagnosis. This case should alert us that even in Israel, a patient with periodic fever not fully consistent with the typical features of FMF, should be evaluated for other periodic fever syndromes.

IMAJ 2012; 14: 229–231

KEY WORDS: periodic fever syndrome, tumor necrosis factor receptor-1, tumor necrosis factor receptor-1-associated periodic syndrome (TRAPS), familial Mediterranean fever (FMF)

Monogenic periodic fever syndromes, a subset of auto-inflammatory diseases, are characterized by recurrent episodes of fever, accompanied by localized inflammatory manifestations. Among them, familial Mediterranean fever is the most studied and is prevalent among populations originating in the Mediterranean basin. The other hereditary recurrent fevers include the recessively inherited hyperimmunoglobulinemia D with periodic fever syndrome and four dominantly inherited illnesses – namely, tumor necrosis factor receptor-1-associated periodic syndrome, and three cryopyrinopathies: familial cold autoinflammatory syndrome, Muckle-Wells syndrome, and neonatal onset multisystem inflammatory disease, also known as chronic infantile neurologic cutaneous and articular syndrome.

Because FMF is by far the most prevalent and known periodic fever, particularly in endemic areas for FMF, such as Israel, the other periodic fever syndromes are usually ignored when

assessing patients with episodic febrile disease. We present a diagnostic workup of a patient with TRAPS, with emphasis on the clinical features that distinguish TRAPS from FMF.

PATIENT DESCRIPTION

A 28 year old male was referred to the Department of Rheumatology for evaluation of recurrent abdominal pain and fever that had troubled him since early childhood. The patient, of Jewish origin, was born in Bukhara and immigrated with his family to Israel at the age of 10. There was no family history of fever, abdominal pain or arthritis. At the age of 10 years, an appendectomy was performed, but the appendix was not inflamed. At age 11, a positive tuberculin skin test and a suspicious finding on chest X-ray led to treatment with isoniazid, rifampin and ethambutol for suspected tuberculosis, but without any change in the course of the disease. During adolescence, he continued to suffer from attacks of abdominal pain and high fever with elevated acute-phase reactants, without diarrhea or signs of malabsorption. The attacks lasted for about 10 days and resolved spontaneously. Repeated abdominal computed tomography and endoscopic evaluation were normal. A trial of treatment with colchicine was discontinued in view of negative genetic testing for FMF.

At the age of 24 he was hospitalized for peritonitis. An abdominal CT revealed small bowel loops with wall thickening and a small amount of peritoneal fluid. A laparotomy was performed, disclosing purulent peritoneal fluid, a grossly inflamed intestine, multiple adhesions and a short inflamed mesothelium. An omental biopsy showed fatty tissue with signs of chronic and acute inflammation. Gram-positive bacteria, both rods and cocci, were observed and the possibility of intestinal microperforation due to Crohn's disease was suggested.

During the next few years, the patient continued to experience recurrent attacks of fever and abdominal pain, sometimes presenting as partial bowel obstruction necessitating hospitalization, and occasionally accompanied by a rash on the arms or torso. Laboratory investigations revealed a normal complete blood count, except for intermittent normocytic anemia, normal levels of liver enzymes, albumin, amylase and normal renal

FMF = familial Mediterranean fever

TRAPS = tumor necrosis factor receptor-1-associated periodic syndrome

function. Acute-phase reactants, including C-reactive protein and erythrocyte sedimentation rate, were markedly elevated, also between attacks. Levels of vitamin B12, folic acid, vitamin D, thyroid-stimulating hormone, C1 esterase inhibitor, C3, C4 and porphobilinogen were within normal range. Serological tests for antineutrophil cytoplasmic antibodies, anti-*Saccharomyces cerevisiae* antibodies, antinuclear antibodies and anti-tissue transglutaminase antibodies were negative.

An abdominal CT showed a thickened terminal ileum. Colonoscopy was grossly normal, except for an edematous mucosa at the ileocecal valve. Biopsies from the colon and ileocecal valve were normal, including Congo red staining for amyloid deposits. No small intestinal mucosal inflammation was observed by a video capsule endoscopy. The patient was then referred for evaluation of possible FMF. A repeated genetic test for the common *MEVF* gene mutations M694V, E148Q and V726A was negative. Treatment with 1.5 mg colchicine per day for 5 months was completely ineffective. The flares persisted, lasting from several days to 2 weeks, at a frequency of about once or twice a month, often resolved with intramuscular injection of diclofenac but sometimes requiring hospitalization. Additional symptoms during attacks included pleuritic chest pain, testicular pain, and a transient migratory erythematous rash [Figure A]. The patient also complained of conjunctival irritation diagnosed as allergic conjunctivitis by an ophthalmologist.

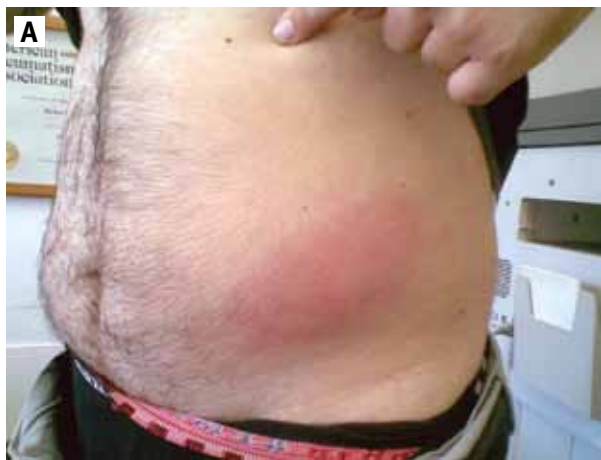At the age of 29, the patient developed acute diplopia. Right exophthalmos with limited bilateral eye abduction and an otherwise normal ophthalmological examination was noted. Blood tests showed elevated acute-phase reactants with normal levels

of thyroid-stimulating hormone. A contrast CT of the head revealed right retro-orbital fat infiltration without any pathological findings in the sinuses or brain [Figure B]. The patient was treated with prednisone 60 mg/day and colchicine 1.5 mg/day for 7 days with complete resolution of his symptoms. The constellation of a periodic fever syndrome accompanied by severe abdominal pain, resistance to colchicine therapy, lack of common *MEVF* mutations, the typical rash and especially the ocular symptoms, led to the clinical diagnosis of TRAPS. A genetic test was performed by sequencing exons 2, 3, 4 and 6 of the *TNFRSF1A* gene. A G→A mutation at nucleotide 374 was detected, resulting in substitution of cysteine by tyrosine in amino acid 96, in exon 4.

Treatment with 25 mg subcutaneous etanercept twice a week was begun, with rapid resolution of all clinical symptoms and normalization of acute-phase reactant levels, an increase in hemoglobin from 12.0 to 15.8 g/dl and a weight gain of 8 kg. This effect lasted for 6 months, but symptoms of abdominal pain with fever and the migratory rash recurred with increasing intensity, requiring continuous corticosteroid therapy. Etanercept was discontinued, and after a washout period of 3 months, treatment was initiated with 150 mg subcutaneous canakinumab, a monoclonal anti-interleukin-1 β antibody. This resulted in a resolution of the clinical symptoms until the present.

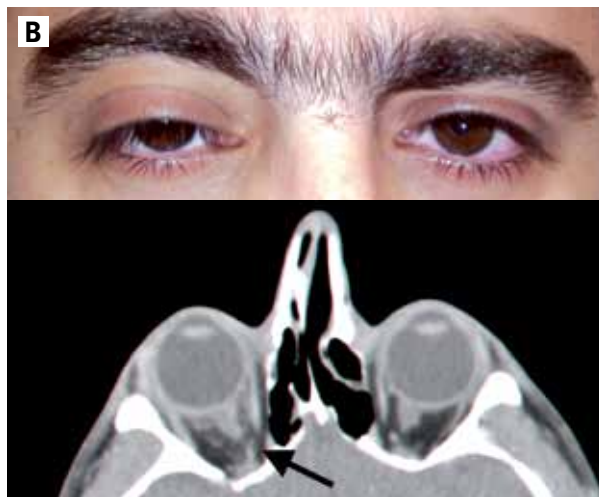
COMMENT

A patient suffering from a periodic fever syndrome, characterized by attacks of fever, severe abdominal pain, a migratory ery-



[A] An erythematous, warm, tender, localized rash, which appeared during some of the attacks. Note that the patient is pointing to the site where the rash originally appeared several days earlier.

[B] Periorbital edema in the right eye. Axial CT shows increased attenuation of the right retro-orbital fat (arrow), compatible



with edema and inflammation. The images demonstrate that the superficial cutaneous lesions in TRAPS are accompanied by deeper local soft tissue inflammation (image reprinted with permission from the American College of Rheumatology).

thematous rash and the ocular symptoms of conjunctivitis and orbital edema was diagnosed with TRAPS after three decades.

TRAPS is a dominantly inherited periodic fever syndrome, originally described in a large pedigree of Irish-Scottish ancestry, but since then a broad ethnic distribution has emerged, including patients of African-American, Puerto Rican, European, Arab, Mexican and Jewish background. The case of an Arab patient with TRAPS in Israel has been reported [1]. The syndrome is caused by mutations in the *TNFRSF1A* gene, encoding the 55 kDa receptor for tumor necrosis factor. At least 76 mutations have been described (fmf.igh.cnrs.fr/infevers/). Patients without a family history due to reduced penetrance and de novo mutations [1] have been reported. All known mutations occur at the extracellular portion of the p55 TNF receptor, presumably disrupting the loop structures formed by cysteine-rich domains. A mutation that results in cysteine substitution is a risk factor for systemic amyloidosis, which occurs in about 15% of TRAPS patients. Defective shedding of the activated TNF receptor was first hypothesized as the mechanism that causes a hyperinflammatory phenotype due to decreased receptor clearance and a lower level of soluble receptors that act as competitive antagonists. Recently, several studies have proposed another mechanism whereby misfolded mutant receptors accumulate in the endoplasmic reticulum and trigger a TNF-independent pro-inflammatory state (reviewed in [2]).

As in FME, attacks usually begin in childhood in 80% of patients, and include fever and severe abdominal pain, sometimes with peritoneal signs. Several clinical features may distinguish TRAPS from FME. The duration of attacks in TRAPS is usually longer than 7 days, although shorter attacks can occur. In contrast to FME, in TRAPS arthralgia is more common than arthritis. The typical rash of TRAPS is a migratory, localized, erythematous, tender patch with underlying myalgia that differs from the erysipelas-like erythema of FME. As in our patient, ocular involvement is a feature that distinguished TRAPS from FME. Periorbital edema and conjunctivitis occur in 80% of TRAPS patients. The imaging in our patient demonstrates that similar to the cutaneous lesions in TRAPS [3], periorbital edema is accompanied by deeper local soft tissue inflammation.

Colchicine is not effective in preventing and treating the attacks of TRAPS or the development of amyloidosis.

Corticosteroids and non-steroidal anti-inflammatory drugs can be used to treat attacks, but patients often require escalating doses. In a prospective, open-label, dose-escalation study of 15 TRAPS patients, etanercept was found to reduce the symptoms and serum inflammatory markers of TRAPS but did not completely normalize symptoms or acute-phase reactants. Long-term adherence to etanercept was poor [4]. A retrospective study of seven TRAPS patients demonstrated that IL-1 blockade with anakinra induced a complete resolution of symptoms, with normalization of acute-phase reactants in all patients within a month. This beneficial effect was maintained during a median follow-up of 23 months [5].

To the best of our knowledge, this is the first published report of successful treatment of TRAPS with canakinumab. Although FMF is by far the most prevalent periodic fever syndrome in Israel, physicians should be aware of the clinical spectrum of the rarer autoinflammatory syndromes. In patients with periodic fever who do not display the typical features of FME, especially when mutations are not found in the *MEVF* gene and the patient is resistant to colchicine treatment, an evaluation for other periodic fever syndromes is warranted.

Corresponding author:

Dr. U. Arad

Dept. of Rheumatology, Tel Aviv Sourasky Medical Center, 6 Weizmann St. Tel Aviv 64239, Israel

email: uria@tasmc.health.gov.il

References

1. Aganna E, Zeharia A, Hitman GA, et al. An Israeli Arab patient with a de novo TNFRSF1A mutation causing tumor necrosis factor receptor-associated periodic syndrome. *Arthritis Rheum* 2002; 46: 245-9.
2. Pettersson T, Kantonen J, Matikainen S, Repo H. Setting up TRAPS. *Ann Med* 2012; 44 (2): 109-18. Epub 2011
3. Hull KM, Wong K, Wood GM, Chu WS, Kastner DL. Monocytic fasciitis: a newly recognized clinical feature of tumor necrosis factor receptor dysfunction. *Arthritis Rheum* 2002; 46: 2189-94.
4. Bulua AC, Mogul DB, Aksentijevich I, et al. Efficacy of etanercept in the tumor necrosis factor receptor-associated periodic syndrome: a prospective, open-label, dose-escalation study. *Arthritis Rheum* 2012; 64: 908-13.
5. Obici L, Meini A, Cattalini M, et al. Favourable and sustained response to anakinra in tumour necrosis factor receptor-associated periodic syndrome (TRAPS) with or without AA amyloidosis. *Ann Rheum Dis* 2011; 70: 1511-12.

IL-1 = interleukin-1

“I realize that patriotism is not enough. I must have no hatred or bitterness towards anyone”

Edith Cavell (1865-1915), British nurse celebrated for saving the lives of soldiers from all sides without distinction and in helping 200 Allied soldiers escape from German-occupied Belgium during World War I, for which she was arrested. She was subsequently court-martialed, found guilty of treason and sentenced to death

“If only I may grow: firmer, simpler, quieter, warmer”

Dag Hammarskjöld (1905-1961), Swedish diplomat, economist, author and Nobel laureate. He was the second to hold the position of Secretary-General of the United Nations. American President John F. Kennedy called Hammarskjöld “the greatest statesman of our century”