Use of Computed Tomography Angiography Before Endovascular Intervention in Acute Gastrointestinal Hemorrhage

Jonathan Singer-Jordan MB ChB FRCPC (C) DABR and Elite Arnon-Sheleg MD

Department of Interventional Radiology, Western Galilee Hospital, Nahariya, Israel

KEY WORDS: computed tomography angiography, gastrointestinal bleeding, embolization

IMAJ 2010; 12: 62–63

A 57 year old man with a history of rectal bleeding in the past year was admitted to the Western Galilee Hospital with acute onset of massive rectal bleeding. Colonoscopy had previously revealed diverticulosis and hemorrhoids. On admission, clotting parameters were within the normal range, heart rate was 130, blood pressure 93/50, and there was a brief episode of loss of consciousness. Despite resuscitation with crystalloids and blood replacement, bleeding continued and hemoglobin fell, eventually reaching 6.2. A CT angiogram was performed before conventional angiography.

CT angiography [Figure 1] clearly demonstrated the source of the bleeding as a branch of the superior hemorrhoidal artery, obviating the need for angiography of the superior mesenteric artery, inferior mesenteric artery and both internal iliac arteries to find the bleeding vessel; in fact without the CT angiogram it is likely that the examination may have been negative since angiography of the IMA did not demonstrate active bleeding [Figure 2]. In light of the CT angiogram, super-selective angiography of the pelvic branches of the IMA was carried out immediately after the IMA injection [Figure 3] and embolization with microcoils and microfibrillar collagen arrested the hemorrhage [Figure 4].

CT angiography has emerged in recent years as a preferred primary imaging modality in acute gastrointestinal bleeding. It was shown (in a porcine model) to depict active intraluminal bleeding at even lower extravasation

IMA = inferior mesenteric artery

Figure 1. Oblique coronal MIP (maximum intensity projection) reconstruction from CT angiography: aorta (upper arrow), inferior division of inferior mesenteric artery (middle arrow), active hemorrhage in rectum (lower arrow)

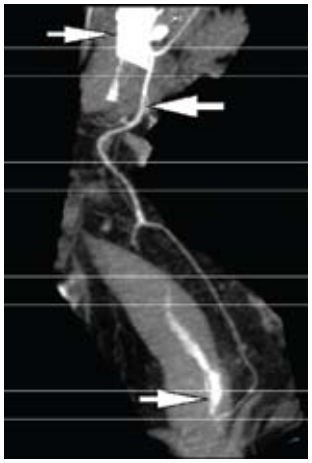

Figure 2. Inferior mesenteric arteriogram: superior hemorrhoidal artery (arrow)

Figure 3. Selective injection of branch of the superior hemorrhoidal artery: active hemorrhage (arrow)

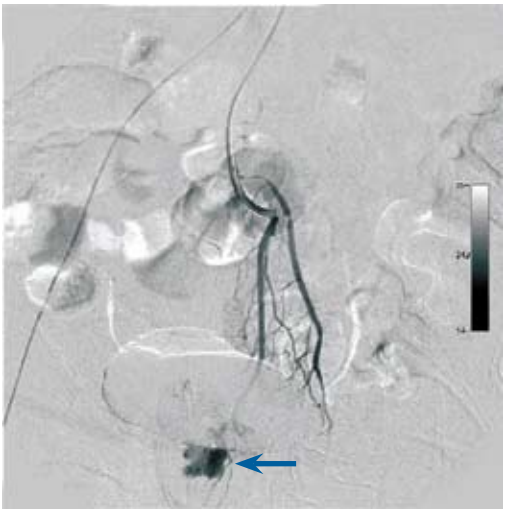

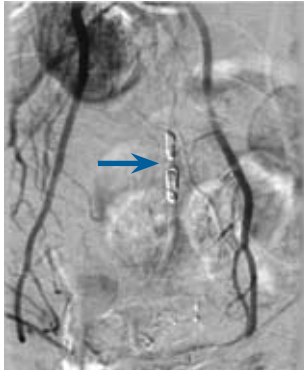

Figure 4. Arrest of hemorrhage following embolization: embolized branch (arrow)

rates than required for the detection of active hemorrhage during conventional angiography (0.3 ml/min compared to 0.5 ml/min respectively) [1]. It was also shown in a prospective study by Yoon et al. [2] to have a sensitivity of 90.9% and specificity of 99.0%. It also has the advantage of speed and availability, of being non-invasive, and having the ability to localize the bleeding site and sometimes the underlying pathology.

We suggest that in cases of acute gastrointestinal hemorrhage, when available, CT angiography should be performed immediately prior to angiography in order to facilitate directed and swift endovascular intervention.

Correspondence:
Dr. J. Singer-Jordan
17 Raqefet Street, Ma'alot 21017, Israel
Phone: (972-4) 957-0736
email: osdoctor@mac.com

References

1. Kuhle WG, Sheiman RG. Detection of active colonic hemorrhage with use of helical CT: findings in a swine model. *Radiology* 2003; 228: 743-52.
2. Yoon W, Jeong YY, Shin SS, et al. Acute massive gastrointestinal bleeding: detection and localization with arterial phase multi-detector row helical CT. *Radiology* 2006; 239: 160-7.