Spinal Stenosis: Example of Computed Tomography Findings

Osnat Halshtok MD

Department of Diagnostic Imaging, Sheba Medical Center, Tel Hashomer, Israel

KEY WORDS: lumbar spinal stenosis, neurogenic claudication, spinal surgery

IMAJ 2010; 12: 61

Lumbar spinal stenosis is an anatomical narrowing of the spinal canal. The characteristic symptom of lumbar spinal stenosis is neurogenic claudication, limping or cramping lumbar pain that radiates into the legs primarily during walking. Other symptoms include pain in the back, buttocks, thighs and/or lower legs, numbness or tingling in the leg or foot, or weakness in the leg or foot.

There are two types of stenoses, congenital (or developmental) and acquired (or degenerative) [1]. The stenosis can also be classified by etiology as primary (idiopathic, achondrodysplasia) and secondary (degenerative, infectious, neoplastic, etc.) [2]. The anatomic division is central, lateral or foraminal stenosis. This condition can be monosegmental or multisegmental, unilateral or bilateral. The L4-5 spinal disks are most frequently affected by lumbar spinal stenosis, followed by L3-4, L5-S1, and L1-2 [2]. Absolute stenosis has been defined as an antero-posterior lumbar spine diameter of less than 10 mm. Degenerative spinal stenosis is secondary to hypertrophy of one or more of the following elements: facet joint, ligamenta flava, posterior longitudinal ligament, intervertebral disk, epidural fat, and osteophytic disease of the vertebral body [3].

Lumbar spine surgery is performed mostly for this condition. Part of the reason for this is the advancement in imaging modalities, even though the presence or absence of clinical symptoms and their severity is of greater importance than the criteria for radiological abnormalities. Other options for treatment include physical therapy, epidural injections, chiropractic, and the use of anti-inflammatory drugs and opioid analgesics, but studies have shown greater amelioration of symptoms after surgical treatment [4].

The following example is of a 60 year old man with back pain and neurological symptoms that began 30 years prior to the magnetic resonance imaging scan shown here. This MRI was performed because of worsening of his symptoms in the 6 weeks prior to the scan. In the sagittal sequence [Figure 1] degenerative changes are visible, including narrowing of the disk spaces with bulging disks, and irregularity and fatty changes of end-plates known as "modic changes" are demonstrated. Spinal stenoses are demonstrated in several levels, the most severe in L3-4 and L4-5 [Figure 2].

Correspondence:
Dr. O. Halshtock
Dept. of Diagnostic Imaging, Sheba Medical Center, Tel Hashomer 52621, Israel
Phone: (972-3) 530-2530
email: osnatx@gmail.com

References

1. Kalichman L, Cole R, Kim DH, et al. Spinal stenosis prevalence and association with symptoms: the Framingham Study. *Spine J* 2009; 9: 545-55.
2. Siebert E, Prüss H, Klingebiel R, Failli V, Einhäupl KM, Schwab JM. Lumbar spinal stenosis: syndrome, diagnostics and treatment. *Nature Rev Neurol* 2009; 5: 392-403.
3. Joaquim AF, Sansur CA, Hamilton DK, Shaffrey CI. Degenerative lumbar stenosis. *Arq Neuro Psiquiat* 2009; 67(2-B): 553-8.
4. Weinstein JN, Tosteson TD, Lurie JD, and SPORT Investigators. Surgical versus nonsurgical therapy for lumbar spinal stenosis. *N Engl J Med* 2008; 358(8): 794-810.

Figure 1. T2 sagittal MRI sequence, showing narrowing of the disk spaces with bulging disks (short arrows). "Modic changes" are demonstrated in L2-3 disk space (long arrows). The lumbar spine is not completely shown due to scoliosis

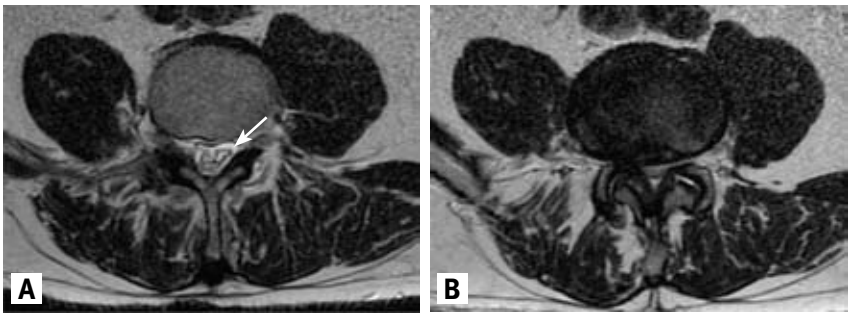

Figure 2. T2 axial MRI sequence of the same patient in the L4 level **[A]** and L4-5 disk level **[B]**. The cerebrospinal fluid, which was clearly visible around the nerves in the spinal canal at the level of L4 (arrow), is completely erased in the L4-5 disk level. The image **[B]** demonstrates a severe spinal stenosis of L4-5 disk level.