Endometriosis-related Hemoperitoneum in Late Pregnancy

Amir Naeh MD[1,2], Ilan Bruchim MD[1,2], Mordechai Hallak MD[1,2] and Rinat Gabbay-Benziv MD[1,2]

[1]Department of Obstetrics and Gynecology, Hillel Yaffe Medical Center, Hadera, Israel
[2]Rappaport Faculty of Medicine, Technion–Israel Institute of Technology, Haifa, Israel

KEY WORDS: endometriosis, hemoperitoneum, spontaneous hemoperitoneum in pregnancy (SHiP)

IMAJ 2019; 21: 557–559

Endometriosis is a common gynecologic entity. It is determined pathologically by the ectopic presence of endometrium, and clinically associated with pelvic pain, dysmenorrhea, and infertility. Although pregnancy is generally associated with regression of endometriosis-related symptoms, spontaneous hemoperitoneum in pregnancy (SHiP) may occur as a rare life-threatening complication.

We present a case of severe spontaneous hemoperitoneum in a primigravida with previously-established, deep, infiltrating endometriosis.

PATIENT DESCRIPTION

A 35-year-old nulliparous woman presented at 34 4/7 weeks of gestation with acute abdominal pain, which had commenced 2 hours prior to admission. Medical history was notable for severe deep infiltrating endometriosis. The woman had undergone laparoscopic surgery 2 years prior to the index pregnancy, in which many endometriosis lesions were removed and adhesiolysis was performed. During that surgery, a bladder perforation was recognized and repaired. The patient was otherwise healthy, with no other medical issues. The current pregnancy was achieved after in vitro fertilization with normal pregnancy surveillance.

At presentation, the woman was hemodynamically stable, without fever. She had no additional symptoms accompanying her abdominal pain. On physical examination, the abdomen was soft with tenderness localizing to the right lower quadrant. Her uterus was soft and non-tender. Pelvic examination revealed a firm, undilated cervix. Ultrasound demonstrated a viable fetus, with a full biophysical profile and no signs of placental abruption. A nonstress test was reassuring, without contractions. Complete blood count identified hemoglobin of 11 g/dl and 19,000 leukocytes.

Due to ongoing abdominal pain without evidence of obstetrical cause, the woman was sent for surgical consult for suspected acute appendicitis. Further workup included abdominal ultrasound scan [Figure 1A] followed by a magnetic resonance imaging scan, both of which failed to visualize the appendix and revealed fluid around the liver and in the right lower quadrant.

Following the initial examination and workup, the woman complained of worsening abdominal pain. On repeated evaluation she was hemodynamically stable but her abdomen was increasingly tender with signs of peritonitis. Lab tests showed stable hemoglobin level and reduction in the leukocyte count. At this point, due to signs of peritonitis, a decision was made to perform exploratory laparotomy. While preparing the woman for surgery, contractions started. Vaginal examination, revealed 1 cm dilation and cervix 70% effaced. Fetal heart rate was continuously reassuring.

Under general anesthesia, an open laparotomy was performed using a McBurney's incision. A normal appearing appendix was identified; however, acute bleeding was noted surrounding the appendix and filling the right gutter without a visible source. Dilated blood vessels were seen on the uterine surface with active bleeding that appeared to arise from the uterus. An appendectomy was performed, and the incision was elongated to enable exploration for the source of hemorrhage. Pelvic exploration revealed bleeding from multiple ruptured adhesions to the uterus. Due to active bleeding, gestational age, and the need for proper exploration, a decision was made to perform a cesarean section. A viable, 2000 gram male infant was delivered and the uterus was closed in a 2-layer suture. After closure of the uterine incision, full exploration of the abdomen and the pelvis was performed. Active bleeding from multiple ruptured adhesions to the anterior and posterior uterine walls was recognized. Complete hemostasis was achieved using coagulation, multiple sutures, and hemostatic agents. Bladder irrigation with methylene blue, performed following the appearance of hematuria, revealed no signs of bladder injury.

The initial postoperative period was uneventful. The patient received two units of packed cells with stabilization of hemoglobin levels and recovered well. The Foley catheter was removed 24 hours post-surgery but was reinserted the following day due to a sense of difficulty in complete emptying of the bladder. On postoperative day 5, the patient developed severe abdominal pain, and an abdominal computed tomography (CT) scan demonstrated the Foley catheter bulb located exterior to the urinary bladder in the pelvis, with secondary diffuse fluid loculations [Figure 1B], suggestive of bladder rupture. A second laparotomy was conducted, and a small rupture in the posterior wall of the bladder was identified with the Foley catheter passing through it, with diffuse pus in the peritoneal cavity. The bladder wall was closed by the urology team in three layers, and the abdomen was rinsed several times, until recovery of clear fluid.

Figure 1. [A] Abdominal ultrasound demonstrating small amount of free fluid (arrow) near the patient's liver; **[B]** Pelvic computed tomography scan demonstrating perforation of urinary bladder with a Foley catheter, and secondary diffuse fluid loculations

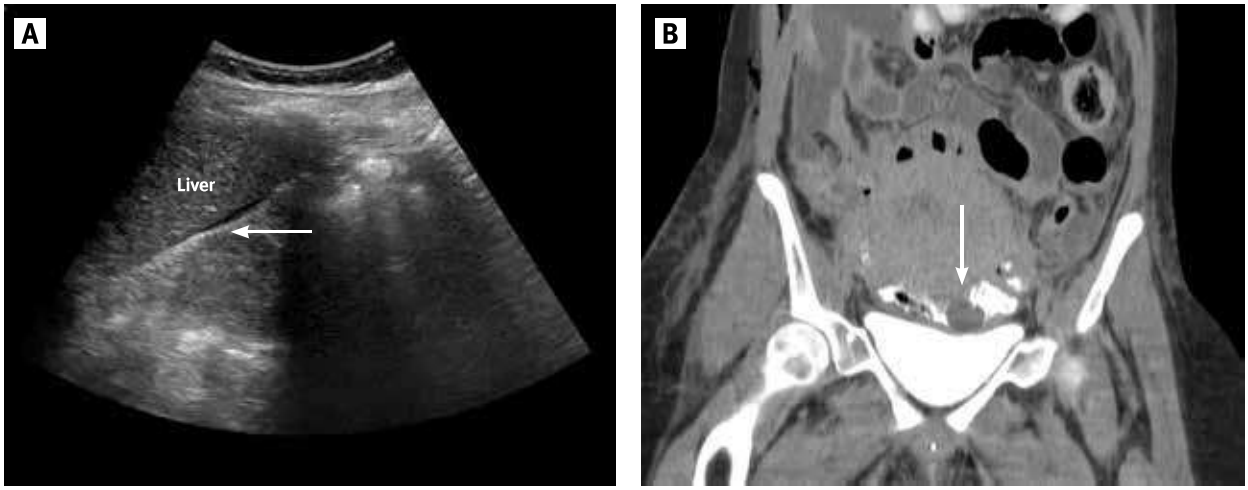

The patient was started on broad spectrum antibiotics and transferred to the intensive care unit. Subsequent recovery was without incident and the patient was discharged 2 weeks later.

COMMENT

Endometriosis is a common gynecologic condition, which affects approximately 10% of women of reproductive age. It is a chronic inflammatory disease, defined as the presence of endometrial-like tissue outside the uterine cavity. Common symptoms include dysmenorrhea, pelvic pain, dyspareunia, and infertility.

Pregnancy usually has beneficial effects on endometriosis by promoting involution of the endometrial implants. Nevertheless, spontaneous hemoperitoneum in pregnancy (SHiP) is a rare but life-threatening complication of endometriosis in pregnancy. Bleeding can occur secondary to ruptured pelvic adhesions, involution of decidualized endometriosis implants under falling levels of progesterone, or perforation of utero-ovarian vessels by invasive ectopic lesions. However, the exact pathophysiology of spontaneous bleeding in pregnancy is poorly understood [1].

A review of 75 cases of SHiP was first published in 1950 [2]. Three other case series were published in 1987 [3], 2009 [4], and 2017 [5]. Endometriosis is recognized as a major risk factor for SHiP, associated with more than 50% of cases. No apparent correlation between SHiP and stage of endometriosis was found [5]. In 27% of women diagnosed with endometriosis and SHiP, pregnancy was achieved using assisted reproductive technology [5].

In cases of SHiP, the presentation depends on the degree of bleeding. When massive hemorrhage occurs, the sudden onset of abdominal pain is associated with hypovolemic shock, a marked reduction of hemoglobin levels, and possible intrauterine fetal death [4]. When the quantity of bleeding is less severe, the symptoms have a much more gradual onset.

The diagnosis of SHiP is extremely challenging. The main presenting symptom is usually sudden onset of acute abdominal pain, which has a wide differential diagnosis, including gynecological and non-gynecological etiologies. The uncommon possibility of endometriosis-related SHiP is usually not considered, and the diagnosis is rarely made before laparotomy.

The most important imaging technique for the diagnosis of SHiP appears to be ultrasonography [5], as it is capable of detecting free fluid and ruling out other reasons for acute abdominal pain. However, as in our case, the sonographic preoperative diagnosis of SHiP may be difficult, especially when the hemoperitoneum consists mostly of clotted blood, gestational age is advanced, and maternal obesity is noted.

The treatment of SHiP is surgical and consists of aspirating the hemoperitoneum, identifying the bleeding source, and achieving full hemostasis. In most cases, intervention has been via laparotomy, although there are a few reports of successful laparoscopic treatment [5]. Few authors reported the need for hysterectomy to achieve hemostasis [5].

Due to advances in resuscitative and operative techniques, maternal mortality rates due to SHiP have significantly declined in the past 25 years from almost 50% [2]an unprovoked (nontraumatic to 0–3% [5]. However, fetal mortality has remained constant, at a rate of 31–36%, probably because of diagnosis after the appearance of maternal shock. The most important factors determining fetal outcome are the degree of prematurity, the extent of hemoperitoneum, and the severity of the hemodynamic shock [4].

CONCLUSIONS

Physicians should consider the rare possibility that endometriosis may lead to spontaneous bleeding and hemoperitoneum, especially in late pregnancy. This condition should be included in the differ-

ential diagnosis of acute abdominal pain in pregnancy, especially in women with known endometriosis. With advances in assisted reproductive technology, more women with endometriosis are successfully becoming pregnant, which may result in an increase incidence of SHiP. Greater awareness of this situation may facilitate the diagnosis and expedite the proper interventions to improve maternal and fetal outcomes.

Correspondence
Dr. A. Naeh
Dept. of Obstetrics and Gynecology Hillel Yaffe Medical Center, Hadera 38100, Israel
Fax: (972-4) 631-4916
email: amir_naeh@outlook.com

References

1. Vigano P, Corti L, Berlanda N. Beyond infertility: Obstetrical and postpartum complications associated with endometriosis and adenomyosis. *Fertil Steril* 2015; 104 (4): 802-12.
2. Hodgkinson CP, Christensen RC. Hemorrhage from ruptured utero-ovarian veins during pregnancy; report of 3 cases and review of the literature. *Am J Obstet Gynecol* 1950; 59 (5): 1112–7.
3. Ginsburg KA, Valdes C, Schnider G. Spontaneous utero-ovarian vessel rupture during pregnancy: three case reports and a review of the literature. *Obstet Gynecol* 1987; 69 (3 Pt 2): 474-6.
4. Brosens IA, Fusi L, Brosens JJ. Endometriosis is a risk factor for spontaneous hemoperitoneum during pregnancy. *Fertil Steril* 2009; 92 (4): 1243-5.
5. Lier MCI, Malik RF, Ket JCF, Lambalk CB, Brosens IA, Mijatovic V. Spontaneous hemoperitoneum in pregnancy (SHiP) and endometriosis – a systematic review of the recent literature. *Eur J Obstet Gynecol Reprod Biol* 2017; 219: 57-65.

Capsule

3D heart printing

3D bioprinting is still a fairly new technique that has been limited in terms of resolution and by the materials that can be printed. **Lee** et al. describe a 3D printing technique to build complex collagen scaffolds for engineering biological tissues. Collagen gelation was controlled by modulation of pH and could provide up to 10-micrometer resolution on printing. Cells could be embedded in the collagen or pores could be introduced into the scaffold via embedding of gelatin spheres. The authors demonstrated successful 3D printing of five components of the human heart spanning capillary to full-organ scale, which they validated for tissue and organ function.

Science 2019; 365: 482

Eitan Israeli

Capsule

Enhanced inhibitor

Epidermal growth factor receptor tyrosine kinase inhibitors (EGFR TKIs) block oncogenic receptor signaling and are used as a first-line treatment for EGFR-mutated non-small cell lung cancer. Resistance to EGFR TKIs, including the standard hyperfractionated EGFR TKI treatment (HyperTKI), is a problem that has driven the development of next-generation inhibitors. **Liu** et al. described the improved efficacy of hypofractionated EGFR TKI treatment (HypoTKI) relative to HyperTKI in triggering antitumor T cell responses and preventing relapse in a TKI-sensitive syngeneic murine tumor model through a mechanism involving immune signaling pathways. Coadministration of HypoTKI with an immunotherapy antibody further improved antitumor responses and reduced tumor relapse, thus suggesting that this combined therapy may be a potential alternative to existing treatment regimens.

Sci Immunol 2019; 4: eaav6473

Eitan Israeli

Capsule

How natural killer cells bind HLA Class II molecules

Natural killer (NK) cells are cytotoxic lymphocytes that recognize virus-infected, stressed cells and tumor cells with both activating and inhibitory receptors. Many NK cell receptors bind human leukocyte antigen (HLA) class I, which presents self-peptides but which is often lost within tumors and during infection. Whether and how NK cells might then bind HLA class II molecules, which are required for adaptive immunity, remains unclear. **Niehrs** and colleagues reported a direct functional interaction between the NK cell receptor NKp44 and a subset of commonly expressed HLA-DP molecules, including HLA-DP401. Intriguingly, the strength of NK cell binding and activation was both peptide- and HLA allotype-dependent. This work may help explain previously reported associations between certain HLA allotypes and some autoimmune, viral, and graft-versus-host disease outcomes.

Nat Immunol 2019; 10.1038/s41590-019-0448-4

Eitan Israeli