

Contact Sport-Induced Coronary Artery Dissection

Richard Haber MB BS (Hons) FRACP^{1,2} and George M. Weisz MD FRACS BA MA^{3,4}

¹Notre Dame University, Sydney, Australia

²Sydney University, Sydney, Australia

³University of New South Wales, Sydney, NSW, Australia

⁴School of Humanities, University of New England, Armidale, Australia

KEY WORDS: contact sports, coronary dissection, stent

IMAJ 2019; 21: 555–556

A relatively low velocity chest compression occurred in an otherwise healthy 29-year-old first grade football player during a game. The injury caused delayed coronary artery dissection resulting in ventricular fibrillation, a massive myocardial infarction, and anoxic brain injury. Four years after successful resuscitation and rehabilitation, he still has reduced left ventricular ejection fraction, but with only minor cognitive deficit.

Dissection of the coronary arterial wall is rarely seen in clinical experience, but it is seen in autopsy findings in arteriosclerotic cases. Dissection in sub-intimal or sub-adventitial areas results in obstruction of the lumen and ischemia of the distal myocardium, as in our case. This type of obstruction has recently been reported more often, probably due to increased awareness and improved diagnostic radiological techniques [1,2].

PATIENT DESCRIPTION

A 29-year-old healthy first grade football player experienced a direct hit by a shoulder to his sternal area during a game. He collapsed but quickly recovered and was able to complete the game for the next 10 minutes. He walked off the field, but soon afterwards experienced chest pain, malaise, and nausea. He was driven to a local country hospital. The initial electrocardiogram was normal, but after approximately 40 minutes he suddenly lost consciousness and had a grand mal seizure.

The second electrocardiogram showed ventricular fibrillation. Six electric shocks were given as part of his resuscitation, with repeated adrenalin injections, before he reverted to sinus rhythm. He then showed massive ST-segment elevation myocardial infarction (STEMI) and remained unconscious, but was breathing spontaneously. A computed tomography scan of the brain was performed and heparin and clopidogrel were administered. He was transferred by ambulance to a university hospital. Coronary angiogram showed intermittent occlusion of the proximal part of the anterior descending coronary artery, which was stabilized with two overlapping Resolute Integrity™ drug-eluting coronary stents (Medtronic, USA). The patient was admitted to the intensive care unit and later to the brain injury unit for a total of 2 months. He was discharged home where he continued with cardiac and brain injury rehabilitation programs. On review one year later, he had already returned to physical work.

PATHOLOGY RESULTS

The pathology reports showed that troponin I level was 418,477 (upper limit of normal is 26 ng/L). Venous blood gases showed oxygen saturation to be 56.7% and partial pressure of oxygen (pO₂) level was 50.8 mmHg (normal 25–40). Biochemistry results at the time of his discharge from hospital were normal.

ELECTROCARDIOGRAPHY

The results of the electrocardiogram initially were normal but soon showed ventricular fibrillation. When he reverted to sinus rhythm, he showed evidence of extensive anterior myocardial infarction [Figure 1]. The echocardiogram also showed mod-

erately dilated left ventricle, mild systolic segmental dysfunction with severe diastolic dysfunction, akinesis, and thinning of mid and apical septal wall with an ejection fraction of 30%.

CORONARY ANGIOGRAPHY

The coronary angiography showed intermittent stenosis of the left anterior descending coronary artery due to dissection, with slow refilling by collateral circulation [Figure 1B].

LEFT VENTRICULOGRAM

The left ventriculogram initially showed severe anterior hypokinesis with preserved function compared to other segments. Ejection fraction at discharge from hospital was about 30%.

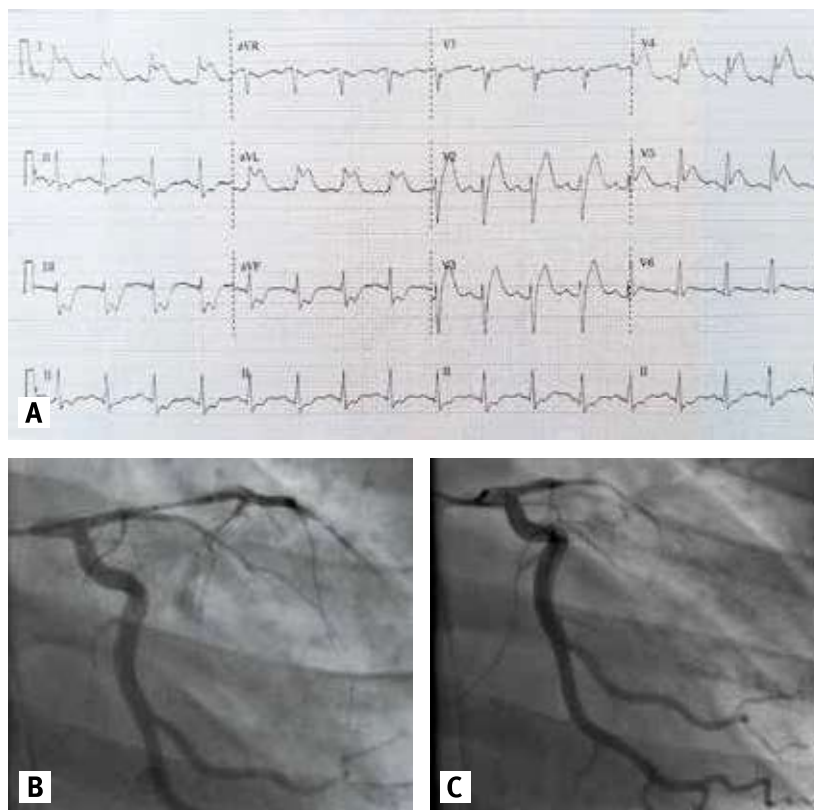
COMMENT

Coronary artery dissection is usually either the result of direct chest trauma in patients after a car accident or with arteriosclerotic arteries. It also occurs in young women with prolonged obstetrical delivery [4]. Rupture may be fatal immediately or it may be delayed.

We note the possibility that dissection of a major coronary artery may occur, even with relatively minor compressive chest trauma, in an otherwise healthy young person. This event may have a disastrous delayed effect, as in our case and also as reported by Bjørnstad et al. [3].

An initial normal electrocardiogram does not exclude the immediate dissection. Successful primary stenting for traumatic coronary artery dissection has been described in an 18-year-old man after the diagnosis was made [5]. Bypass surgery has also been performed in a number of cases.

Figure 1. The results of the electrocardiogram [A] sinus rhythm with STEMI [B] coronary angiography showing intermittent occlusion [C] intermittent occlusion of coronary artery



CONCLUSIONS

Our case presents a young man with coronary artery dissection, with no predispos-

ing condition and with relatively low velocity direct trauma to the chest, but with successful recovery. From an extensive STEMI

and hypoxic cerebral damage in a healthy sportsman, with initial hepatic and renal biochemical changes, he fully recovered. As the result of successful rehabilitation, at 4 years post-coronary artery dissection, there was minor residual memory loss and minimal speech deficit. He had no residual cardiac symptoms, but cardiac echocardiogram still shows significant impairment, with left ventricular ejection fraction of about 34%, diastolic dysfunction, and moderately dilated left ventricle.

Correspondence

Dr. G.M. Weisz

School of Humanities University of New England, Armidale, and University of New South Wales, Sydney, NSW, Australia
email: gmweiszi@aol.com

References

- Swinkels BM, Hoedemaker G, Peters RHJ. Coronary artery dissections following blunt chest trauma: a case report. *Neth. Heart J* 2005; 13 (5): 191-2.
- Maheshwari A, Thenapan T, Das G L. Adding fuel to the fire: coronary artery dissection complicating blunt chest trauma. *Am J Emerg Med* 2017; 25 (7): 1041.e5-e6.
- Bjornstad JL, Pillgram-Larsen J, Tonnessen T. Coronary artery dissection and acute myocardial infarction following blunt chest trauma. *World J Emerg Surg* 2009; 4. 14: 1-4.
- Saw J, Mancini J, Humphries K. Contemporary review on spontaneous coronary artery dissection. *J Am Coll Cardiol* 2016; 68 (3): 297-312.
- Shukur AM. Primary Stenting for traumatic coronary artery dissection resulting from blunt chest trauma – a case report. *Int J Angiol* 2004; 13 (2): 86-8.

Capsule

How the brain perceives music

Music can bring great joy to our lives, yet the extent to which humans find music pleasurable varies greatly. Several brain regions have been suggested to play a role in music perception, but we do not yet understand how they connect. **Martínez-Molina** et al. looked at brain areas such as the superior temporal gyrus, nucleus accumbens, and the orbitofrontal cortex known to be involved in experiencing reward and integration of information. They found differences

in the microstructure of white-matter pathways between these brain regions in healthy adults. When the relationship of these pathways with the individuals' specific musical sensibility was tested, the authors concluded that details of the structure of the white-matter pathways influences the extent to which individuals perceive music as pleasurable.

J. Neurosci. 2019;39: 5018

Eitan Israeli

“It is impossible to enjoy idling thoroughly unless one has plenty of work to do. There is no fun in doing nothing when you have nothing to do. Wasting time is merely an occupation then, and a most exhausting one. Idleness, like kisses, to be sweet must be stolen”

Jerome K. Jerome (1859–1927), humorist and playwright