

Noma Neonatorum: A Disease Long Forgotten

Micky Osovsky MD¹, Eric Barel MD² and Ad-El Dean MD²

Departments of ¹Neonatology and ²Plastic Surgery and Burns, Rabin Medical Center (Beilinson Campus), Petah Tikva, Israel

KEY WORDS: gangrene, infection, neonate, noma neonatorum, pseudomonas

IMAJ 2018; 20: 784–785

Noma neonatorum is a rare gangrenous disease causing progressive mutilating tissue destruction of soft tissue and bone [1]. It usually affects low birth weight infants, especially premature infants presenting with severe co-morbid pathologies [1,2].

Noma neonatorum should be differentiated from noma, which is a gangrenous disease leading to facial tissue destruction with severe morbidity and mortality. Noma is still frequently seen in children and young adults in India, Africa, and South America. Its pathogenesis is most likely related to malnutrition, polymicrobial infection, and immune dysfunction [2].

In 1978, Ghosal et al. [3] described the only case series of 48 premature infants, most of them fatally infected with *Pseudomonas aeruginosa* presenting with gangrenous lesions similar to noma described in older children. Areas involved were the nose, lips, mouth, and anal region. The age at disease onset was typically during the first 2 weeks of life.

The most frequent pathogen isolated and associated with noma neonatorum is *Pseudomonas aeruginosa*, usually with a fatal outcome. All cases of neonatal noma had similar characteristics distinct from the older age group of noma patients; hence, they were termed noma neonatorum [3]. Since Ghosal, only a few cases have been reported sporadically in the literature, and most have come from developing countries.

We report a special case of noma neonatorum in a premature infant. The lesion evolved very early during the neonate's hospitalization, despite common practice in a general neonatal care unit. Facial involvement, rapid deterioration, and involvement of the deep tissues, including the soft and hard palate, suggested noma as the diagnosis.

The ulcerative noma lesions are often found in the facial area, especially under tubing fixations, including nasogastric or endotracheal tubes. Treatment should be prompt and aggressive.

PATIENT DESCRIPTION

We report a male infant, the second of concordant twins, born by vaginal delivery at 28 weeks gestation with a birth weight

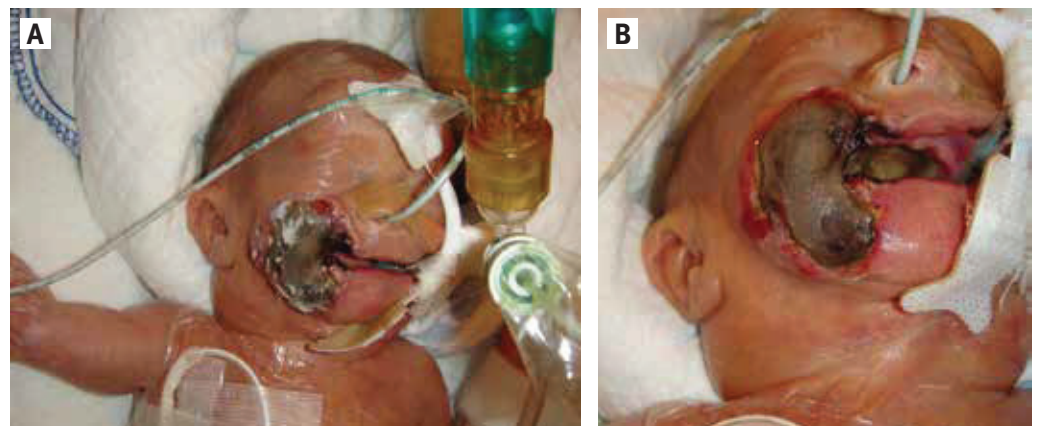
of 1170 grams. There were no signs or symptoms for chorioamnionitis. Placental cultures were negative. He was intubated in the delivery room and treated with a first dose of surfactant.

During his first postnatal days of life, our patient presented with severe respiratory distress syndrome. He was treated with two additional doses of surfactant and was ventilated on high frequency ventilation due to failure of conventional ventilation. Because of a left pneumothorax on the second day of life, a thoracic drain was inserted. He required frequent intravenous fluid boluses and treatment with inotropes, including dopamine and dobutamine.

There were signs of pulmonary hypertension in echocardiography and severe anasarca on physical examination. Hydrocortisone was added to the treatment on the fifth day of life to stabilize his blood pressure.

The first head ultrasound was performed on the second day of life. It showed bulkiness of the choroid plexus bilaterally. A second ultrasound was performed on the fifth day of life demonstrating intraventricular hemorrhage grade 3 on the left, and grade 2 on the right.

Figure 1.
[A] Ulcer over the right cheek involving deep facial tissues
[B] Involvement of deep facial tissues and hard palate



On the sixth day of life a small erythematous lesion, which looked like a decubitus ulcer, appeared on the right cheek under the endotracheal tube taping. This ulcer was accompanied by worsening thrombocytopenia and elevated C-reactive protein. Broad spectrum antibiotic treatment with vancomycin and meropenem was started. Blood and sputum culture on the seventh day of life grew *Citrobacter koseri*, which was sensitive to cefotaxime.

The ulcer over the right cheek expanded rapidly to a size of 3 × 3 cm and involved deep facial tissues over the maxillary area, including the soft and hard palate [Figures 1A and 1B].

After a plastic surgical consultation, antibiotic treatment was changed again to broad spectrum antibiotic coverage with meropenem, and local treatment was added with sulfadiazine. Despite intensive care treatment and broad spectrum antibiotic treatment, the patient died on his fifteenth day of life.

COMMENT

Noma neonatorum is a rare gangrenous disease causing progressive mutilating tissue destruction of soft tissue and bone [1]. It should be differentiated from noma in older children. The former appears during the first months of life, with *Pseudomonas* being the most frequent bacteria found.

The latter has been described in children 2 to 5 years of age with different types of bacteria species [4].

The first case series of noma neonatorum was published by Ghosal and co-authors in 1978 [3]. They reported 48 cases. Since then, only a few cases of noma neonatorum have been published.

The oral cavity is the most commonly involved site. Other sites have included the nose, eyelids, umbilicus, scrotum, and groin [3,5]. Reported onset was from the third postnatal day to 120 days of age. *Pseudomonas* was isolated from all cases. In the majority of cases, the disease was fatal. Treatment should be supportive and aggressive including anti-*Pseudomonas* antibiotic treatment.

No early extensive surgical repair is indicated, and reconstructive surgery should be postponed to 1 year post-resolution [1,3,5].

CONCLUSIONS

Our goal was to highlight a disease rarely seen in the Western world. In our case, noma neonatorum appeared in a premature infant, the second of preterm twins.

To the best of our knowledge, ours is the first case reported in such a young preterm infant, appropriate for gestational age, with no evidence of intrauterine growth restriction. The lesion evolved very early during the neonate's hospitalization. Common neonatal practice was used, including total

parenteral nutrition supplementation. The facial involvement, rapid deterioration, and involvement of the deep tissues, including the soft and hard palate, suggested noma neonatorum as the diagnosis.

Clinicians should look for ulcerative lesions in the facial area, especially under tubing fixations like nasogastric or endotracheal tubings. Treatment must be prompt and aggressive, and comprise broad spectrum antibiotics, including coverage for *Pseudomonas*.

Correspondence

Dr. M. Osovsky
 Dept. of Neonatology, Rabin Medical Center (Beilinson Campus), Petah Tikva 4941492, Israel
Phone: (972-3) 937-7474
Fax: (972-3) 937-7469
email: micky.osovsky@gmail.com

References

1. Parikh TB, Nanavati RN, Udani RH. Noma neonatorum. *Indian J Pediatr* 2006; 73 (5): 439-40.
2. Lin JY, Wang DW, Peng CT, Tsai FJ, Chiou YM, Tsai CH. Noma neonatorum: an unusual case of noma involving a full-term neonate. *Acta Paediatr* 1992; 81 (9): 720-2.
3. Ghosal SP, Sen Gupta PC, Mukherjee AK, Choudhury M, Dutta N, Sarkar AK. Noma neonatorum: its aetiopathogenesis. *Lancet* 1978; 2 (8084): 289-91.
4. Raimondi F, Veropalumbo C, Coppola C, et al. Noma neonatorum from multidrug-resistant *Pseudomonas aeruginosa*: an underestimated threat? *J Pediatric Infect Dis Soc* 2015; 4 (3): e25-7.
5. Prajapati NC, Chaturvedi P, Bhowate RR, Mishra S. Noma neonatorum. *Indian Pediatr* 1995; 32 (9): 1019-21.

Capsule

Modeling sporadic ALS in iPSC-derived motor neurons identifies a potential therapeutic agent

Amyotrophic lateral sclerosis (ALS) is a heterogeneous motor neuron disease for which no effective treatment is available, despite decades of research into *SOD1*-mutant familial ALS (FALS). The majority of ALS patients have no familial history, making the modeling of sporadic ALS (SALS) essential to the development of ALS therapeutics. However, as mutations underlying ALS pathogenesis have not yet been identified, it remains difficult to establish useful models of SALS. Using induced pluripotent stem cell (iPSC) technology to generate stem and differentiated cells retaining the patients' full genetic information, **Fujimori** et al. established a large number of in vitro cellular models of SALS. These models showed phenotypic differences in their pattern of neuronal

degeneration, types of abnormal protein aggregates, cell death mechanisms, and onset and progression of these phenotypes in vitro among cases. The authors therefore developed a system for case clustering capable of subdividing these heterogeneous SALS models by their in vitro characteristics. They further evaluated multiple-phenotype rescue of these subclassified SALS models using agents selected from non-*SOD1* FALS models, and identified ropinirole as a potential therapeutic candidate. Integration of the datasets acquired in this study permitted the visualization of molecular pathologies shared across a wide range of SALS models.

Nature Med 2018; 24: 1579
 Eitan Israeli