

Childhood Limb Poliomyelitis as a Suspected Etiology for a Contra-Lateral Femoral Arteriomegaly and Aneurysm Formation

Dallit Mannheim MD¹ and Ron Karmeli MD²

¹Department of Vascular Surgery, Carmel Medical Center, Haifa, Israel

²Department of Vascular Surgery, Hadassah Medical Center, Jerusalem, Israel

KEY WORDS: aneurysm, arteriomegaly, endovascular, poliomyelitis, superficial femoral artery

IMAJ 2018; 20: 454–455

PATIENT DESCRIPTION

A 64 year old man presented to our vascular clinic in October 2011 with a pulsatile mass in his left hip. The patient denied associated symptoms of local pain, edema, or intermittent claudication and walked independently without walking aids. His past history was significant for childhood poliomyelitis resulting in permanent paresis of his contralateral leg, hypertension, and smoking. There was no family history of aneurysm disease and no history of surgery, arterial catheterization, or trauma

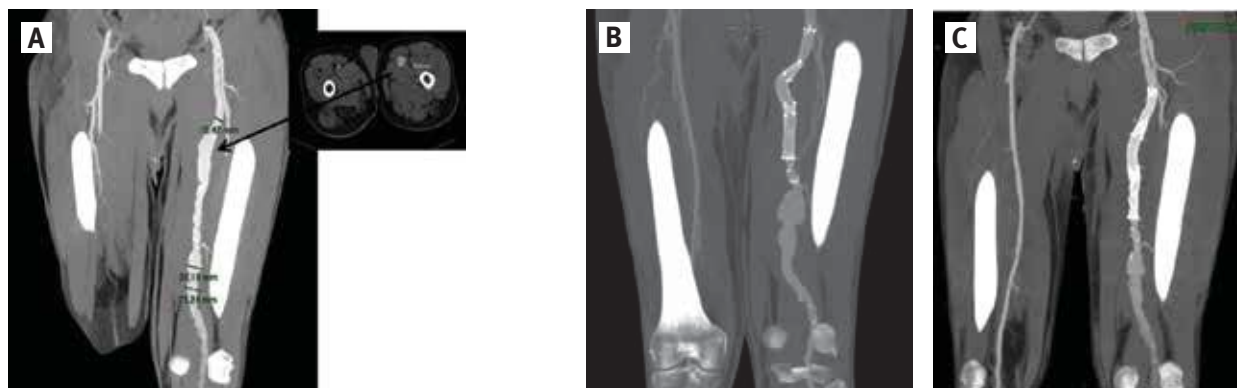
to his non-paretic leg. The patient's physical examination revealed a non-tender pulsatile mass in his left hip with palpable popliteal pulse and no pedal pulses. The right leg showed signs of diffused muscular atrophy with normal distal pulses. Computed tomography (CTA) showed normal aorto-iliacs, right leg arteries, and an arteriomegaly of the left superficial femoral artery (SFA) without involvement of the poplitea and with a single artery runoff of the peroneal artery. The proximal SFA demonstrated an aneurismal degeneration of a 3.4 cm in diameter [Figure 1A]. The aneurysm of the proximal SFA was repaired with overlapping covered stents (Fluency[®] 120 × 8 mm, and two 120 × 60 mm, Bard Peripheral Vascular, Inc, Tempe, AZ, USA) [Figure 1B]. On follow-up (4 years later) an aneurysm of 4 cm was diagnosed distal to the previous repair [Figure 1C]. The aneurysm was treated with additional covered stents overlapping

with the previous stents up to the poplitea (Fluency[®] 100 × 12mm, Viabahn[®] 150 × 10 mm, Bard Peripheral Vascular, Inc.), with a good morphological result. As of the time of the submission of this article, the patient had been asymptomatic with no significant claudication. When examining this patient's flow patterns, we found a 20% increase in flow in the non-paralytic leg compared with the paralytic limb (420 vs. 340 cc/min, in 3 consecutive measurements in CFA). The non-paralytic limb was within the range of flow in matched controls (400–450 cc/min).

COMMENT

This patient presented with arteriomegaly of his healthy leg, which later degenerated to aneurysms. Arteriomegaly has been shown to progress to aneurysms in most patients, and femoral artery aneurysms have been shown to correlate with arte-

Figure 1. [A] Initial computed tomography (CTA) with arteriomegaly and a 3.4 cm proximal superficial femoral artery (SFA) aneurysm, [B] CTA after covered stent implantation, [C] 4 years later with a 4 cm distal SFA aneurysm



riomegaly as well as multiple aneurysms, including contralateral SFA, popliteal, iliac, and aortic [1]. Past reports have demonstrated that femoral artery aneurysms with arteriomegaly are always accompanied by multiple aneurysms [1]. This patient's arteriomegaly and aneurysms were isolate only to his healthy leg, which also demonstrated an increase in blood flow.

Studies have shown a decrease in lumen width and reduced arterial flow in paralytic limbs as compared to the normal ones [2], and an increase in diameter and blood flow in the intact limb of athletes after below knee amputation of the contralateral leg [3].

Arterial hypertrophy and aneurysm formation have been reported in situations of increased blood flow as seen in A-V fistulas created for dialysis access and congenital A-V fistulas. Patients with high-flux hemodialysis had a 5.3-fold higher risk of vascular access aneurysm [4].

Hemodynamic changes, as seen in major lower limb amputation and chronic spinal cord injury, predispose patients to an increased risk for late abdominal aortic aneurysm formation independent of other recognized systemic factors, such as cigarette smoking or obesity [5].

It might be speculated that the unique flow pattern in this patient's non-paralytic limb, with high flow over a long period of time (more than 50 years), including the growth period of adolescence with no atherosclerotic disease to influence the vessel wall remodeling, might have led to arteriomegaly and later even aneurysm formation.

CONCLUSIONS

This case might support the assumption that high flow and turbulence can be part of the etiology for aneurysm formation. We recommend screening of the healthy limbs in unilateral long-term paralysis.

Correspondence

Dr. D. Mannheim

Dept. of Vascular Surgery, Carmel Medical Center, Haifa 3436212, Israel

Phone: (972-4) 825-0290, **Fax:** (972-4) 825-0989

email: dallit@gmail.com

References

1. Barandiaran JV1, Hall TC, Glaves I, El-Barghouti N, Perry EP. An observational study into the management of arteriomegaly: a call for a revised classification system. *Ann R Coll Surg Engl* 2012; 94 (4): 250-5.
2. Grande NR, dos Santos JM. Limb immobilization and intimal hyperplasia--an echo-Doppler study in man. *Surg Radiol Anat* 1999; 21 (1): 23-8.
3. Huonker M, Schmid A, Schmidt-Trucksass A, Grathwohl D, Keul J. Size and blood flow of central and peripheral arteries in highly trained able-bodied and disabled athletes. *J Appl Physiol* (1985) 2003; 95 (2): 685-91.
4. Jankovic A, Donfrid B, Adam J, et al. Arteriovenous fistula aneurysm in patients on regular hemodialysis: prevalence and risk factors. *Nephron Clin Pract* 2013; 124 (1-2): 94-8.
5. Vollmar JF, Paes E, Pauschinger P, Henze E, Friesch A. Aortic aneurysms as late sequelae of above-knee amputation. *Lancet* 1989; 2 (8667): 834-5.

Capsule

Dyslipidemia, alcohol consumption, and obesity as main factors associated with poor control of urate levels in patients receiving-urate-lowering therapy

In real life, in a substantial proportion of gouty patients receiving urate-lowering therapy (ULT), urate levels are not maintained below the target of 6.0 mg/dl. **Latourte** and co-authors aimed to search for factors associated with poor control of serum uric acid (UA) levels in a large population of patients with gout receiving ULT. This cross-sectional study involved adults with gout in primary care who were receiving ULT. Demographics, gout history, co-morbidities, lifestyle, clinical factors, concomitant treatments, and laboratory data were compared in well-controlled gout (serum UA ≤ 6.0 mg/dl) versus poorly controlled gout (serum UA > 6.0 mg/dl) on univariate and multivariate analyses. Among the 1995 patients receiving ULT, only 445 (22.3%) had reached the target of 6.0 mg/dl serum UA. Such patients had a lower rate of gout flares within the previous year than

patients without the target (mean 1.7 ± 1.4 vs. 2.1 ± 1.4; P < 0.0001). The main factors associated with poor serum UA level control in multivariate analysis were low high-density lipoprotein cholesterol level (adjusted odds ratio [OR] 0.5, 95% confidence interval [95%CI] 0.26–0.96, P = 0.04), high total cholesterol level (OR 1.83, 95%CI 1.29–2.60, P = 0.0007), increased waist circumference (OR 1.55, 95%CI 1.11–2.13, P = 0.008), and alcohol consumption (OR 1.52, 95%CI 1.15–2.00, P = 0.003). Dyslipidemia, abdominal obesity, and alcohol consumption are the main factors associated with a poor response to ULT. Knowledge of these factors might help physicians identify cases of gout that may be less likely to achieve target urate level.

Arthritis Care Res 2018; 70: 918
Eitan Israeli

“I not only use all the brains I have, but all I can borrow, and I have borrowed a lot”

Thomas Woodrow Wilson, (1856–1924), 28th president of the United States, leading architect behind the League of Nations, Nobel laureate

“The life of every man is a diary in which he means to write one story, and writes another, and his humblest hour is when he compares the volume as it is with what he vowed to make it”

Sir James Matthew Barrie, 1st Baronet, (1860–1937), Scottish novelist and playwright, best remembered as the creator of Peter Pan