

Digital Ischemia in a Patient with Recent Influenza A Infection

Alexander Korytny MD¹, Adi Kibari MD², Itzhak Rosner MD^{3,4} and Devy Zisman MD^{2,4}

¹Department of Internal Medicine and ²Rheumatology Unit, Carmel Medical Center, Haifa, Israel

³Department of Rheumatology, Bnai Zion Medical Center, Haifa, Israel

⁴Rappaport Faculty of Medicine, Technion–Israel Institute of Technology, Haifa, Israel

KEY WORDS: digital ischemia, influenza, ischemia

IMAJ 2018; 20: 446–447

Influenza infection has been associated with various complications, some of which include autoimmune mechanisms. While organizing pneumonia is a well-described complication of influenza A virus infection, vasculitides and ischemic events are more rare. In our report, to the best of our knowledge, we describe the first case of digital ischemia in a patient with recent influenza A infection.

PATIENT DESCRIPTION

A 54 year old previously healthy man was referred to our hospital because of a dry cough, fever, and painful bluish discoloration of the distal phalanges of the

fingers [Figure 1A]. He denied smoking, weight loss, night sweats, exposure to sick people or animals, recent travel abroad, or exposure to chemicals or asbestos. His only medication was alendronate, which he had been taking for years. Physical examination revealed bilateral diffuse crackles on auscultation and bluish discoloration of distal phalanges on both hands. Room air oxygen saturation was 85%.

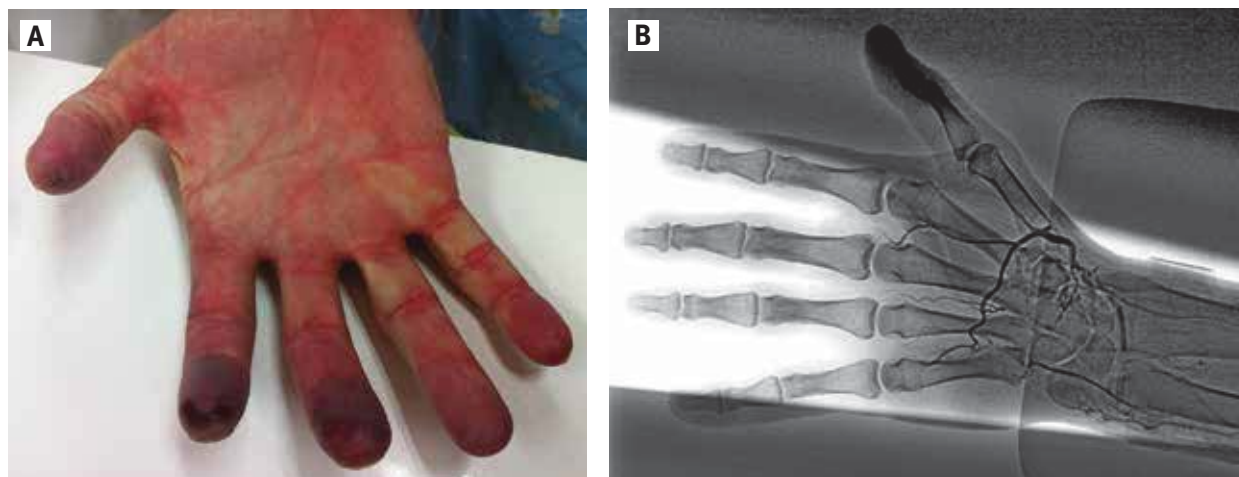
Laboratory workup included complete blood count. Kidney and liver function tests were within normal limits. Blood cultures were negative, as were serologic tests for hepatitis B, hepatitis C, Q fever, mycoplasma, *Rickettsia typhi*, *Rickettsia conori*, cytomegalovirus immunoglobulin M (IgM), and Epstein-Barr virus IgM.

Polymerase chain reaction (PCR) assay from bronchial lavage was positive for influenza A and negative for influenza B, parainfluenza, metapneumovirus, and rhi-

novirus, respiratory syncytial virus (RSV), H1N1, and adenovirus. Immunology tests including rheumatoid factor, anti-nuclear antibodies, anti-double-strand DNA, anti-Sjögren's-syndrome-related antigen A (anti-SSA), anti-SSB, anti-centromere, anti-neutrophil-cytoplasmic antibodies (ANCA) including c-ANCA and p-ANCA, cryoglobulins, anti-b2 glycoprotein IgG and IgM, anti-cardiolipin antibodies (ACA) IgM, and *anti-glomerular basement membrane* antibodies were all negative. Complement levels (C3 and C4), angiotensin converting enzyme as well as dilute Russell viper venom time were within normal limits. ACA IgG revealed low positive titers at the beginning while repeated tests were negative.

Chest X-ray was normal, but pulmonary function test revealed mixed obstructive and restrictive disease. Chest computerized tomography showed consolidations

Figure 1. [A] Ischemic distal phalanges [B] Palm angiography of the patient's hand



and diffuse reticular and ground glass opacities in both lung bases and lingula. Treatment with broad spectrum antibiotics and antiviral therapy brought only minor improvement. Open lung biopsy demonstrated changes consistent with organizing pneumonia. Palm angiography performed due to worsening ischemia disclosed hypoplastic ulnar artery without anastomoses with the palmar arch, absent 1st and 5th palmar digital arteries, and extreme narrowing of other palmar arteries. No atherosclerotic plaques, microaneurysms, or collateral vessels consistent with Burger's disease were found (Figure 1B).

Treatment with high dose corticosteroids, iloprost, and enoxaparin was initiated. Respiratory symptoms improved rapidly, but the digital ischemia worsened. Following several hyperbaric oxygen treatments (HOT), the intractable ulcers improved. Repeat anticardiolipin serology was negative; hence, anticoagulation was stopped. The patient was treated with steroid sparing regimens, including azathioprine, and subsequently with cyclophosphamide, iloprost, and HOT, with only partial improvement of the digital ulcers.

COMMENT

We describe a patient with organizing pneumonia and digital ischemia, which developed after influenza A infection. A wide spectrum of complications were described after influenza virus infection, part of which is caused by autoimmune

mechanisms. Vasculitis as an adverse effect of influenza vaccination, including leukocytoclastic vasculitis, Henoch–Schoenlein purpura, and ANCA-associated vasculitis, have been reported [1]. However, reports of systemic vasculitis as a sequela of influenza infection are scarce [2]. The mechanisms by which an infectious agent triggers a vasculitic process include direct pathogen invasion and damage of the endothelial cells, immune-mediated damage to the vessel walls, and stimulation of lymphocyte proliferation [3].

An increased risk of ischemic complications, such as stroke and myocardial infarction, were associated with acute infection in a large data based study, while other research highlighted the association between influenza infections and thrombotic events [4].

Stimulation of an inflammatory mechanism and activation of a prothrombotic state by the infectious trigger were suggested as the pathological link between the two conditions [5]. The production of antiphospholipid antibodies is one of the possible links involved in this mechanism.

Since skin biopsy had not been performed, the mechanism responsive for ischemic changes in our case could only be assumed. We suspect thrombotic etiology of digital ulcers because of positive anticardiolipin serology, hence anticoagulation was initiated. Repeated serology assay was negative, excluding diagnosis of antiphospholipid syndrome, so anticoagulation was stopped. Clinical improvement was shown

with HOT in patients with severe, nonhealing vasculitis-induced ulcers that did not respond to immunosuppressive therapy. Our patient improved after immunosuppressive therapy and several courses of HOT.

CONCLUSIONS

Influenza infection has been associated with a number of complications, some of which involve autoimmune mechanisms and ischemic complications. It is important to acknowledge possible complications since influenza infection is very common. Digital ischemia is a potential complication that requires aggressive treatment.

Correspondence

Dr. D. Zisman
 Rheumatology Unit, Carmel Medical Center,
 Haifa 34362, Israel
Phone: (972-4) 825-0486
Fax: (972-4) 826-0213
email: devyzisman@gmail.com

References

1. Zafrir Y, Agmon-Levin N, Shoenfeld Y. Post-influenza vaccination vasculitides: a possible new entity. *Clin Rheumatol* 2009; 15 (6): 269-70.
2. Urso R, Bevilacqua N, Gentile M, Biagioli D, Lauria FN. Pandemic 2009 H1N1 virus infection associated with purpuric skin lesions: a case report. *J Med Case Rep* 2011; 5: 132.
3. Lidar M, Lipschitz N, Langevitz P, Shoenfeld Y. The infectious etiology of vasculitis. *Autoimmunity* 2009; 42: 432-8.
4. Foster ED, Cavanaugh JE, Haynes WG, et al. Acute myocardial infarctions, strokes and influenza: seasonal and pandemic effects. *Epidemiol Infect* 2013; 141: 735-44.
5. Lindsberg PJ, Grau AJ. Inflammation and infections as risk factors for ischemic stroke. *Stroke* 2003; 34: 2518–32.

Capsule

Apoptotic cell-induced AhR activity is required for immunological tolerance and suppression of systemic lupus erythematosus in mice and humans

The transcription factor AhR modulates immunity at multiple levels. **Shinde** and colleagues reported that phagocytes exposed to apoptotic cells exhibited rapid activation of AhR, which drove production of the cytokine IL-10. Activation of AhR was dependent on interactions between apoptotic-cell DNA and the pattern-recognition receptor TLR9 that was required for the prevention of immune responses to DNA and histones in vivo. Moreover, disease progression in mouse systemic lupus erythematosus (SLE) correlated with

strength of the AhR signal, and the disease course could be altered by modulation of AhR activity. Deletion of AhR in the myeloid lineage caused systemic autoimmunity in mice, and an enhanced AhR transcriptional signature correlated with disease in patients with SLE. Thus, AhR activity induced by apoptotic cell phagocytes maintains peripheral tolerance.

Nature Immunology 2018; 19: 571
 Eitan Israeli