

Pancreatic Cyst Mucin Ball Aspiration as a Diagnostic Maneuver

Wisam Sbeit MD¹, Anas Kadah MD², Moaad Farraj MD³ and Moshe Shiller MD¹

¹Department of Gastroenterology, ²Department of Internal Medicine D and ³Department of Surgery B, Galilee Medical Center, Nahariya, Israel

³Faculty of Medicine in the Galilee, Bar-Ilan University, Safed, Israel

KEY WORDS: endoscopic ultrasound (EUS), epithelial nodule, fine needle aspiration (FNA), mucin ball, pancreatic cyst

IMAJ 2018; 20: 394

A 64 year old female was referred for endoscopic ultrasound (EUS) for further investigation of a multifocal cystic lesion in her pancreas that was discovered incidentally by an abdominal contrast enhanced computed tomography scan as part of oncologic surveillance after a mastectomy. EUS by curved linear array echo endoscope demonstrated innumerable cysts of various sizes distributed along all the pancreatic parenchyma, with connection to the pancreatic duct. The biggest cyst was seen in the pancreatic head, measuring 27 mm in diameter without wall thickening, but with a round hyperechoic structure adjacent to the cyst wall. The cyst was suspected to represent a mucin ball. Fine needle aspiration was performed from this large cyst using a 22 gauge needle. The hyperechoic structure was punctured and aspirated through the needle [Figure 1, Figure 2], leaving no doubt that it

was a mucin ball and not an epithelial nodule. Analysis of aspirated fluid revealed high levels of amylase of up to 85000 U/L, carcinoembryonic antigen up to 5807 ng/ml, and paucicellular cytopathology without suspicious cells. These findings are compatible with branch duct intraductal papillary mucinous neoplasm (IPMN). Repeated EUS 1 year later showed the same pancreatic cysts but without the mucin ball seen in the previous EUS [Figure 3].

Mucus producing cystic neoplasms of the pancreas, including IPMN and mucinous cystic neoplasm, are premalignant cystic lesions. Mural epithelial nodules are predictors of malignancy, in contrast to intracystic mucin balls. Differentiating between them has tremendous implications on how the patient's case is managed.

There are three characteristic EUS features that can distinguish a mucin ball from mural nodules. These features are round shape, smooth edges, and anechoic center with an echoic rim [1]. Still, the specificity of EUS for protruding lesions within pancreatic cysts is only about 33% [2], and the mere presence of an intracystic echogenic lesion is a poor predictor of an epithelial nodule on pathology [1]. Suggested maneu-

vers for differentiating mucin balls from epithelial nodules included body position change, dislodging or moving the echogenic lesion with the needle tip, or cyst aspiration. These maneuvers correctly diagnosed mucus in 100% of cases [1].

In the images provided, we could clearly show that the hyperechoic intracystic structure was a mucin ball, which was aspirated through the needle. Aspirating an encountered intracystic hyperechoic structure is an easy and obvious maneuver to differentiate a mucin ball from a premalignant epithelial nodule.

Correspondence

Dr. W. Sbeit

Dept. of Gastroenterology, Galilee Medical Center, Nahariya 22100, Israel

Phone: (972-4) 910-7620, **Fax:** (972-4) 910-7545

email: wisams@gmc.gov.il

References

1. Zhong N, Zhang L, Takahashi N, et al. Histologic and imaging features of mural nodules in mucinous pancreatic cysts. *Clin Gastroenterol Hepatol* 2012; 10: 192-8.
2. Nakagawa A, Yamaguchi T, Ohtsuka M, et al. Usefulness of multidetector computed tomography for detecting protruding lesions in intraductal papillary mucinous neoplasm of the pancreas in comparison with single-detector computed tomography and endoscopic ultrasonography. *Pancreas* 2009; 38: 131-6.

Figure 1. Intracystic mucin ball before aspiration

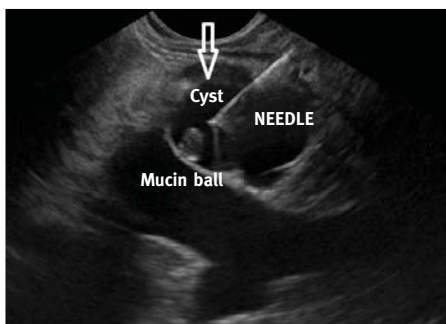


Figure 2. Mucin ball aspiration

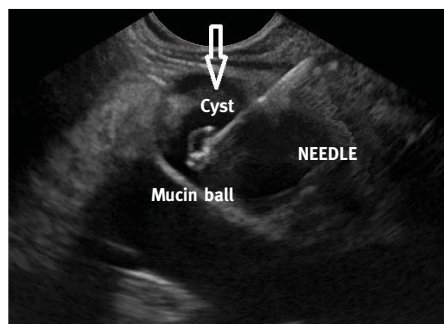


Figure 3. Cyst without mucin ball a year later

