

# A Case Report of Metastatic Primary Thyroid Leiomyosarcoma Treated with Pazopanib

Igal Kushnir MD, Viacheslav Soyfer MD and Ofer Merimsky MD

Department of Oncology, Tel Aviv Sourasky Medical Center, Tel Aviv, affiliated with Sackler Faculty of Medicine, Tel Aviv University, Tel Aviv, Israel

**KEY WORDS:** leiomyosarcoma, thyroid, pazopanib, chemotherapy, treatment

*IMAJ* 2018; 20: 125–126

Leiomyosarcoma is a highly malignant soft tissue sarcoma (STS) that originates in the smooth muscle portion of various organs. It frequently occurs in the uterus and gastrointestinal tract, rarely develops as primary bone sarcoma, and may actually arise from the smooth muscle in blood vessel walls situated in any organ. Primary leiomyosarcoma of the thyroid gland is an extremely rare entity, representing 0.014% of thyroid tumors [1]. Literature data are scarce, and no consensus on the best treatment approach is available. In this article we present a case of a 67 year old female with primary leiomyosarcoma of the thyroid, and discuss the oncological options of treatment.

## PATIENT DESCRIPTION

A 67 year old woman with a medical history of treated hypercholesterolemia and heavy smoking complained on hoarseness, dysphagia, and breathing difficulties in July 2012. An ultrasound scan performed that month demonstrated a hypoechoic space-occupying lesion measuring about 1.6 cm in diameter involving the right lobe the thyroid gland and an isoechoic nodule measuring about 2.5 cm in the left lobe of the thyroid gland. Thyroid function tests were in the normal range. Fine needle aspiration showed no malignancy, but because of high clinical suspicion the patient underwent total thyroidectomy

in August 2012. No other imaging studies were conducted prior to surgery. The histological study revealed that the right thyroid lobe was involved with a spindle cell tumor with extra-thyroidal extension. The left lobe was not involved and showed only hyperplastic changes. Ki-67 showed a proliferative rate of 35–40%.

Staining for cytokeratin, epithelial membrane antigen, thyroid transcription factor 1 (TTF1), S100, and calcitonin were negative; whereas, staining for vimentin, smooth muscle actin (SMA), and desmin were positive. The final diagnosis was high grade leiomyosarcoma of the thyroid.

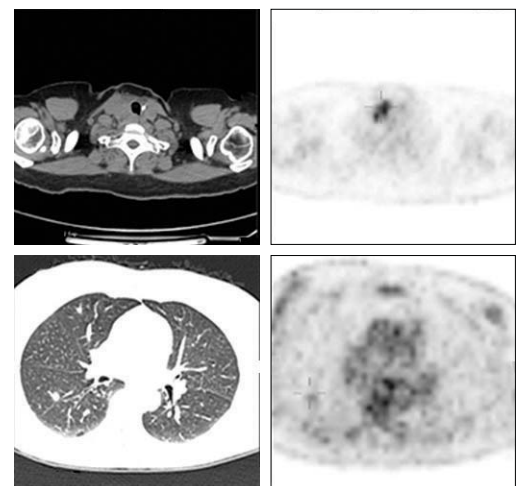
No postoperative treatment was offered. In September 2012 the patient arrived at the sarcoma unit for consultation. She complained about the same symptoms as during the initial presentation. A positron emission tomography/computed tomography (PET-CT) scan conducted in September 2012 showed a recurrent tumor in the surgical bed and metastatic spread to the lungs [Figure 1].

Because the patient was symptomatic, and the disease showed rapid recurrence, she began treatment with palliative chemotherapy based on Doxorubicin 37.5 mg/m<sup>2</sup> + Ifosfamide/mesna 3000 mg/m<sup>2</sup> on days 1 and 2 every 3 weeks. After four cycles, the symptoms resolved. Maximal response was reached and therefore the chemotherapy treatment was stopped.

In November 2013, after a progression-free interval of 13 months, the symptoms (hoarseness and pain) recurred. A CT scan demonstrated progression of the disease in the neck. In December 2013 the chemotherapy treatment was resumed with trabectedin 1.5 mg/m<sup>2</sup> every 3 weeks. Due to side effects (weakness and nausea), the dose was reduced to 1.2 mg/m<sup>2</sup> every 3 weeks. After five cycles, a CT scan revealed a progressive disease and the treatment was stopped.

In the beginning of July 2014, due to symptomatically progressive disease, treatment with pazopanib 800 mg once a day was initiated. Under pazopanib treatment,

**Figure 1.** A positron emission tomography/computed tomography scan demonstrating the tumor in the neck compressing vital structures and a lung metastasis



the patient reported improvement in symptoms. Repeated CT scans revealed stabilization of the disease until March 2016 when a CT scan demonstrated suspicious lesions in the liver, which were regarded as disease progression. Still, the disease was stabilized in the neck region and lungs and therefore it was recommended to continue treatment with pazopanib. In July 2016 the patient's condition deteriorated and she succumbed to the disease in August 2016.

### COMMENT

Thyroid leiomyosarcoma is an extremely rare neoplasm and only a few cases have been described in the literature [1-3]. The mean age at diagnosis is 61 and the tumors seem to be somewhat more frequent among women [3]. The patients usually present with symptoms related to local pressure of the tumor mass. As in our case, there is great difficulty in diagnosing thyroid sarcoma prior to surgery as fine needle aspiration may often be non-informative or non-reliable [1]. The histological diagnosis can be challenging. The main differential diagnosis is anaplastic carcinoma. Immunohistochemical staining is needed to differentiate between the two. Leiomyosarcoma stains positive to desmin, SMA, and vimentin but negative to cytokeratin, TTF1, thyroglobulin, and calcitonin. The negative staining to cytokeratin helps to rule out anaplastic carcinoma [2,3]. Most patients are diagnosed with an advanced disease and the prognosis is poor, with 1 year overall survival of less than 20% [1-3]. In contrast to soft tissue sarcoma arising in the limb, for example, while the principles of chemotherapy and radiation therapy may be

similar, the surgical option is rather limited due to the vicinity of important anatomical structures in the neck region. We decided to treat our patient with standard leiomyosarcoma treatment [4]. Our patient initially received chemotherapy, which included doxorubicin and ifosfamide, with good response that lasted for about 1 year. Even more remarkable is the benefit the patient experienced with long-term stabilization of her disease under treatment with pazopanib, which resulted in a progression-free interval of 20 months.

Pazopanib is an oral, multi-targeted, tyrosine kinase inhibitor of vascular endothelial growth factor receptor (VEGFR), platelet-derived growth factor receptor and several other key proteins responsible for angiogenesis, tumor growth and cell survival. [4]. Pazopanib is an effective treatment for non-adipocytic metastatic soft tissue sarcomas, including leiomyosarcomas, that have progressed after standard chemotherapy with median progression-free survival of 4.6 months and an overall survival of 12.5 months. Interestingly, the main benefit of pazopanib is stabilization of the disease (as in our case) with only 6% of patients in the PALETTE trial [4] achieving partial response and 67% achieving stable disease. Although pazopanib was used successfully in treating thyroid carcinoma, to the best of our knowledge, pazopanib has never been used before to treat patients with primary thyroid leiomyosarcomas [5].

Our experience implies that standard treatment for leiomyosarcoma is effective for primary thyroid leiomyosarcoma, including standard chemotherapy regimens and pazopanib. In addition, as our patient achieved an overall survival of 4 years, it seems that prognosis may not be as poor as

previously reported. Because of the rarity of this entity, no clinical trials addressing the question of the optimal treatment for primary thyroid leiomyosarcoma are expected. However, it is now reasonable to exploit the evolving data concerning leiomyosarcoma in general for the treatment of this rare subtype.

### CONCLUSIONS

In this case report we demonstrated that treating primary thyroid leiomyosarcoma like standard leiomyosarcoma, with a chemotherapy regimen that included doxorubicin and ifosfamide and later pazopanib, resulted in prolonged palliation and survival.

### Correspondence

**Dr. I. Kushnir**

Dept. of Oncology, Tel Aviv Sourasky Medical Center, Tel Aviv, 6423906 Israel

**Phone:** (972-3) 697-3469

**Fax:** (972-3) 697-3721

**email:** igalku@tlvmc.gov.il; ikushnir@toh.ca

### References

1. Conzo G, Candela G, Tartaglia E, et al. Leiomyosarcoma of the thyroid gland: a case report and literature review. *Oncol Lett* 2014; 7 (4): 1011-14.
2. Just PA, Guillemin R, Capron F, et al. An unusual clinical presentation of a rare tumor of the thyroid gland: report on one case of leiomyosarcoma and review of the literature. *Ann Diagn Pathol* 2008; 12 (1): 50-6.
3. Şahin Mİ, Vural A, Yüce İ, Çağlı S, Deniz K, Güney E. Thyroid leiomyosarcoma: presentation of two cases and review of the literature [Review]. *Braz J Otorhinolaryngol* 2016; 82 (6): 715-21.
4. Van der Graaf WT, Blay JY, Chawla SP, et al. Pazopanib for metastatic soft-tissue sarcoma (PALETTE): a randomised, double-blind, placebo-controlled phase 3 trial. *Lancet* 2012; 379 (9829): 1879-86.
5. Gruber JJ, Colevas AD. Differentiated thyroid cancer: focus on emerging treatments for radioactive iodine-refractory patients. *Oncologist* 2015; 20 (2): 113-26.

**“People who wonder whether the glass is half empty or half full miss the point. The glass is refillable”**

Simon Sinek, (born 1973), British/American author, motivational speaker and marketing consultant

**“The greatest obstacle to being heroic is the doubt whether one may not be going to prove one's self a fool; the truest heroism is to resist the doubt; and the profoundest wisdom, to know when it ought to be resisted, and when it be obeyed”**

Nathaniel Hawthorne, (1804–1864), American novelist, dark romantic, and short story writer