

# The Epidemiological, Clinical, and Histopathological Characteristics of Lacrimal Gland Biopsies in a Tertiary Care Center in Israel

Ayelet Priel MD, Vicktoria Vishnevskia-Dai MD, Liran Hochma MD, Juliana Gildener-Leapman MD, Guy J. Ben Simon MD, Mordechai Rosner MD, Gal Antman MD and Ofira Zloto MD

Goldschleger Eye Institute, Sheba Medical Center, Tel Hashomer, affiliated with Sackler Faculty of Medicine, Tel Aviv University, Tel Aviv, Israel

**ABSTRACT:** **Background:** The distribution of pathology and clinical characteristics of lacrimal gland diseases are different in different areas of the world.

**Objectives:** To evaluate the incidence rate, patient characteristics, and indications for surgical intervention of lacrimal gland lesions in a tertiary care center in Israel.

**Methods:** All biopsied or surgically removed lacrimal gland lesions at the Goldschleger Eye Institute from 2009 to 2015 were identified. The following data were collected: age, gender, indications for surgical intervention, diagnosis, treatment, and prognosis.

**Results:** We evaluated 28 lacrimal gland biopsies from 26 patients (11 men, 15 women). Mean age at biopsy was 47.5 years old. The most common presenting symptoms were: eyelid swollenness (57.14%), ptosis (32.14%), and proptosis (10.71%). All patients underwent computed tomography and magnetic resonance imaging. In 28 cases, infiltrations of the lacrimal gland were found. In nine cases infiltration of muscles or orbital extension were found. The most common pathologies were non-specified inflammation (44.82%), lymphoma (20.68%), and immunoglobulin G4-related disease (10.34%). The treatment was diverse according to the patient diagnosis. Prognosis of lacrimal gland disease was good; however, in five patients the systemic disease progressed.

**Conclusions:** Lesions of the lacrimal gland comprise a wide variety of pathological findings that require different treatment strategies. Lacrimal gland biopsies enable physicians to precisely recognize the pathology; therefore, it is important to consider this surgical method in any patient with lesions in the lacrimal gland.

*IMAJ* 2018; 20: 104–108

**KEY WORDS:** lacrimal gland, ptosis, proptosis, lymphoma, immunoglobulin G4-related disease (IgG4-RD)

of many acini and intralobular ducts that drain into excretory ducts or tubules. The ducts of both lobes drain into the superotemporal conjunctival fornix [1].

The human tear film coats the anterior surface of the eye and has a variety of constituents that are essential for the maintenance of the avascular transparent corneal epithelium. This film is composed of three distinct layers: an inner mucin coating, a middle aqueous component, and a lipid overlay [2].

Traditionally, it was thought that the lacrimal gland produces only the aqueous component; however, in the last decade it was found that the lacrimal gland also secretes antimicrobial agents and hormones that add to the mucin layer as well [3].

The lacrimal gland contains a variety of cells that are responsible for its different function. The gland contains secretory cells, myoepithelial cells, B and T lymphocytes, plasma cells, nerve cells, and fibroblasts [1].

Due to this cellular diversity, pathological lesions of the gland have several potential origins. The differential diagnosis of lacrimal gland lesions is wide and includes dacryops, inflammatory processes, benign tumors, malignant tumors, secondary invading tumors, and metastasis [Table 1].

A literature search using the term “lacrimal gland lesions” revealed some case series of unilateral lacrimal gland biopsies from different countries around the world [4-6]. The largest study we found is from Australia. The group examined the clinical and pathological findings of 268 biopsies over 15 years. They found that approximately two-thirds of all lacrimal gland biopsies were attributed to inflammation and lymphoid hyperplasia, and that the ratio of inflammation to neoplasia was significantly influenced by the clinician's threshold to perform a biopsy on a lesion presenting with features of dacryoadenitis [4]. The distribution of pathology and clinical characteristics were different from other studies around the world. To the best of our knowledge, the characteristics of lacrimal gland biopsies in Israel have never been examined.

The purpose of this study was to evaluate the incidence of unilateral lacrimal gland lesions and to review the patient characteristics and indications for surgical intervention in the setting of a tertiary care center in Israel.

The lacrimal gland is a bi-lobed eccrine secretory gland that is located superotemporally in the orbit within the lacrimal fossa of the frontal bone. The gland is divided into two lobes: the orbital and palpebral. Each lacrimal gland lobule consists

**Table 1.** Differential diagnosis of lacrimal gland lesions

<b>Dacryops</b>	
<b>Inflammation</b>	
Acute dacryoadenitis	Chronic dacryoadenitis
Necrotizing granulomatous inflammation	Non-necrotizing granulomatous inflammation
<b>Benign tumors</b>	
Benign epithelial tumors: pleomorphic adenoma	Benign lymphoid tumors: benign lymphoid hyperplasia
Granular cell tumor	Benign lymphoepithelial lesion
Neurofibroma	Benign vascular tumors: angiolymphoid hyperplasia with eosinophilia
<b>Malignant tumors</b>	
Malignant epithelial tumors: adenoid cystic carcinoma, carcinoma ex pleomorphic adenoma, adenocarcinoma, mucoepidermoid carcinoma, cuctal carcinoma, squamous cell carcinoma	Malignant lymphoid tumors: extra-nodal marginal zone lymphoma, diffuse large B-cell lymphoma, follicular lymphoma, mantle cell lymphoma, small lymphocytic lymphoma
<b>Secondary invading tumors</b>	
Adenoid cystic carcinoma	Squamous cell carcinoma
Meibomian carcinoma	
<b>Metastasis</b>	

**PATIENTS AND METHODS**

This retrospective analysis comprised a cohort of patients who had been diagnosed with a unilateral lacrimal gland lesion and who underwent a biopsy at the Goldschleger Eye Institute during the years 2009–2015.

The following parameters were documented: patient demographic information (gender and age at diagnosis), ocular and systemic history, symptoms and complaints leading to the biopsy, suspected diagnosis at presentation, clinical findings, radiographic findings on computed tomography (CT) and magnetic resonance imaging (MRI), histopathologic findings on biopsy with frozen sections, treatment, and ocular and systemic outcomes.

The study was approved by the institutional review board at the Sheba Medical Center.

**RESULTS**

**EPIDEMIOLOGICAL CHARACTERISTICS**

We performed 28 lacrimal gland biopsies on 26 patients with unilateral lacrimal gland lesions. The population included 11 men and 15 women, with the mean age of 47.34 ± 21.76 years (range 16–88) at the time of the biopsy.

In 14 cases the biopsy was taken from the right lacrimal gland, and in 14 cases the biopsy was taken from the left lacrimal gland.

**CLINICAL CHARACTERISTICS**

The most common complaint (26 patients) was eyelid swelling (96.15%). Four patients complained of visual field disturbances (14.28%), and two patients described pain (7.14%). None of the patients reported diplopia. Some patients had more than one complaint.

The most common presenting signs were eyelid swelling in 24 cases (85.74%), ptosis in 9 cases (32.14%), and proptosis in 3 cases (10.71%). Some patients had more than one presenting sign.

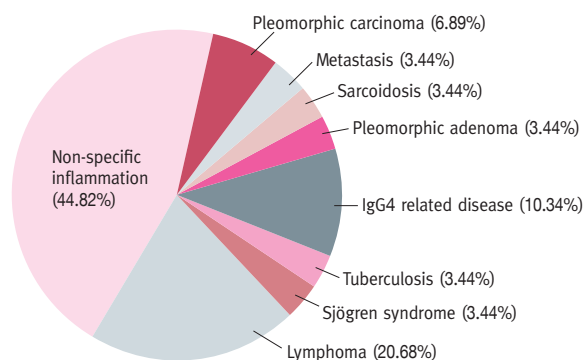
In 11 cases (39.28%) the suspected diagnosis was non-specific inflammation. In six cases (21.42%) pleomorphic adenoma was suspected, eight patients (28.57%) had lymphoma, one case (3.57%) revealed a cyst lined by ductal epithelium, and one case (3.57%) was of metastases.

**IMAGING CHARACTERISTICS**

All patients underwent imaging. Some patients underwent a CT scan at presentation or an MRI to improve radiologic evaluation of the soft tissues. In total, 21 patients underwent CT and 11 patients underwent MRI.

In 28 biopsies (100%), infiltration of the lacrimal gland was found, in 9 patients (32.14%) infiltration of muscles was observed, and in 9 patients (32.14%) orbital extension was observed beyond the superotemporal area [Figure 1A, 1B].

**Figure 1.** The distribution of histopathology



### HISTOPATHOLOGICAL CLASSIFICATION

The distribution of histopathology is illustrated in Figure 1.

Collectively, inflammation, infection, and vasculitis accounted for 65.48% of cases, and malignancy accounted for 31.01%. Non-specific dacryoadenitis was the most common histopathological diagnosis overall, accounting for 44.82% of lacrimal gland biopsies. The histopathologic findings of this group demonstrated variable amounts of fibrosis and a mixed chronic inflammatory cell infiltrate of typical lymphoid cells, plasma cells and occasional eosinophils.

Lymphoma was the second most common diagnosis (20.68%). B-cell lymphoma was the most frequent lymphoid malignancy.

The third most common histopathologic diagnosis was immunoglobulin G4-related disease (IgG4-RD). IgG4-related disease has been examined at Sheba Medical Center since 2013, and standard immunohistochemical staining for IgG4 has been performed since that time.

Comparison of the suspected diagnoses with the final histopathological results was summarized and analyzed. When a suspicion of non-specific inflammation was raised, the final histopathological diagnoses were non-specific inflammation and IgG4-related disease. However, when a suspicion of pleomorphic adenoma was raised, the final histopathological diagnoses included pleomorphic adenoma, tuberculosis, or lymphoma. When a suspicion of lymphoma was raised, the final histopathological diagnoses were lymphoma, sarcoidosis, and non-specific inflammation.

Older patients presented with malignant disease more than with inflammatory processes, while younger patients showed inflammation at a higher rate than malignant diseases. Men presented with more malignant diseases than women, and women showed more inflammatory diseases than men [Table 2].

### TREATMENT

The treatment methods were diverse and applied in accordance with patient diagnosis. The treatment methods were changed as needed according to the patient response.

**Table 2.** Mean age and gender per diagnosis

Diagnosis	Mean age (years)	Male (%)
Lymphoma	64	80
Non-specific inflammation	30.5	20
Sjögren syndrome	53	0
Tuberculosis	23	0
IgG4-related diseases	38.3	0
Pleomorphic adenoma	63.5	50
Sarcoidosis	43	100
Pleomorphic carcinoma	39	100
Metastasis	79	100

Nine patients (32.14%) were treated with oral prednisone. Six of them received adjuvant chemotherapy and methotrexate was added for three of them. One patient (3.57%) was treated for tuberculosis and one patient (3.57%) received the immunosuppressive drug imuran. Three patients (10.71%) received local treatment with triamcinolone injection to the area of the lacrimal gland in the lacrimal fossa.

### OUTCOME

The mean follow-up time was 13.6 months (3–24 months). At the end of the follow-up period, local disease in the lacrimal gland underwent complete resolution in eight patients (28.57%), showed significant improvement with mild residual disease in three patients (10.71%), remained stable in six patients (21.42%), and progressed in two patients (7.14%).

Regarding the systemic disease, four patients (14.28%) had progression of the disease, three patients (10.71%) showed significant improvement with only mild residual disease, three patients (10.71%) remained stable, and two patients (7.14%) underwent complete resolution of the disease. One patient (3.57%) with metastatic lacrimal gland disease died from the primary disease.

### DISCUSSION

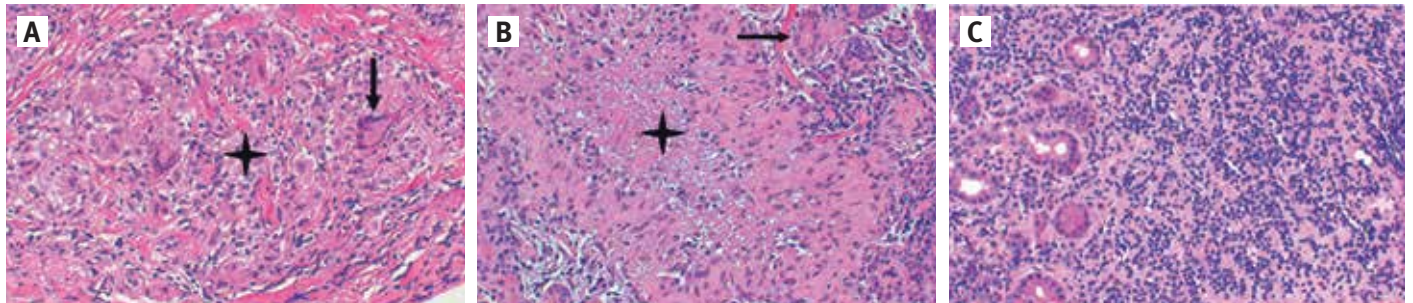
The purpose of this study was to find the incidence, clinical characteristics, and distribution of pathological etiologies in a sample of lacrimal gland biopsies performed in a tertiary care center in Israel. To do so, we retrospectively reviewed the database for all cases presenting with lacrimal gland lesions to our center during the period of January 2009 to December 2015.

Our study retrieved 28 lacrimal gland biopsies during a 6 year study period, equating to approximately 1.3 lacrimal biopsies per 1,000,000 people per year. This incidence is similar to the incidence of the Danish study [5] but two time less than the Australian study [4] with an incidence of approximately 2.6 lacrimal biopsies per 1,000,000 people per year. We think that the differences are attributable to the threshold for performing a biopsy in each institution. When a patient presented with a lacrimal gland mass the physician elicited a suspected diagnosis based on the clinical presentation, age, and imaging results. If the circumstances strongly pointed in favor of an inflammatory process (young age, pain, inflammation), the clinician may have decided to treat the patient with a trial of steroids without performing a biopsy.

After one treatment trial, if there is a relapse, a biopsy should be promptly performed. In Israel, the primary care ophthalmologist may start treatment based on a high level of suspicion. Therefore, not all patients arrive at the tertiary center; some begin steroid treatment.

Inflammatory lesions were the most common lacrimal gland lesions in this study. This result is in accordance to the report

**Figure 2.** Examples for histopathological findings **[A]** Sarcoidosis: Non-necrotizing granulomatous inflammation (asterisks) with giant cells (arrow), **[B]** Tuberculosis: Necrotizing granulomatous inflammation (asterisks) with giant cells (arrow), **[C]** Lymphoma: multiple lymphoid cells



by Shields and colleagues [7]. They reported on a cohort of 1264 patients referred over the course of 3 decades to an ocular oncology service. Of the 113 lacrimal gland lesions identified, the most common lesion of the lacrimal gland was dacryoadenitis, accounting for 33% of lesions overall. Their findings, as well as ours, are in contrast to the Japanese Lacrimal Gland Tumor Study Group, which found that only 16.1% of their lesions were inflammatory lesions [8]. We think that those differences can be attributed to the different threshold for performing a biopsy or to the epidemiological differences between the study groups. Those theories should be further examined in the future.

The most common malignant lesion, and one of the most common pathologies in this study, was lymphoma.

The population sample of this study was from a tertiary care center. Therefore, referral bias toward difficult cases is suspected.

IgG4-RD is a relatively new diagnosis described as a mass-forming, fibro-inflammatory condition. It is characterized histopathologically by storiform fibrosis and a lymphoplasmacytic infiltrate that is rich in IgG4-producing plasma cells [9]. Ophthalmic IgG4-RD is not rare, and may affect any anatomic structure in and around the globe. Several orbital lesions that were previously interpreted as idiopathic orbital inflammation have now been reclassified as IgG4-RD due to more specific histological features and particular stains [10].

At the Goldschleger Eye Center, IgG4-RD has only routinely been tested in blood samples and in histopathology since 2013. Therefore, we believe that this condition is under-diagnosed in this study (cases collected from 2009). In future studies, the prevalence of this diagnosis may increase.

As expected, malignant lesions were found in older patients while inflammatory lesions were found among younger patients. Moreover, we found that men have more malignant lesions while women have more inflammatory lesions. These findings are important because they may lead to practical treatment decisions. The threshold for performing biopsies in older men should be lower than the threshold for biopsy in younger women.

Treatment was also given according to the systemic disease when diagnosed.

The outcome of the lacrimal gland disease was good in most cases. However, the prognosis of the patient, when systemic disease present, was poor, even when the lacrimal gland disease had been resolved. This indicates that in some cases, although we may treat the local condition of the lacrimal gland, the systemic disease involving the gland continues to evolve.

**CONCLUSIONS**

Lacrimal gland lesions represent a wide spectrum of etiologies that require different treatment strategies. Patient characteristics, laboratory tests, and imaging studies are key features distinguishing between the etiologies. However, while there was a broad spectrum of suspected diagnoses, histopathological examinations confirmed the final answer. In addition, the surgical approach to the lacrimal gland for a biopsy sample is relatively simple, with a low rate of complication. Therefore, we think that the threshold for lacrimal gland biopsy performance should be low. The complications of this procedure are rare, while the success of the procedure can be high.

To the best of our knowledge, this study is the first from Israel that summarizes the incidence, clinical and pathological characteristics of lacrimal gland biopsies.

**Correspondence**

**Dr. A. Priel**  
 Goldschleger Eye Institute, Sheba Medical Center, Tel Hashomer 52621, Israel  
**Phone:** (972-3) 530-2874  
**Fax:** (972-5) 302-822  
**email:** priel.ayelet@gmail.com

**References**

1. Obata H. Anatomy and histopathology of the human lacrimal gland. *Cornea* 2006; 25: S82-9.
2. Walcott B. The lacrimal gland and its veil of tears. *News Physiol Sci* 1998; 13: 97-103.
3. Tsai PS, Evans JE, Green KM, et al. Proteomic analysis of human meibomian gland secretions. *Br J Ophthalmol* 2006; 90: 372-7.
4. Andrew NH, McNab AA, Selva D. Review of 268 lacrimal gland biopsies in an Australian cohort. *Clin Experiment Ophthalmol* 2015; 43: 5-11.

5. von Holstein SL, Therkildsen MH, Prause JU, et al. Lacrimal gland lesions in Denmark between 1974 and 2007. *Acta Ophthalmol* 2013; 91: 349-54.
6. Teo L, Seah LL, Choo CT, et al. A survey of the histopathology of lacrimal gland lesions in a tertiary referral centre. *Orbit* 2013; 32: 1-7.
7. Shields JA, Shields CL, Scartozzi R. Survey of 1264 patients with orbital tumors and simulating lesions: The 2002 Montgomery Lecture, part 1. *Ophthalmology* 2004; 111:997-1008.
8. Lacrimal Gland Tumor Study G. An epidemiological survey of lacrimal fossa lesions in Japan: number of patients and their sex ratio by pathological diagnosis. *Jpn J Ophthalmol* 2005; 49: 343-8.
9. Mulay K, Aggarwal E, Honavar SG. Clinicopathologic features of orbital immunoglobulin G4-related disease (IgG4-RD): a case series and literature review. *Graefes Arch Clin Exp Ophthalmol* 2015; 253: 803-9.
10. McNab AA, McKelvie P. IgG4-related ophthalmic disease. Part I: background and pathology. *Ophthalm Plast Reconstr Surg* 2015; 31: 83-8.

## Capsule

### Why aging attenuates antiviral responses

Older adults are more likely to die after influenza A viral infection than younger adults. This effect is in part because monocytes from older people produce less interferon and show reduced induction of antiviral genes in response to infection. **Molony** and co-authors found that monocytes from older human donors showed impaired signaling downstream

of the cytosolic RNA sensor RIG-I, which initiates the innate immune response to influenza A virus. Thus, restoring RIG-I signaling in older individuals may reduce age-related mortality from influenza A viral infection.

*Sci Signal* 2017; 10: eaan2392

Eitan Israeli

## Capsule

### Recycling antibiotic sensitivity

Cystic fibrosis (CF) is accompanied by chronic lung infections, requiring lifelong consumption of many antibiotics to maintain airway function. Antibiotic resistance and clinical deterioration are apparently inevitable. In a multifactorial study, **Imamovic** and co-authors discovered that mutations in *Pseudomonas aeruginosa* that endow resistance to some classes of antibiotic concomitantly result in sensitivity to others. For example, in any strain of *P. aeruginosa*, resistance to the fluoroquinolone ciprofloxacin was consistently associated

with sensitivity to aminoglycoside antibiotics, such as amikacin. In this case, resistance was mediated by mutations in the transcriptional regulator nfxB of the MexC transporter. Using biomarkers such as nfxB, it appears to be possible to design antibiotic regimens for individual CF sufferers that flip resistant bacteria between predictable drug-sensitive states.

*Cell* 2018; 172: 121

Eitan Israeli

## Capsule

### Internet cognitive-behavioral therapy for depression in older adults with knee osteoarthritis: a randomized controlled trial

**O'moore** and colleagues tried to determine the efficacy of an internet-based cognitive-behavioral therapy (iCBT) program for depression in older adults with osteoarthritis (OA) of the knee and co-morbid major depressive disorder (MDD). The authors conducted a randomized controlled trial in 69 adults (ages  $\geq$  50 years) meeting criteria for MDD and OA of the knee with 1-week post-intervention (week 11) and 3-month follow-up (week 24) as the end points. Patients were allocated to either a 10-week iCBT program for depression added to treatment as usual (TAU) or to a TAU control group. Intent-to-treat analyses indicated between-group superiority of iCBT over TAU on the primary outcomes (PHQ-9: Hedges  $g = 1.01$ , 95% confidence interval [95%CI] 0.47, 1.54; K-10: Hedges  $g = 0.75$ , 95%CI 0.23–1.28), at post-intervention and 3 months follow-up (PHQ-

9: Hedges  $g = 0.90$ , 95%CI 0.36–1.44; K-10: Hedges  $g = 0.94$ , 95%CI 0.41–1.48), and on secondary OA-specific measures (ASES: Hedges  $g = -0.81$ , 95%CI 0.29, -1.33; WOMAC: Hedges  $g = 0.56$ –0.65, 95%CI 0.04–1.18) at the 3 month follow-up. The majority of iCBT participants (84%) no longer met diagnostic criteria at the 3 month follow-up. The authors concluded that the results support the efficacy of an iCBT program (requiring no face-to-face contact) for depression in individuals with co-morbid depression and OA of the knee. Importantly, the benefits of the program extended beyond reduced depressive symptoms and distress to include increased self-efficacy and improved pain, stiffness, and physical function at follow-up.

*Arthritis Care & Res* 2018; 70: 61

Eitan Israeli