

A Rare Case of a Hydatid Cyst of the Neck in a Kazakh Boy

Ardak Suleimenova MD^{1,3}, Ruslan Utebaliyev MD^{1,3}, Damir Jenalayev MD^{1,3}, Ruslan Bilal, MD, PhD^{1,3}, Altyнай Isabekova, MD^{2,3} and Sandro Vento, MD^{3,4}

¹Pediatric Surgery and Transplantation Unit and ²Department of Radiation Diagnostics, National Research Center for Maternal and Child Health, Astana, Kazakhstan

³Nazarbayev University Medical Center, Astana, Kazakhstan

⁴Department of Medicine, Nazarbayev University, Astana, Kazakhstan

KEY WORDS: echinococcosis, hydatid cyst, neck cyst, Kazakhstan

IMAJ 2017; 19: 584–585

A 10 year old boy was admitted to the Pediatric Surgery and Transplantation Unit at the National Research Center for Maternity and Child Health, University Medical Center in Astana, Kazakhstan. He had a 4 month history of a mass in the anterior part of the neck that had progressively increased in size. An ultrasound of the neck conducted at another hospital had shown a large multi-chamber (polycystic) mass with heterogeneous content, which displaced the right lobe of the thyroid gland posteriorly and downward. Regional lymph nodes were not enlarged.

Physical examination revealed that the neck mass was elastic, moderately mobile,

and painless. Routine blood test results showed increased eosinophils (7.0%).

A new ultrasound of the neck confirmed the previous findings, and a contrast computerized tomography (CT) scan of the soft tissues showed a reduced density, capsulated multi-chamber liquid mass of irregular shape with a size of 7.1 × 4.7 × 3.4 cm, which dislocated the thyroid gland and the trachea [Figure 1].

A chest CT scan and an abdominal ultrasound revealed no cysts in the lungs or liver.

Complete resection of the neck cyst and surrounding tissues was performed. Opening of the cyst after resection showed it to be multilocular, to contain clear fluid, and to be surrounded by a white germinal membrane, confirming its hydatid nature. Histological examination of the cyst revealed a chitinous layer surrounding the lesion and confirmed the diagnosis of cystic echinococcosis due to *Echinococcus*

granulosus [Figure 2]. No cyst recurrence was observed at a 6 month follow-up.

Although the liver and the lungs are commonly regarded as the most frequent sites of hydatid cysts, other locations such as kidneys and the central nervous system are even more common in some countries [1]. Indeed, cysts can occur anywhere in the body after eggs have passed through the liver and the lungs. Soft tissues account for only 2–3% of cases [2] and head and neck hydatid cysts are very rare even in countries where echinococcosis is endemic, presenting as firm or soft, well limited, painless, slowly growing masses [3,4]. Blood cell count is usually within normal range, but eosinophilia (present in our case) is unusual [4]. Serologic tests, including enzyme-linked immunosorbent assays, are positive in less than 30% of cases [4]. The treatment is a complete surgical resection of the cyst. After surgery, albendazole may be administered to

Figure 1. Computerized tomography scan showing neck cyst (arrows)

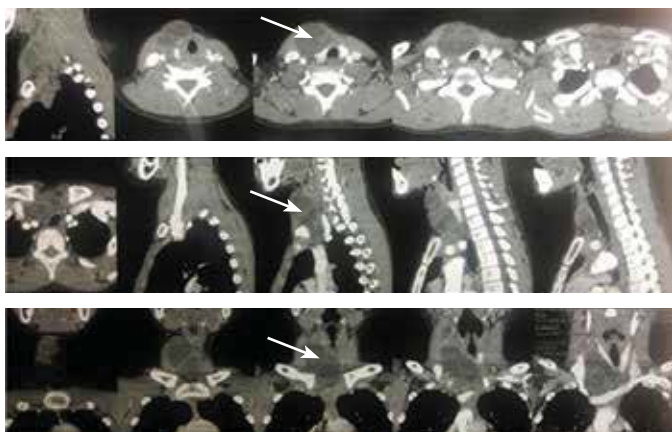
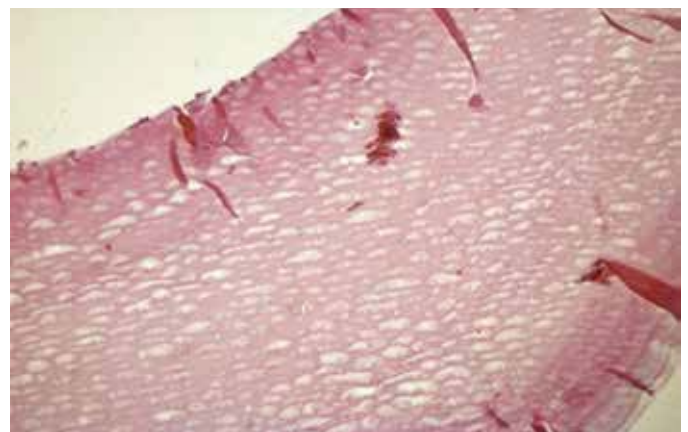


Figure 2. Laminated membranous structures lining the hydatid cyst wall



prevent recurrences, even though they are highly uncommon [4].

CONCLUSIONS

In conclusion, the differential diagnosis of silent growing masses in soft tissues should include subcutaneous hydatid cyst in endemic regions, such as Central Asia.

Correspondence

Dr. S. Vento
 Dept. of Medicine Nazarbayev University, Astana
 010000, Kazakhstan
Phone: (7 717) 269-4654
email: sandro.vento@nu.edu.kz

References

1. Bellil S, Limaïem F, Bellil K, et al. Descriptive epidemiology of extrapulmonary hydatid cysts: a re-

port of 265 Tunisian cases. *Tunis Med* 2009; 87: 123-6.

2. Safioleas M, Stamatakos M, Safioleas C, Kostakis A, Manti C. Management of soft-tissue echinococcosis. *Surgery* 2006; 139: 855.
 3. Belcadhi M, Kermani W, Mani R, et al. Cervicofacial hydatidosis. Report of 17 cases. *Tunis Med* 2011; 89: 336-41.
 4. Vecchio R, Marchese S, Ferla F, Spataro L, Intagliata E. Solitary subcutaneous hydatid cyst: review of the literature and report of a new case in the deltoid region. *Parasitol Int* 2013; 62: 487-93.

Capsule

Cancer immunotherapy according to GARP

Cancer, like microbes, can adapt to become resistant to a single therapy, making combination therapies the approach of choice. Complementary therapies that decrease immunosuppression may boost the efficacy of immunotherapies. Rachidi and colleagues found that targeting platelets improved adoptive T cell therapy of multiple cancers in mice. Transforming growth factor β (TGF β) from platelets decreased

T cell function, largely through the expression of the TGF β docking receptor, GARP (glycoprotein A repetitions predominant). Thus, combining immunotherapy with platelet inhibitors may improve cancer therapy.

Sci Immunol 2017; 2: eaai7911
 Eitan Israeli

Capsule

The NET effect of viral-triggered asthma

Infection with rhinovirus is a common cause of allergic asthma. Toussaint and co-authors studied how the virus triggers inflammation and stimulates an asthmatic attack. Rhinovirus infection causes the release of host double-stranded DNA and the formation of neutrophil extracellular traps (NETs). NETs are structures that capture microorganisms and activate immune cells and inflammatory responses. The

authors showed that rhinovirus-driven NETs promote the infiltration of inflammatory cells to the airways, causing the clinical features of an allergic response. Treatment with a compound blocking NET formation stopped the asthma from becoming worse.

Nat Med 2017; 10.1038/nm.4332
 Eitan Israeli

Capsule

Personalized physical therapy versus usual care for patients with systemic sclerosis: a randomized controlled trial

To compare a physical therapy program to usual care of systemic sclerosis (SSc) patients on disability, a 12-month follow-up, parallel-group randomized controlled trial involving a modified Zelen design was conducted in four tertiary-care hospitals. Patients were enrolled if they had a disability rating ≥ 0.5 on the Health Assessment Questionnaire disability index (HAQ DI) or symptoms of decreased mouth opening or limited range of motion of at least one joint. The experimental intervention (n = 112, of which 110 were analyzed) was a 1-month personalized supervised physical therapy program provided by trained care providers followed by home sessions. The control parameter (n = 108, all 108 were analyzed) was usual care that could include ambulatory physical therapy. The primary outcome was the HAQ DI score. Rannou et al. found

statistically significant differences in disability at 12 months. HAQ DI score between-group difference was -0.01, 95% confidence interval (95%CI) -0.15-0.13, P = 0.86. Disability was reduced at 1 month for patients in the physical therapy group (HAQ DI between-group difference -0.14, 95%CI -0.24-0.03, P = 0.01, at 6 months the HAQ DI score between-group difference was -0.12, 95%CI -0.23-0.01, P = 0.054). There was a statistically significant difference for hand mobility and function, and for pain, at 1 month. Microstomia was lower in the physical therapy group at 1, 6, and 12 months (between-group difference at 12 months 1.62, 95%CI 0.32-2.93, P = 0.01). No differences in adverse effects were observed.

Arthritis Care & Res 2017; 69: 1050
 Eitan Israeli