

Prospective Comparison between Remnant-Preserving Augmentation and Double-Bundle Reconstruction in Anterior Cruciate Ligament Tears

Noam Shohat MD*, Dror Lindner MD*, Eran Tamir MD, Yiftah Beer MD and Gabriel Agar MD

Department of Orthopedic Surgery, Assaf Harofeh Medical Center, Zerifin, Israel

ABSTRACT: **Background:** The debate continues regarding the best way to manage partial anterior cruciate ligament (ACL) tears. **Objectives:** To prospectively compare the clinical outcomes of remnant-preserving augmentation (RPA) and double-bundle reconstruction (DBR) in patients with ACL tears. **Methods:** In this prospective study, we included 13 cases of RPA and 30 cases of DBR with a follow-up period of 6 months, 12 months and 24 months. We clinically compared the preoperative and postoperative range of motion, Knee Society Score (KSS), Visual Analog Scale (VAS), Lysholm score, Tegner activity score, Short Form Health Survey (SF-36), thigh and calf circumference and anterior translation (using the KT-1000 knee arthrometer). **Results:** There were no significant differences in Lysholm score, Tegner score, VAS or KSS within the two groups at any time. The KT-1000 arthrometer results were higher in the RPA group at 6 months than in the DBR group; however, they did not reach statistical significance. **Conclusions:** We found no significant differences between the two specific groups leading us to believe that RPA may play a role in reconstruction when only a single bundle is injured.

IMAJ 2017; 19: 355–359

KEY WORDS: anterior cruciate ligament (ACL), reconstruction, remnant-preserving augmentation (RPA), double-bundle reconstruction (DBR), augmentation

Anterior cruciate ligament (ACL) reconstruction is a common procedure, with good to excellent results reported over the years [1]. The goal of the procedure is to replicate the normal knee anatomy, yet traditional single-bundle ACL reconstruction cannot restore normal knee kinematics [2]. Subsequently, anatomic double-bundle reconstruction (DBR) has become popular, in which the anteromedial and posterolateral bundles are created at their anatomic footprints [3] with good outcomes reported [4,5].

*The first and second authors contributed equally to this study

A partial tear of the ACL is a frequent injury, representing 10% to 35% of ACL tears, although symptomatic tears are reported in only 5 to 10% [6]. Anatomic and biomechanical studies [7,8] enabled us to consider a selected remnant-preserving augmentation (RPA) as a choice of treatment for partial ACL tears. RPA has shown excellent outcomes [9,10], which are thought to be attributed to the retained mechanoreceptor and vascularity of the remnant bundle. Recently, Mifune et al. [11] showed on an animal model that RPA can accelerate the healing process of the grafted tendon, which promotes better biomechanical recovery of the tendon.

The controversy continues regarding the best way to deal with partial ACL tears. Most of the earlier studies focused on the clinical outcomes of patients undergoing RPA compared to single bundle ACL reconstruction. Two recent systematic reviews [12,13] showed significant postoperative improvements in patients undergoing RPA. Two of the studies included in these reviews found significantly better results regarding knee stability in the RPA group [14]. Nevertheless, there is minimal data comparing RPA and DBR. Two studies comparing the two techniques showed similar clinical outcomes at a 2 year follow-up, neither of them compared the outcomes at different time periods [15,16].

The purpose of this study was to prospectively compare the clinical results of RPA and DBR in patients with ACL tears at a minimum of 2 years follow-up. We suggested that RPA would show comparable if not preferable results in the early stages of follow-up based on the potential better healing process of the grafted tendon and earlier recovery.

PATIENTS AND METHODS

PATIENT SELECTION

Between 2009 and 2012 in our institution we conducted a randomized control trial comparing ACL reconstruction using single-bundle vs. double-bundle reconstruction. All patients who underwent ACL reconstruction were symptomatic and had a visible tear on magnetic resonance imaging (MRI) scans. Exclusion criteria were multiple ligamentous injuries, revision surgery, or previous surgery around the affected knee. Every

arthroscopy started with a systematic examination of the knee and ACL integrity. In total, 76 patients enrolled in our study. Patients were randomly assigned intra-operatively to the single-bundle reconstruction group or to the DBR group. In total, 13 patients (17.1%) were diagnosed intra-operatively with a partial ACL tear of either the anteromedial or posterolateral bundle with an attached remnant bundle between the femur and tibia, which was not attenuated or functionally disrupted. In all 13 patients the ACL was thicker than 50% of that of the anteromedial or posterolateral bundle, and was less than 5 mm lax when haggarded with a probe. In these cases, an RPA was indicated, as proposed by Yoon and colleagues [17]. For complete tears, a single or double bundle reconstruction was performed as randomized.

PATIENT DEMOGRAPHICS

In total, 33 patients underwent a single-bundle reconstruction, 30 patients underwent DBR and 13 patients underwent RPA [Figure 1]. The DBR group comprised 28 males and 2 females, mean age 24 years (range 18–39 years). The RPA group included nine cases of anteromedial bundle augmentation. The group included and four cases of posterolateral bundle augmentation and consisted of 11 males and 2 females with a mean age = 23.5 years (range 19–36 years). The mean time period between the injury and surgery was 17.9 months (range 1.9–104 months) in the DBR group and 9.6 months (range 2.4–36.2 months) in the RPA group.

SURGICAL TECHNIQUE

Surgical procedures were performed by the two senior authors, and both were present during each surgery. Patients were positioned supine on the operating table and a tourniquet was placed as proximal to the knee as possible. Standard

anterolateral portal close to the patellar tendon and low anteromedial portal were created for arthroscopy. A diagnostic arthroscopy was performed and the morphology of the ACL was examined by probing at different knee flexion angles and the figure-of-four position. In all cases an autologous hamstring tendon was used (semitendinosus and gracilis), and it was harvested on the ipsilateral side of the knee joint by an oblique 4 cm incision over the pes anserinus. After the removal of the muscular tissue of the harvested hamstring tendon, a tubular form was made with a No. 2 ETHIBOND™ suture (Ethicon, Somerville, NJ, USA).

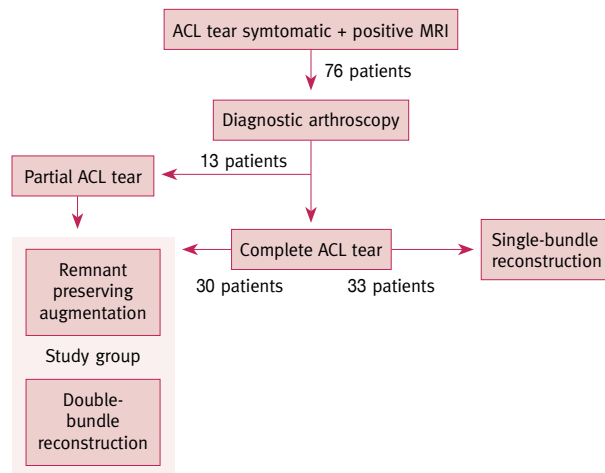
REMNAINT PRESERVING AUGMENTATION

The augmentation was performed in a similar fashion to a single bundle ACL reconstruction, using a 4-strand semitendinosus and gracilis tendon with an average diameter of 6.8 mm. The torn bundle was identified and debrided while preserving the intact bundle. For anteromedial bundle reconstruction, the guide pin of the femoral tunnel was pointed at the center of the anteromedial bundle footprint (11:00 direction for a right knee joint, 1:00 direction for a left knee), and the tibial tunnel was located at the center of the remnant footprint. For posterolateral bundle reconstruction, the guide pin was pointed at the center of the posterolateral bundle footprint on the femur (10:00 direction for a right knee, 2:00 direction for a left knee joint), and the tibial tunnel was located at the center of the remnant footprint. Graft tendon was fixed on the femoral side with a 15 mm loop Endobutton™ (Smith & Nephew, UK). The fixation on the tibial side was made after the application of a sufficient pretensioning cyclic loads and was fixed with bioabsorbable interference screws suitable for the diameter of the tunnel, and a metal staple.

DOUBLE-BUNDLE RECONSTRUCTION

For a DBR, a 4-strand semitendinosus graft with an average diameter of 6.55 mm was used for the anteromedial bundle. A 4-strand gracilis tendon with an average diameter of 5.7 mm was used for the posterolateral bundle. For anteromedial bundle reconstruction, the guide pin was pointed to the anterior and medial area of the ACL insertion site on the femur (11:00 direction for a right knee joint, 1:00 direction for a left knee). The posterolateral tunnel was pointed laterally and posterior to the anteromedial femoral tunnel (10:00 direction for a right knee, 2:00 direction for a left knee joint). A 2 mm bony bridge was preserved between the two bone tunnels. The tibial tunnel for the anteromedial bundle was positioned at the anterior portion of the natural ACL insertion. The posterolateral bundle was positioned 7 mm posterior and lateral to the anteromedial guide wire in the natural ACL insertion site. The posterolateral bundle was first introduced through the joint to the femoral drilled hole and fixed on the femoral side with a 15 mm loop Endobutton. The anteromedial bundle was then introduced and fixed in the same manner. The posterolateral bundle was fixed at full exten-

Figure 1. Study group



ACL = anterior cruciate ligament, MRI = magnetic resonance imaging

sion, followed by the anteromedial bundle at 30° knee flexion. Both were fixed on the tibial side after a sufficient pretensioning cyclic load in the same manner as described for RPA.

POSTOPERATIVE REHABILITATION

Both groups followed the same protocol. Weight bearing (with crutches) was allowed as tolerated immediately post-operative. Physiotherapy aimed for early restoration of full extension and quadricep function, and patients were put on a continuous passive motion machine (CPM). Low-grade exercise was allowed after 3 months, and return to full activity after 6 months. For patients who underwent a meniscal suture in addition to ACL reconstruction, weight bearing was not allowed for 6 weeks.

CLINICAL EVALUATION AND FOLLOW-UP

A thorough clinical examination and a functional assessment were performed preoperatively and at 6 months, 12 months and 24 months postoperative. Four patients from the DBR group and two from the RPA group were absent at the 24 month follow-up, representing a 13% and 17% loss of follow-up, respectively. Subjective evaluation consisted of the Knee Society Score (KSS), Visual Analog Scale (VAS), Lysholm score, Tegner activity score and Short Form Health Survey (SF-36). Objective evaluation included range of motion (knee flexion and extension), triple hop test, thigh and calf circumference and anterior translation. Thigh and calf circumference were measured 10 cm proximal and 5 cm distal to the patella, respectively. The KT-1000 knee arthrometer was used to measure anterior tibial motion relative to the femur. Evaluation was performed by a blinded evaluator who was not aware of the surgical procedure. The study was performed with internal review board approval and all patients gave informed consent to participate in the study.

STATISTICAL ANALYSIS

All statistical data were expressed as mean ± standard deviation. The IBM SPSS Statistics version 20 software (IBM Corp, Armonk, New York, USA) was used to perform all the statistical analyses in this study. We considered a difference of above 3 mm in the KT-1000 knee arthrometer between the healthy and injured leg to be positive for anterior instability [18]. For continuous variables, comparison between the group of patients who underwent DBR and the group that had RPA was done with Wilcoxon signed-rank test because the measurements were not normally distributed. Comparisons between dichotomy variables was done using the Mann–Whitney test. A P value < 0.05 was considered significant.

RESULTS

Both groups experienced a marked improvement in subjective and objective scores after surgery. The Lysholm score was

not significantly different in the two groups at any time, with a maximal improvement seen during the first 6 months post-surgery. On consecutive exams the score did not improve much [Table 1]. There was a trend toward better KSS scores in the RPA group at 24 months post-surgery, but this did not reach significance. The VAS, Tegner activity and SF-36 scores did not show significant differences with the groups in any time.

The data regarding the side-to-side differences in anterior tibial translation as measured by the KT-1000 arthrometer are presented in Table 1. There was no significant difference in anterior instability (KT-1000 difference above 3 mm) with the groups in any time. However, there was a tendency toward less translation in the DBR group compared to the RPA group at 6 months post-surgery [Figure 2]. There were no differences in range of motion, calf and thigh circumference, and the triple hop test between the groups at the 6-, 12- and 24-month visits.

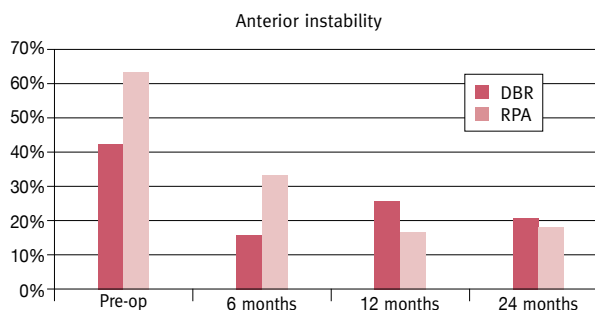
Table 1. Lysholm, KSS and KT-1000 knee arthrometer (mm) results at different times:

	RPA Group	DBR Group	PValue
Lysholm			
Preoperative	78.18 ± 13.02	65.82 ± 22.06	0.11
6 Month	86.75 ± 11.32	84.65 ± 13.73	0.57
12 Month	84.50 ± 18.38	88.18 ± 13.17	0.68
24 Month	88.82 ± 13.15	86.50 ± 15.44	0.75
KSS			
Preoperative	71.09 ± 21.57	72.04 ± 18.04	0.94
6 Month	81.08 ± 11.81	82.68 ± 13.07	0.29
12 Month	78.17 ± 15.44	81.43 ± 14.21	0.57
24 Month	84.82 ± 11.46	78.58 ± 16.23	0.17
*KT-1000			
Preoperative	4.08 ± 1.93	4.94 ± 4.22	0.54
6 Month	2.67 ± 2.18	0.84 ± 2.93	0.06
12 Month	1.29 ± 1.91	1.07 ± 3.16	0.69
24 Month	0.86 ± 3.75	1.25 ± 2.63	0.13

RPA = remnant-preserving augmentation, DBR = double-bundle reconstruction, KSS = Knee Society Score

*KT-1000 knee arthrometer (mm) results between the healthy and operated leg

Figure 2. The percentage of patients with a difference of more than 3 mm in the KT-1000 arthrometer between the healthy and operated leg, representing anterior instability. There were no significant differences in anterior stability between the two groups at any time



RPA = remnant-preserving augmentation, DBR = double-bundle reconstruction

In both groups there were no additional ligamentous injuries. Meniscal and chondral injuries, and the treatment for these injuries, are summarized in Table 2.

DISCUSSION

The most important findings of this study are:

- Postoperative improvement in patients undergoing RPA for partial ACL tears at 6, 12 and 24 months
- Comparable subjective clinical outcomes between the RPA and DBR groups
- No significant difference in knee stability as measured by KT-1000 arthrometer with the two groups after 6, 12 and 24 months

Earlier studies suggested that the advantages seen by conserving the ACL remnant are due to an increase in mechanical strength in the early postoperative period due to the preserved ACL, which may allow faster rehabilitation. In addition, preserved nerve fibers in the ACL bundle may reproduce mechanoreceptors about the augmented graft thus improving postoperative proprioceptive and knee kinematics [19]. Finally, the preserved ACL bundle may contribute to fast vascularization of the augmented graft, hastening return of ACL function [20]. A recent study, on a sheep model concluded that preservation of the ACL remnant tissue in ACL reconstruction enhances cell proliferation, revascularization, and regeneration of proprioceptive organs in the reconstructed ACL and reduces anterior translation [21]. Disadvantages in remnant preservation are the technical skills required by the physician and the increased risk of malposition due to poor visualization [22].

The results of this study show an advantage for selected ACL augmentation compared to DBR in the early stages of follow-up based on the potential better healing process of the grafted tendon and earlier recovery. According to our study, at early follow-up (6 months) there was no significant difference between the two groups. Moreover, the RPA group showed a tendency to greater instability. At later follow-up (24 months) the RPA group showed no significant improvement in stability

compared to the DBR group. There were no significant differences in the subjective clinical outcomes at any time between the two groups.

Mifune et al. [11] demonstrated on a rat model that selective ACL augmentation promotes an increase in cellularity and angiogenesis compared to conventional reconstruction and a higher failure to load at 8 weeks. They concluded that remnant preserving promotes early tendon graft healing, which appears to result in further mechanical strength of the bone-tendon bone complex. In our study we were unable to demonstrate an early advantage for remnant preserving at 6 months postoperative. Our results support an advantage for DBR at 6 months postoperative. The dissonance can be explained by the following:

- Most of the earlier studies are based on animal models. Rats have a greater healing potential than humans, so the tendon graft healing probably progresses at a faster rate than would be seen in humans.
- Previous studies compared remnant preserving to single-bundle reconstruction, while we compared it to DBR. The DBR may be responsible for the early stability seen in our results.
- Our earliest examination was 6 month postoperative while in other studies the examination was done much earlier (8 weeks postoperative). There might be an advantage for ACL augmentation in the earlier stages postoperative that reaches an equilibrium before 6 month.

Previous studies have shown good outcomes after a RPA [23,24]. Most of the research in this field assessed RPA compared to classical single bundle ACL reconstruction and found no significant difference in clinical outcome with the groups [12,13]. Park and co-authors [16] compared RPA and DBR at 24 months and showed equal results in clinical scores and stability tests, except for the anterior drawer, which was significantly better in the augmentation group. Lee et al. [15] presented similar subjective results in a smaller group of patients and assessed the anterior drawer test using a telos device; but were unable to show greater stability in the RPA group. Matsushita and colleagues [25] compared the results of 16 patients who had undergone RPA to 37 patients who underwent DBR and showed similar clinical and biomechanical outcomes. A second-look arthroscopy 1 year after surgery showed no difference between groups. We examined clinical scores and joint stability at 6 months 12 months and 24 months postoperative. At 24 months we showed comparable results to earlier studies with improved clinical results and stability compared to preoperative scores and no significant difference between the two group at any time.

LIMITATIONS

This study has several limitations. The study group was small and several patients were absent at each time period.

Table 2. Additional injuries and their treatment

	RPA Group	DBR Group
Lateral meniscal tear	3 (23.1%)	12 (41.4%)
Meniscectomy	3 (23.1%)	8 (27.6%)
Repair	0	4 (13.8%)
Medial meniscal tear	4 (30.76%)	16 (55.2%)
Meniscectomy	1 (7.7%)	8 (27.6%)
Repair	3 (23.1%)	8 (27.6%)
Chondral defect	1 (7.7%)	3 (10.3%)

RPA = remnant-preserving augmentation, DBR = double-bundle reconstruction

Nevertheless, the prospective nature of the study gives it strength, and our study group is comparable to earlier studies examining RPA outcomes. Surgery was performed by two different surgeons, which may account for differences in surgical outcomes and in scoring on objective exams. However, both surgeons are highly experienced knee arthroscopic surgeons who followed a strict protocol and in most cases both were present during surgery.

CONCLUSIONS

As far as we know, we are the first group to compare RPA and DBR on consecutive exams. Prior works comparing the two methods focused on differences at 2 years, whereas we also included results at 6 months and 12 months postoperative. We found no significant differences between the two specific groups studied leading us to believe that RPA may play a role in reconstruction when only a single bundle is injured. Further studies are required on a larger group of patients to examine the differences in stability with these two groups at early stages of ACL reconstruction.

Correspondence

Dr. N. Shohat

Dept. of Orthopedic Surgery, Assaf Harofeh Medical Center, Zerifin 70300, Israel

Fax: (972-3) 921-8888

email: noam.shohat@gmail.com

References

1. Kruse LM, Gray B, Wright RW. Rehabilitation after anterior cruciate ligament reconstruction: a systematic review. *J Bone Joint Surg Am* 2012; 94 (19): 1737-48.
2. Ristanis S, Stergiou N, Patras K, Vasiliadis HS, Giakas G, Georgoulis AD. Excessive tibial rotation during high-demand activities is not restored by anterior cruciate ligament reconstruction. *Arthroscopy* 2005; 21 (11): 1323-9.
3. Forsythe B, Kopf S, Wong AK, et al. The location of femoral and tibial tunnels in anatomic double-bundle anterior cruciate ligament reconstruction analyzed by three-dimensional computed tomography models. *J Bone Joint Surg Am* 2010; 92 (6): 1418-26.
4. Aglietti P, Giron F, Losco M, Cuomo P, Ciardullo A, Mondanelli N. Comparison between single- and double-bundle anterior cruciate ligament reconstruction: a prospective, randomized, single-blinded clinical trial. *Am J Sports Med* 2010; 38 (1): 25-34.
5. Suomalainen P, Moisala AS, Paakkala A, Kannus P, Jarvela T. Double-bundle versus single-bundle anterior cruciate ligament reconstruction: randomized clinical and magnetic resonance imaging study with 2-year follow-up. *Am J Sports Med* 2011; 39 (8): 1615-22.
6. Ohsawa T, Kimura M, Kobayashi Y, Hagiwara K, Yorifuji H, Takagishi K. Arthroscopic evaluation of preserved ligament remnant after selective anteromedial or posterolateral bundle anterior cruciate ligament reconstruction. *Arthroscopy* 2012; 28 (6): 807-17.

7. Duthon VB, Barea C, Abrassart S, Fasel JH, Fritschy D, Menetrey J. Anatomy of the anterior cruciate ligament. *Knee Surg Sports Traumatol Arthrosc* 2006; 14 (3): 204-13.
8. Ferretti M, Levicoff EA, Macpherson TA, Moreland MS, Cohen M, Fu FH. The fetal anterior cruciate ligament: an anatomic and histologic study. *Arthroscopy* 2007; 23 (3): 278-83.
9. Buda R, Di Caprio F, Giuriati L, Luciani D, Busacca M, Giannini S. Partial ACL tears augmented with distally inserted hamstring tendons and over-the-top fixation: an MRI evaluation. *Knee* 2008; 15 (2): 111-6.
10. Sonnery-Cottet B, Lavoie F, Ogassawara R, Scussiato RG, Kidder JF, Chambat P. Selective anteromedial bundle reconstruction in partial ACL tears: a series of 36 patients with mean 24 months follow-up. *Knee Surg Sports Traumatol Arthrosc* 2010; 18 (1): 47-51.
11. Mifune Y, Ota S, Takayama K, et al. Therapeutic advantage in selective ligament augmentation for partial tears of the anterior cruciate ligament: results in an animal model. *Am J Sports Med* 2013; 41 (2): 365-73.
12. Song GY, Zhang H, Zhang J, et al. The anterior cruciate ligament remnant: to leave it or not? *Arthroscopy* 2013; 29 (7): 1253-62.
13. Hu J, Qu J, Xu D, Zhang T, Zhou J, Lu H. Clinical outcomes of remnant preserving augmentation in anterior cruciate ligament reconstruction: a systematic review. *Knee Surg Sports Traumatol Arthrosc* 2014; 22 (9): 1976-85.
14. Adachi N, Ochi M, Uchio Y, Sumen Y. Anterior cruciate ligament augmentation under arthroscopy. A minimum 2-year follow-up in 40 patients. *Arch Orthop Trauma Surg* 2000; 120 (3-4): 128-33.
15. Lee YS, Nam SW, Sim JA, Lee BK. Comparison of anatomic ACL reconstruction between selective bundle reconstruction and double-bundle reconstruction. *Knee Surg Sports Traumatol Arthrosc* 2014; 22 (11): 2803-10.
16. Park SJ, Jung YB, Jung HJ, et al. Outcome of arthroscopic single-bundle versus double-bundle reconstruction of the anterior cruciate ligament: a preliminary 2-year prospective study. *Arthroscopy* 2010; 26 (5): 630-6.
17. Yoon KH, Bae DK, Cho SM, Park SY, Lee JH. Standard anterior cruciate ligament reconstruction versus isolated single-bundle augmentation with hamstring autograft. *Arthroscopy* 2009; 25 (11): 1265-74.
18. Arneja S, Leith J. Review article: Validity of the KT-1000 knee ligament arthrometer. *J Orthop Surg (Hong Kong)* 2009; 17 (1): 77-9.
19. Ochi M, Adachi N, Deie M, Kanaya A. Anterior cruciate ligament augmentation procedure with a 1-incision technique: anteromedial bundle or posterolateral bundle reconstruction. *Arthroscopy* 2006; 22 (4): 463 e461-5.
20. Bray RC, Leonard CA, Salo PT. Vascular physiology and long-term healing of partial ligament tears. *J Orthop Res* 2002; 20 (5): 984-9.
21. Takahashi T, Kondo E, Yasuda K, et al. Effects of remnant tissue preservation on the tendon graft in anterior cruciate ligament reconstruction: a biomechanical and histological study. *Am J Sports Med* 2016; 44 (7): 1708-16.
22. Ahn JH, Wang JH, Lee YS, Kim JG, Kang JH, Koh KH. Anterior cruciate ligament reconstruction using remnant preservation and a femoral tensioning technique: clinical and magnetic resonance imaging results. *Arthroscopy* 2011; 27 (8): 1079-89.
23. Tie K, Chen L, Hu D, Wang H. The difference in clinical outcome of single-bundle anterior cruciate ligament reconstructions with and without remnant preservation: A meta-analysis. *Knee* 2016; 23 (4): 566-74.
24. Sabat D, Kumar V. Partial tears of anterior cruciate ligament: results of single bundle augmentation. *Indian J Orthop* 2015; 49 (2): 129-35.
25. Matsushita T, Kuroda R, Nishizawa Y, et al. Clinical outcomes and biomechanical analysis of posterolateral bundle augmentation in patients with partial anterior cruciate ligament tears. *Knee Surg Sports Traumatol Arthrosc* 2015; 1-11.

“Most creativity is a transition from one context into another where things are more surprising. There’s an element of surprise, and especially in science, there is often laughter that goes along with the ‘Aha’. Art also has this element. Our job is to remind us that there are more contexts than the one that we’re in –the one that we think is reality”

Alan Kay (b. 1940) , computer scientist. He is best known for his pioneering work on object-oriented programming and windowing graphical user interface design.