

Transcatheter Tricuspid Valve-In-Valve Implantation in Patients with Tricuspid Bioprosthetic Valve Degeneration at High Surgical Risk: A Multicenter Case Series

Uri Landes MD¹, Arthur Kerner MD⁴, Amit Segev MD², Haim Danenberg MD⁵, Yaron Shapira MD¹, Ariel Finkelstein MD³ and Ran Kornowski MD FESC FACC¹

¹Department of Cardiology, Rabin Medical Center (Beilinson Campus), Petah Tikva, Israel

²Leviv Heart Center, Sheba Medical Center, Tel Hashomer, Israel

³Department of Cardiology, Tel Aviv Sourasky Medical Center, Tel Aviv, Israel

⁴Department of Cardiology, Rambam Health Care Campus, Haifa, Israel

⁵Department of Cardiology, Hadassah-Hebrew University Medical School, Jerusalem, Israel

ABSTRACT: **Background:** Transcatheter tricuspid valve-in-valve implantation (TVIV) is an attractive yet under-explored alternative to redo valve surgery.

Objectives: To report the multicenter TVIV experience in Israel.

Methods: We approached multiple centers and collected data regarding seven TVIV cases.

Results: The study group comprised seven participants: five females and two males, with a mean age of 63 ± 12 years and EuroSCORE-II $13.6 \pm 3.3\%$. Follow-up ranged from 3 to 21 months (mean 8 ± 6 months). All presented with advanced heart failure. The indication for valve intervention was a predominant tricuspid stenosis in three patients, significant tricuspid regurgitation in one and a mixture in three. Six procedures were conducted via a transfemoral approach and one by transatrial access. The Edwards SAPIENT™ XT valve was used in four cases and the SAPIENT™ 3 in three. Without pre-stenting/rapid pacing, all participants underwent successful valve implantation. Mean transvalvular gradient decreased from 11 ± 3 mmHg to 6 ± 3 mmHg ($P = 0.003$) and regurgitation decreased from moderate/severe (in four cases) to none/trace (in six of the seven cases). One patient remained severely symptomatic and died 3.5 months after the implantation. All others achieved a functional capacity improvement and amelioration of symptoms soon after the implantation, which persisted during follow-up.

Conclusions: TVIV may be a safe and effective strategy to treat carefully selected patients with degenerated bioprosthetic tricuspid valve at high operative risk.

KEY WORDS: transcatheter heart valve, valve-in-valve (VIV), tricuspid, degenerated bioprosthesis

IMAJ 2017; 19: 156–159

Contemporary guidelines support the growing practice of tricuspid valve surgery [1-3]. To reduce the risk of valve thrombosis, bioprosthetics are used in most tricuspid valve replacement surgeries with the inevitable risk of subsequent prosthetic valve degeneration. Redo valve surgery has been the standard of care for significant prosthetic valve degeneration; however, particularly for the tricuspid valve, it is associated with high morbidity and mortality rates [4]. Transcatheter tricuspid valve-in-valve implantation (TVIV) may be an attractive alternative to redo valve surgery, yet it is an under-explored treatment option and rather exceptional compared to valve-in-valve (VIV) implantation within degenerated aortic bioprostheses. Recent reviews of the literature [3,5] identified only a limited number of reports on TVIV, which frequently targeted young patients with congenital heart disease. In this study, we report our preliminary multicenter experience with TVIV in adult patients with acquired valvular disease.

PATIENTS AND METHODS

A datasheet was distributed to five centers in central Israel that are involved in high volume transcatheter valve therapies and have performed TVIV. Data on demographics, clinical status and co-morbidities, echocardiographic measures, procedure techniques and hemodynamic details, results, and follow-up were collected for each patient. Continuous variables are presented as means and standard deviations (SD) or medians and interquartile ranges (IQR). Paired *t*-tests and Wilcoxon tests were used to compare pre- and post-procedure valvular gradients within patients. A two-tailed $P < 0.05$ was considered statistically significant.

RESULTS

BASELINE CHARACTERISTICS

Seven patients were identified and included in the current analysis. Their mean age was 63 ± 12 years; five were female, and the mean EuroSCORE II was $13.6 \pm 3.3\%$. Six patients presented with advanced heart failure symptoms, namely New York Heart Association (NYHA) functional class III-IV, while one patient presented with moderate symptoms (NYHA II). All had left ventricular ejection fraction \geq preserved ($57 \pm 6\%$). Three patients had two prior cardiac surgeries, all had prosthetic mitral valves, and one patient also had aortic and pulmonary prosthetic valves. Severe pulmonary hypertension was present in the four patients with an echocardiographic measurable pulmonary blood pressure, atrial fibrillation was present in six, renal insufficiency in two and liver cirrhosis (secondary to right heart failure) in two patients. The mean daily furosemide dose (intravenous) at admission was 150 ± 18 mg.

TRICUSPID VALVE CHARACTERISTICS

At baseline, the mean gradient over the tricuspid valve was 11 ± 3 mmHg and four patients had tricuspid valve regurgitation \geq moderate (assessed by echocardiography). The indication for tricuspid valve intervention was a predominant tricuspid stenosis (defined as mean gradient > 5 mmHg) in three patients, a significant (\geq moderate) tricuspid regurgitation in one patient, and a mixture of both pathologies in three. Some

of their baseline characteristics are described in Table 1.

After a multidisciplinary discussion of each case, a “standard” reoperation was overruled by the heart teams due to an estimated extremely high operative risk. Given patients’ advanced symptoms, the transcatheter intervention was estimated to provide the utmost efficacy-safety profile. Consequentially, all patients gave their informed consent and were referred for TVIV.

PROCEDURAL AND IN-HOSPITAL OUTCOMES

All procedures were conducted between 2014 and 2016 via a transfemoral vein access, except for one that was conducted by a transatrial access in 2011. General anesthesia was used in four cases and conscious sedation in three. Pre-dilatation using a high pressure balloon was performed in three of six patients with significant tricuspid stenosis (using 20 mm, 24 mm, and 25 mm balloons). Five procedures were done under transesophageal, one under transthoracic, and one under intracardiac echocardiographic guidance. The Edwards SAPIEN™ XT valve (26 or 29 mm, Edwards Lifesciences, Irvine, CA, USA) was used in four cases and the SAPIEN™ 3 (29 mm, Edwards Lifesciences) in three. Without pre-stenting and without rapid pacing, all patients underwent a successful valve implantation. Figure 1 A to D (top panel) demonstrates the intraprocedural fluoroscopy of some TVIV procedure key steps. Figure 1 A to C (bottom panel) shows the fluoroscopy of a patient (index no. 5) who underwent a combined transapical mitral and transfemoral TVIV implantation.

Table 1. Patients’ demographic and historical data

Case	Center	Age	Gender	NYHA class	Native TV pathology	No. of prior surgeries	Years since TV surgery	Indication for TV surgery	Bioprosthetic TV size (mm)	Bioprosthetic TV type
1	Hadassah	63	M	2	Rheumatic	1	8	Mixed	29	Unknown
2	Sheba	39	F	3	Rheumatic	2	13	Mixed	29	Carpentier Edwards
3	Tel Aviv Sourasky	60	F	4	Rheumatic	2	20	Mixed	29	No-react
4	Rambam	65	F	4	Rheumatic	1	40	Stenosis	27	Unknown
5	Rambam	72	M	4	Myxomatous	1	14	Mixed	31	Perimount
6	Rabin	78	F	3	Rheumatic	2	37	Mixed	29	Medtronic Hancock
7	Rabin	64	F	4	Rheumatic	1	11	Mixed	33	Carpentier Edwards

NYHA = New York Heart Association, TV = tricuspid valve, Mixed = stenosis (\geq moderate) and regurgitate (\geq moderate)

Figure 1. Intraprocedural fluoroscopy.

Top panel:

[A, B] The transcatheter tricuspid valve (blue arrow) is being transported to its target position. **[C]** Without pre-stenting and pre-dilatation, balloon expansion of the valve is performed. **[D]** The device is well expanded and released in the correct anatomic position.

Lower panel:

[A] Fluoroscopy of patient (index no. 5) who underwent a combined transapical mitral valve-in-valve and transfemoral tricuspid valve-in-valve **[B]** implantations. **[C]** The final result.

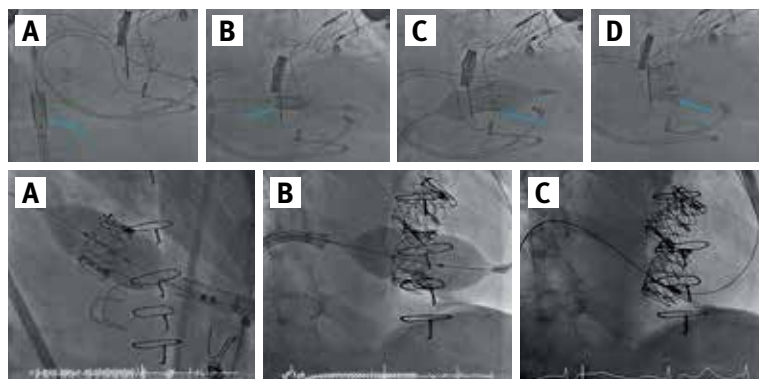


Table 2. Procedure technical and hemodynamic data

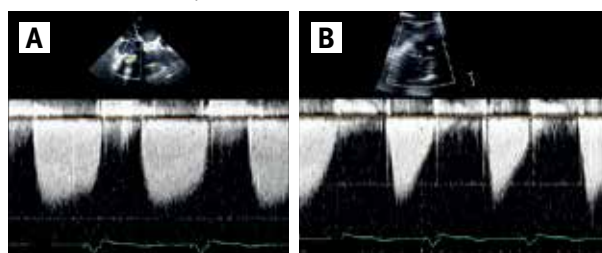
Patient	Indication	Mean gradient (mmHg)		Regurgitation		THV type, size	Balloon pre-dilatation	Rapid pacing
		Pre-	Post-	Pre-	Post-			
1	TS	12	5	Mild	Mild	SAPIEN XT, 26 mm	Yes	No
2	TS+TR	12	8	Severe	None	SAPIEN 3, 29 mm	Yes	No
3	TS+TR	10	9	Moderate	None	SAPIEN 3, 29 mm	No	No
4	TS	14	10	None	None	SAPIEN XT, 29 mm	Yes	No
5	TS+TR	10	5	Severe	Trivial	SAPIEN XT, 29 mm	No	No
6	TS	12	4	Mild	None	SAPIEN XT, 29 mm	No	No
7	TR	5	3	Moderate	Trivial	SAPIEN 3, 29 mm	No	No

RV = right ventricle, THV = transcatheter heart valve, TR = tricuspid valve regurgitation, TS = tricuspid valve stenosis

Post-implantation, tricuspid valve performance was significantly improved. Table 2 summarizes the main technical details and hemodynamic results of each procedure. The mean transvalvular gradient decreased from 11 ± 3 mmHg to 6 ± 3 mmHg ($P = 0.003$) and regurgitation decreased from moderate/severe (in four patients) to none/trace in all but one who remained with a mild tricuspid regurgitation [Figure 2].

Peri-procedural complications included one major vascular complication (femoral artery perforation near the femoral vein access site) that was treated successfully with a covered stent implantation, one case of transient periprocedural bradycardia with an escape rhythm that resolved spontaneously, and one case of ventilation-associated pneumonia that was treated with antibiotics. Following the implantation, all patients received anti-thrombotic therapy with a dual antiplatelet or a single antiplatelet combined with a vitamin K antagonist (VKA) anticoagulant agent. Five patients left the hospital in a good clinical condition 5 to 6 days after the procedure, and another patient who developed pneumonia left 11 days after the procedure. The patient who underwent the transatrial TVIV left the hospital 2 weeks after the procedure while remaining in NYHA class III heart failure.

Figure 2. Tricuspid valve hemodynamics evaluated by transesophageal echocardiography before [A] and after [B] transcatheter valve-in-valve implantation. Presented are the hemodynamics of patient 6. Baseline Doppler echocardiography demonstrating elevated (max 13 mmHg, mean 9 mmHg) gradients over the degenerated tricuspid bio-prosthetic valve, with mean pressure half-time of 480 msec at a heart rate of 60 beats per minute. Transthoracic Doppler echocardiography after the implantation indicating valvular function improvement and a decrease in gradients (max 7 mmHg, mean 4 mmHg) and in mean pressure half-time (160 msec)



Follow-up time ranged from 3 to 21 months (mean 8 ± 6 months). After discharge, the transatrial TVIV patient remained highly symptomatic and died due to a major stroke 3.5 months later. The remaining six patients experienced a significant and persistent amelioration of symptoms and improved functional capacity until the latest follow-up visit (three patients with NYHA class I, and three with NYHA class II). One of the six patients had a major stroke a year and a half after the implantation, while demonstrating subtherapeutic international normalized ratio (INR) levels with a VKA indicated for her mechanical mitral valve and atrial fibrillation. No other major safety concerns were observed during follow-up. All repetitive transthoracic echocardiography studies so far demonstrated a consistent low and stable transvalvular gradient with absence of significant leaks.

DISCUSSION

For many years redo surgery and valve replacement have been the standard of care for patients with significant degenerated bioprostheses in any position [1,2]. However, due to the high risk associated with reoperation, particularly in older patients with co-morbidities, TVIV implantations have emerged as an attractive alternative and are increasingly being performed. While so far preferentially implemented in the aortic position, given the difficulties in tricuspid valve surgery and the advantages of transcatheter intervention, reports on TVIV are mounting.

In the present study, one patient who underwent transatrial TVIV in 2011 remained highly symptomatic and died of a stroke 3.5 months after the implantation. Whether his death was directly or indirectly related to the TVIV remains unknown, as the time interval and the mechanism in which right heart side intervention causes stroke in the absence of right-to-left shunt are not clear, and stroke is unlikely to be related to TVIV. Nevertheless, this patient clearly did not benefit from the intervention.

The other six patients who underwent TVIV between 2014 and 2016 by a transfemoral approach experienced a significant improvement in their tricuspid valve function, accompanied by

functional capacity progress and symptom relief soon after the implantation and during short to midterm follow-up.

Our series demonstrates that TVIV currently represents a promising treatment solution in a carefully selected group of adult patients. Since the TVIV experience is rather preliminary, we highlight some key technical reflections.

Mal-deployment and/or erroneous sizing of the transcatheter valve may cause device dysfunction, from under-expansion, increased transvalvular gradients and regurgitations to device embolization into the right ventricle or pulmonary artery, which is a major complication reported in association with TVIV [5-7]. It is known that optimal sizing and positioning of any valve inside a bioprosthetic valve necessitates understanding of the detailed structural characteristics and that the internal ring diameter of the surgical valve is the most important determinant for sizing. To date, no imaging modality has been proven superior over another in annular size valuations. Echocardiography may underestimate annular size [8], and the manufacturer's size label mostly corresponds to the outer diameter, which is also unable to capture the temporal trends (i.e., pannus, bulky leaflets and calcifications) that might change annular size. Accordingly, at this time, a multimodality approach – systematically integrating baseline manufacturer's diameters (offering the theoretical maximum diameter), two or three-dimensional transesophageal echocardiography, fluoroscopy and in particular computed tomography (and, in selected cases, intraprocedural balloon sizing) – contributes to TVIV sizing/planning.

Earlier case reports on TVIV commonly described pre-stenting utilization with the primary goal of reducing the internal diameter of the surgical valve and also lengthening the short landing zones in some cases. As a result, pre-stenting may also reduce the internal transcatheter valve diameter and thus contribute to a smaller orifice area, which can be detrimental in the long term. In this series, as well as in another more recent report [9], pre-stenting was no longer performed since the modern devices are available in larger sizes and enable pre-stenting-free TVIV in most cases.

Another frequently described TVIV element is rapid ventricular pacing, which similar to other transcatheter balloon-expandable valve implantations is suggested to help achieve an unwavering position during balloon inflation and valve deployment. In TVIV, to avoid jailing of a right ventricular pacing lead, rapid pacing is generally achieved using a lead positioned in the left ventricle, coronary sinus or the epicardium – each with its potential damage/safety concerns. Unlike the hemodynamics that accompany aortic valve implantation, the low pressure gradients across the tricuspid valve may permit a safe and accurate valve positioning without rapid pacing, as was demonstrated in all our cases as well as in other reports [5].

At present, TVIV has been reported to be performed using either the Melody® valve (Medtronic, Minneapolis, MN, USA) or the Edwards SAPIEN™ valve. Since the former is only avail-

able in a rather small diameter size (maximum 22 mm) it can be used effectively in young patients with congenital heart disease but is less suitable for adults with acquired valvulopathy. In our series, the diameters of the failed bioprosthetic valves ranged between 29 and 33 mm, and the transcatheter valve diameters used ranged between 26 and 29 mm. To the best of our knowledge, there is only one published case report on the utilization of SAPIEN 3 in TVIV [10].

Although our follow-up time is limited, our findings of no major safety concerns, good post-TVIV device function and regression of symptoms point to TVIV as a highly reassuring treatment strategy.

CONCLUSIONS

In this preliminary case series, TVIV was found to be safe and effective for treating a carefully selected group of adult patients with a degenerated bioprosthetic tricuspid valve, without underlying congenital heart disease, and at high operative risk. Using the Edwards SAPIEN XT or SAPIEN 3 valve, TVIV led to improvement in hemodynamics and functional status, both acutely and at short to midterm follow-up. More studies with extended follow-up are needed to verify our results and to assess durability issues.

Correspondence

Dr. U. Landes

Dept. of Cardiology, Rabin Medical Center (Beilinson Campus), Petah Tikva 39100, Israel

Fax: (972-3) 924-9850, email: uri.landes@gmail.com

References

1. Vahanian A, Alfieri O, Andreotti F, et al., Joint Task Force on the Management of Valvular Heart Disease of the European Society of Cardiology, European Association for Cardio-Thoracic Surgery. Guidelines on the management of valvular heart disease (version 2012). *Eur Heart J* 2012; 33 (19): 2451-96.
2. Nishimura R, Otto C, Bonow R, et al. 2014 AHA/ACC guideline for the management of patients with valvular heart disease. A report of the American College of Cardiology/American Heart Association Task Force on practice guidelines. *J Am Coll Cardiol* 2014; 63 (22): e57-185.
3. Bouleti C, Juliard J, Himbert D, et al. Tricuspid valve and percutaneous approach: no longer the forgotten valve! *Arch Cardiovasc Dis* 2016; 109 (1): 55-66.
4. Pfannmüller B, Moz M, Misfeld M, et al. Isolated tricuspid valve surgery in patients with previous cardiac surgery. *Thorac Cardiovasc Surg* 2013; 146 (4): 841-7.
5. Godart F, Baruteau A, Petit J, et al. Transcatheter tricuspid valve implantation: a multicentre French study. *Arch Cardiovasc Dis* 2014; 107 (11): 583-91.
6. Iino K, Lozonschi L, Metzner A, et al. Tricuspid valved stent implantation: novel stent with a self-expandable super-absorbent polymer. *Eur J Cardiothorac Surg* 2011; 40 (20): 503-7.
7. Cocchieri R, Wiegierinck E, de Groot J, et al. Troubleshooting in transatrial tricuspid valve-in-valve implantation. *Ann Thorac Surg* 2012; 94 (4): 1349-52.
8. Dashkevich A, Blanke P, Siepe M, et al. Preoperative assessment of aortic annulus dimensions: comparison of noninvasive and intraoperative measurement. *Ann Thorac Surg* 2011; 91 (3): 709-14.
9. Eicken A, Schubert S, Hager A, et al. Percutaneous tricuspid valve implantation. Two-center experience with midterm results. *Circ Cardiovasc Interv* 2015; 8 (4): e002155.
10. Conradi L, Silaschi M, Seiffert M, et al. Transcatheter valve-in-valve therapy using 6 different devices in 4 anatomic positions: clinical outcomes and technical considerations. *Thorac Cardiovasc Surg* 2015; 150 (6): 1557-67.