

Learning Curve of Fine-Needle Aspiration Cytology of Head and Neck Masses

Forsan Jahshan MD, Ilana Doweck MD and Ohad Ronen MD

Department of Otolaryngology–Head and Neck Surgery, Carmel Medical Center, affiliated with Rappaport Faculty of Medicine, Technion-Israel Institute of Technology, Haifa, Israel

ABSTRACT: **Background:** Fine-needle aspiration cytology (FNAC) is used to provide rapid diagnostic information regarding masses of the head and neck. To achieve good results, adequate training is essential.

Objectives: To evaluate the efficacy of FNAC in the diagnosis of head and neck masses performed by residents and attending physicians.

Methods: Palpable guided FNA biopsies from 166 consecutive patients with head and neck masses, excluding thyroid, who were treated in our department between 2008 and 2010 were retrospectively reviewed. Accuracy, sensitivity, specificity, and positive and negative predictive values were calculated.

Results: A total of 193 FNACs were performed in 161 patients (5 patients were excluded due to age under 18). Mean age was 57.3 years; female to male ratio was approximately 5:4. Most FNACs were performed in masses in the parotid gland (37.3%), 14.5% in the posterior neck, 19.1% in the lateral neck, 15% at level 1, and 9.3% at level 6. The median size of the masses aspirated was 2 cm. Most FNACs were performed by an experienced physician (2.5:1). About 25% of the patients required a second FNAC. Almost 70% of FNACs were diagnostic. Of these, 71.2% were of benign processes and 28.8% of malignancies.

Conclusions: An FNAC of a palpable mass in all sites of the neck, excluding the thyroid, can be done as an office procedure with reasonable results without imaging guidance. About 25% of patients will require another biopsy. The procedure is not difficult to master, as evidenced by the fact that there were no differences in the results of FNACs performed by an attending otolaryngologist or a resident.

IMAJ 2016; 18: 350–353

KEY WORDS: fine-needle aspiration cytology (FNAC), head and neck cancer, residents, sensitivity, specificity

to provide rapid diagnostic information regarding palpable masses of the head and neck region [5]. Ultrasound-guided FNACs are performed to evaluate patients with deep-seated or poorly localized lesions in the head and neck region, avoiding the potential risk that can be caused when penetrating these lesions [6-8]. Furthermore, since ultrasound-guided FNAC is a more accurate procedure, it can reduce the non-diagnostic aspirations and lessen patient discomfort [9-11].

FNAC is preferred by many physicians since it is a simple, quick and inexpensive method that requires minimal equipment and can be performed in an outpatient setting. Moreover, FNAC is suitable for obtaining specimens in the delicate region of the head and neck because it is a safe procedure associated with minimal complications, compared with open biopsy which has a longer recovery time and may result in scarring, neurovascular injury, or seeding of the tumor [1,12,13]. On the other hand, FNAC has its limitations and diagnostic difficulties: specimens can be non-diagnostic due to technical problems, inability to diagnose low grade lymphoma or classify lymphoma into sub-classifications, and the difficulty in distinguishing between different salivary gland basaloid lesions [14]. Furthermore, analytical difficulties may arise when evaluating a specimen derived from radiated, post-surgical or fibrotic masses [12]. Therefore, when performing the aspiration the presence of a cytopathologist is recognized as necessary to ensure the quality of the specimen and for immediate analysis [9,15,16].

We hypothesized that the procedure is easy to master. To prove our hypothesis, we compared the characteristics of FNAC performed by otolaryngology residents and attending physicians in an outpatient clinic.

PATIENTS AND METHODS

After obtaining approval from the Institutional Ethics Committee, we retrospectively collected the medical records of 205 FNAC procedures performed in 166 consecutive patients over the age of 18, with head and neck masses excluding thyroid masses, who were treated in the Department of Otolaryngology – Head and Neck Surgery at Carmel Medical Center and Lin Medical Center, Haifa, Israel, between January 2008 and December 2010 (some patients underwent more than one FNAC procedure). The FNACs were done by either a resident

Fine-needle aspiration cytology (FNAC) is an initial and well-established technique for the management of patients presenting with head and neck lumps [1-4]. Physicians in different disciplines, including otolaryngologists, use FNAC

*Thesis in partial fulfillment of the requirements for the MD degree of F. Jahshan

or an attending otolaryngologist and were analyzed by a cytopathologist.

FNAC diagnoses were classified into two groups: the non-diagnostic group consisted of pathology reports stating: “no cells,” “inadequate,” “blood only,” or “non-diagnostic.” Pathology reports of “benign,” “suspicious for malignancy,” and “malignant,” comprised the diagnostic group. FNAC results were analyzed according to gender, age, smoking/non-smoking, alcohol consumption, anatomic location including head and neck levels, size, and examiner experience.

In the diagnostic group, after correlating the diagnostic specimen with available histological findings obtained either by surgery or open biopsy and from the patient’s records, accuracy, sensitivity, specificity, positive predictive value (PPV) and negative predictive value (NPV) were calculated. Findings were considered true positive (TP), false positive (FP), true negative (TN), and false negative (FN). The PPV was calculated as $TP / (TP + FP)$, the NPV as $TN / (TN + FN)$, and the accuracy was calculated as $TP + TN / (TP + FP + TN + FN)$. TN was considered when a benign FNAC result matched the benign histological findings or the patient record; FN was considered when there was no such match. TP was considered when a suspicious or malignant result matched the malignant histological findings or the patient record; FP was considered when there was no such match.

Student’s *t*-test was used to compare the results of the different groups. Our results were compared with the published data in the literature.

RESULTS

A total of 193 palpation-guided FNAC and 7 ultrasound-guided FNAC procedures were conducted in 161 patients with head and neck masses excluding thyroid masses (5 patients were excluded due to age under 18). All ultrasound-guided FNACs were performed as a second procedure. The mean age of the patients, 89 females and 72 males, was 57.3 ± 18.2 years. The median size of the masses was 2 cm and the mean size was 2.1 cm.

Table 1 shows the distribution of all FNAC samples by anatomic site and cytological results. Of the 193 palpation-guided FNAC specimens, 58 (30%) were non-diagnostic and 135 (70%) diagnostic. TN, TP, FN, FP, as well as the accuracy, sensitivity, specificity, PPV and NPV were calculated for each location separately and as a whole [Tables 1 and 2]. Accordingly, 96 specimens (71.2%) were benign and considered TN, and 39 (28.8%) were malignant and considered FN or TP.

Among the malignant FNAC results, there were only six suspicious results, all of which matched the final pathological finding and were considered as TP. Of these, two pairs of two consecutive FNACs of the right parotid tail were performed in two different patients. One pair of two consecutive FNACs done by an attending physician yielded marginal zone lymphoma.

Table 1. Distribution of all FNACs by anatomic sites and cytological results

Mass location	N	N%	Diag	Diag %	Non-Diag	TN	TP	FN	FP
Parotid tail	72	37.3	55	76.3	17	42	11	2	0
Level 1	29	15	22	75.8	7	19	2	1	0
Level 5	28	14.5	17	60.7	11	8	7	2	0
Level 2	22	11.4	12	54.5	10	8	4	0	0
Level 6	18	9.3	13	72.2	5	9	4	0	0
Level 3+4	15	7.7	10	66.6	5	5	4	1	0
Other	9	4.6	6	66.6	3	5	1	0	0
Total	193	100	135	70	58	96	33	6	0

N = number of aspirations, N% = the total aspiration percentage, Diag = number of diagnostic results, Diag % = the diagnostic result percentage, Non-Diag = number of non-diagnostic results, Other = head and neck masses not mentioned above, TN = true negative, TP = true positive, FN = false negative, FP = false positive

Table 2. Success of FNAC in predicting malignancy by head and neck location

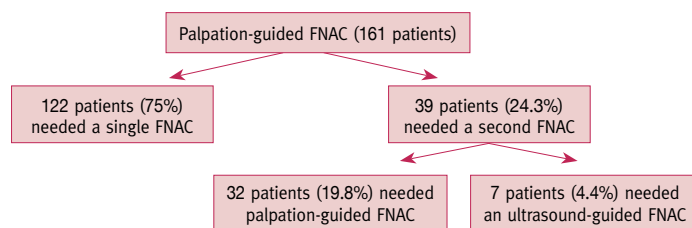
Mass location	N	Spec (%)	Sens (%)	PPV (%)	NPV (%)	Acc (%)	Diag (%)
Parotid tail	55	100	84.6	100	95.4	96.3	76.3
Level 1	22	100	66.6	100	95	95.4	75.8
Level 5	17	100	77.7	100	80	88.2	60.7
Level 2	12	100	100	100	100	100	54.5
Level 6	13	100	100	100	100	100	72.2
Level 3+4	10	100	80	100	83	90	66.6
Other	6	100	100	100	100	100	66.6
Total	135	100	84.6	100	94.1	95.5	70

N = number of diagnostic results, Other = head and neck masses not mentioned above, Spec = specificity, Sens = sensitivity, PPV = positive predictive value, NPV = negative predictive value, Acc = accuracy rate, Diag = diagnostic rate

The other pair, done by resident physicians, yielded basal cell carcinoma. Two other consecutive FNACs done by attending physicians to level 1 lymph node in one patient yielded malignant melanoma.

There were six FN results in six different patients. Of them, two masses of the parotid tail measured 2.5 cm and 1 cm. In the first patient, further ultrasound-guided FNAC was performed yielding the result of adenoid cystic carcinoma, which was confirmed later by the final histological finding. In the other patient, the final result was lymphoma. In three other patients, lymph nodes of level 1B and 5 were aspirated yielding a benign result. Both lesions turned out to be lymphoma. The last FN FNAC, done to a level 3-4 lymph node by a resident physician, yielded a reactive lymph node. In this case, papillary carcinoma of the thyroid was revealed after surgery.

For 193 palpation-guided FNACs, data regarding the physician’s experience were available. Of 159 FNAC procedures, 114 were done by attending physicians and 45 by residents (ratio 2.5:1). No statistical difference was found between the results of FNACs done by attending and those by residents.

Figure 1. Number and percentage of patients needing single and second FNAC**Table 3.** Results of published data regarding FNAC

Study	N	Spec (%)	Sens (%)	PPV (%)	NPV (%)	Diag (%)	Acc (%)
Addams-Williams et al. 2007 [17]	384	90	93	94	88	66	92
Tatomirovic et al. [18]	494	92.85	91.50	97	81.25	84	91.89
Siodlak et al. [19]	117	100	93	98	92.8	93	96
Tantan et al. [22]	2702	98.5	89.5	97.3	94	70.4	95.10
Frale and Frable [20]	346	97.1	94.2	-	-	-	95.4
Fulciniti et al. [21]	218	100	86.4	100	-	94	93.6
Morton [25]	78	99	87.5	98.9	-	85.5	94
Flynn et al. [24]	128	99	82	98	88	95	91.4
Schelkun and Grundy [23]	213	99	81	98.9	82.8	85.5	90
Current study	193	100	84.6	100	94.1	70	95.5

N = number of aspirations, Spec (%) = specificity percentage, Sens (%) = sensitivity percentage, PPV (%) = positive predictive value percentage, NPV (%) = negative predictive value percentage, Diag (%) = diagnostic rate percentage, Acc (%) = accuracy rate percentage

More than one FNAC procedure was not required for 122 patients (75.7%), while 32 patients (19.8%) underwent another palpation-guided FNAC, and 7 patients (4.4%) underwent ultrasound-guided FNAC as a second procedure [Figure 1].

DISCUSSION

The overall accuracy rate, diagnostic rate, sensitivity, specificity, positive predictive value and negative predictive value calculated in our study are high and well-accepted values for a diagnostic tool and are within the ranges quoted in the literature [Table 3]. The specificity according to these studies ranges from 90% to 100%, sensitivity 81–94.2%, positive predictive value 94–100%, negative predictive value 81.25–94%, diagnostic rate 66–95% and accuracy rate 90–95.4% [17–25]. The high specificity (100%) of all the neck masses demonstrated in our study emphasizes the high efficacy of the utility of FNAC to identify negative results.

On the other hand, the less than 100% sensitivity of the overall neck masses and of the masses in each neck location, especially in levels 1, 3, 4 and masses of the posterior neck [Table 2], demonstrates the fact that we cannot always rule out disease by depending exclusively on FNAC.

FNAC is only one step in the overall evaluation of patients with head and neck masses, and one should not rely exclusively on FNAC results. Negative FNACs results in patients with a high index of suspicion for malignancy were further investigated either by a large core needle biopsy or by removing the suspicious mass. When the FNAC results were of a benign nature, such as pleomorphic adenoma or Warthin's tumor, the tumors were operated as needed and the final results were compared with the FNAC reports

Although the majority of procedures were performed by attending physicians (ratio 2.5:1), there were no statistical differences in the results of FNACs performed by an attending or by residents in the second half of their residency. In other words, the learning period does not require years of experience and the procedure is easy to master. Moreover, it can be performed in outpatient clinics, as was done in our study.

In about 75% of patients, a single FNAC was needed for evaluation and no further aspirate was required [Figure 1], making this tool highly efficient for diagnosing masses in the head and neck region. Furthermore, in this retrospective study, the cytology results were interpreted by different cytologists (pathologists) who were not present during the procedure. The total non-diagnostic rate in our study is about 30%, which is relatively high and can be reduced. The presence of a cytopathologist during the procedure and the addition of ultrasound guidance can reduce the non-diagnostic rate [9,10,15,16], especially in the lateral and the posterior neck [Table 2]. Deep impalpable masses, masses beside blood vessels, or those small in size, should be aspirated initially by ultrasound-guided FNAC [6–8,11].

Our data show that in the head and neck region an easily palpable mass, diameter ≥ 2 cm, can be aspirated in the clinic guided by palpation only. Three of four patients yielded a diagnostic result in the parotid gland, and in levels 1 and 6. In three of five patients with a mass in other locations, a diagnostic result was achieved [Table 2].

As stated above, ultrasound-guided FNAC is a more accurate and safer procedure and should be performed whenever possible to masses in the head and neck region. However, this was a retrospective study on patients in the outpatient clinic at Lin Medical Center for the period 2009–2010. Ultrasound-guided FNAC was not available at the clinic during those years. Moreover, ultrasound is not widely available in all clinics around the country and is operator-dependent. This study emphasizes the importance of performing FNAC procedures for palpable masses of the head and neck. We contend that an otolaryngologist should master the skill of performing palpable guided FNAC of masses in the head and neck region. It is always possible to refer patients to ultrasound-guided FNAC if the mass is not palpable or if it is located in a dangerous area of the head and neck.

We found palpation-guided FNA to be an inexpensive, safe and uncomplicated tool that can be easily mastered by residents,

rendering it a useful first-line choice in investigating head and neck masses.

Correspondence

Dr. O. Ronen

Dept. of Otolaryngology–Head and Neck Surgery, Galilee Medical Center, P.O. Box 21, Nahariya 2210001, Israel

Phone: (972-4) 910-7627

Fax: (972-4) 910-7671

email: ohadr@gmc.gov.il

References

1. Anne S, Teot LA, Mandell DL. Fine needle aspiration biopsy: role in diagnosis of pediatric head and neck masses. *Int J Pediatr Otorhinolaryngol* 2008; 72 (10): 1547-53.
2. Bajaj Y, De M, Thompson A. Fine needle aspiration cytology in diagnosis and management of thyroid disease. *J Laryngol Otol* 2006; 120 (6): 467-9.
3. Murthy P, Laing MR, Palmer TJ. Fine needle aspiration cytology of head and neck lesions: an early experience. *J R Coll Surg Edinb* 1997; 42 (5): 341-6.
4. Sack MJ, Weber RS, Weinstein GS, Chalian AA, Nisenbaum HL, Yousem DM. Image-guided fine-needle aspiration of the head and neck: five years' experience. *Arch Otolaryngol Head Neck Surg* 1998; 124 (10): 1155-61.
5. Cannon CR, Replogle WH. Fine-needle aspiration: survey of clinical utility. *Otolaryngol Head Neck Surg* 2000; 123 (5): 563-5.
6. Kletzker GR, Smith PG, Bigelow DC, Leonetti JP, Grubb RL. Management of high parapharyngeal space tumors. *Ear Nose Throat J* 1991; 70 (9): 639-47.
7. Som PM, Biller HF, Lawson W. Tumors of the parapharyngeal space: preoperative evaluation, diagnosis and surgical approaches. *Ann Otol Rhinol Laryngol Suppl* 1981; 90: 3-15.
8. Som PM, Sacher M, Stollman AL, Biller HF, Lawson W. Common tumors of the parapharyngeal space: refined imaging diagnosis. *Radiology* 1988; 169 (1): 81-5.
9. Witt RL, Sukumar VR, Gerges F. Surgeon-performed ultrasound-guided FNAC with on-site cytopathology improves adequacy and accuracy. *Laryngoscope* 2015; 125 (7): 1633-6.
10. Tillman BN, Glazer TA, Ray A, Brenner JC, Spector ME. A lean neck mass clinic model: adding value to care. *Laryngoscope* 2015; 125 (11): 2509-13.
11. Kim DW. Ultrasound-guided fine-needle aspiration for retrojugular lymph nodes in the neck. *World J Surg Oncol* 2013; 30 (11): 121.
12. Karayianis SL, Francisco GJ, Schumann GB. Clinical utility of head and neck aspiration cytology. *Diagn Cytopathol* 1988; 4 (3): 187-92.
13. Göret CC, Göret NE, Özdemir ZT, et al. Diagnostic value of fine needle aspiration biopsy in non-thyroidal head and neck lesions: a retrospective study of 866 aspiration materials. *Int J Clin Exp Pathol* 2015; 8 (8): 8709-16.
14. Lü BJ, Zhu J, Gao L, Xie L, Xu JY, Lai MD. Diagnostic accuracy and pitfalls in fine needle aspiration cytology of salivary glands: a study of 113 cases. *Zhonghua Bing Li Xue Za Zhi* 2005; 34 (11): 706-10.
15. Al Hamarneh O, Liew L, Shortridge RJ. Diagnostic yield of a one-stop neck lump clinic. *Eur Arch Otorhinolaryngol* 2013; 270 (5): 1711-14.
16. Ganguly A, Burnside G, Nixon P. A systematic review of ultrasound-guided FNA of lesions in the head and neck – focusing on operator, sample inadequacy and presence of on-spot cytology service. *Br J Radiol* 2014; 87 (1044): 20130571.
17. Addams-Williams J, Watkins D, Owen S, Williams N, Fielder C. Non-thyroid neck lumps: appraisal of the role of fine needle aspiration cytology. *Eur Arch Otorhinolaryngol* 2009; 266 (3): 411-15.
18. Tatomirovic Z, Skuletic V, Bokun R, et al. Fine needle aspiration cytology in the diagnosis of head and neck masses: accuracy and diagnostic problems. *J Buon* 2009; 14 (4): 653-9.
19. Siodlak MZ, Grainger JM, Gleeson MJ, Wengraf CL. Fine needle aspiration biopsy of neck lumps in a district hospital. *Clin Otolaryngol Allied Sci* 1986; 11 (3): 131-5.
20. Frable WJ, Frable MA. Thin-needle aspiration biopsy: the diagnosis of head and neck tumors revisited. *Cancer* 1979; 43 (4): 1541-8.
21. Fulciniti F, Califano L, Zupi A, Vetrani A. Accuracy of fine needle aspiration biopsy in head and neck tumors. *J Oral Maxillofac Surg* 1997; 55 (10): 1094-7.
22. Tandon S, Shahab R, Benton JI, Ghosh SK, Sheard J, Jones TM. Fine-needle aspiration cytology in a regional head and neck cancer center: comparison with a systematic review and meta-analysis. *Head Neck* 2008; 30 (9): 1246-52.
23. Schelkun PM, Grundy WG. Fine-needle aspiration biopsy of head and neck lesions. *J Oral Maxillofac Surg* 1991; 49 (3): 262-7.
24. Flynn MB, Wolfson SE, Thomas S, Kuhns JG. Fine needle aspiration biopsy in clinical management of head and neck tumors. *J Surg Oncol* 1990; 44 (4): 214-17.
25. Morton KD. Fine needle aspiration cytology of lesions of the head and neck and factors affecting outcome. *Scott Med J* 1989; 34 (5): 523-5.