

# Role of Plain Abdominal Radiographs in the Evaluation of Patients with Non-Traumatic Abdominal Pain

Abdel-Rauf Zeina MD<sup>1</sup>, Mika Shapira-Rootman MD PhD<sup>1</sup>, Ahmad Mahamid MD<sup>2</sup>, Jalal Ashkar MD<sup>3</sup>, Saif Abu-Mouch MD<sup>4</sup> and Alicia Nachtigal MD<sup>1</sup>

<sup>1</sup>Department of Radiology, <sup>2</sup>Division of Surgery, <sup>3</sup>Emergency Department and <sup>4</sup>Department of Internal Medicine B, Hillel Yaffe Medical Center, Hadera, affiliated with Faculty of Medicine, Technion-Israel Institute of Technology, Haifa, Israel

**ABSTRACT:** **Background:** Plain abdominal radiographs are still performed as a first imaging examination to evaluate abdominal pain in the emergency department (ED), despite uncertainty regarding their utility.

**Objectives:** To describe the frequency and outcomes of the use of plain abdominal radiographs in the diagnosis of patients presenting with acute non-traumatic abdominal pain in the ED of a medical center.

**Methods:** We retrospectively reviewed the records of patients presenting to the ED with acute abdominal pain during a 6 month period. Further imaging (computed tomography, ultrasonography), when performed, was compared with the abdominal radiography.

**Results:** Of 573 consecutive patients, 300 (52%) underwent abdominal radiography. Findings were normal in 88% (n=264), non-specific in 7.3% (n=22), and abnormal in 4.7% (n=14). For those with normal results, no further imaging was ordered for 43% (114/264). Of the 57% (150/264) who had follow-up imaging, 65% (98/150) showed abnormal findings. In 9 (3%) of the 300 patients, abdominal radiography identified bowel perforations and obstructions, and treatment was provided without the need for further radiologic examination.

**Conclusions:** The use of plain abdominal radiography is still common despite the high rate of false positive results. Efforts are needed to decrease the indiscriminate use of radiography in patients presenting with abdominal symptoms.

IMAJ 2015; 17: 678–681

**KEY WORDS:** plain abdominal radiograph, abdominal pain, acute abdomen, abdominal imaging, emergency department (ED)

compared to the more recently implemented modalities, such as ultrasound, computed tomography (CT), magnetic resonance imaging (MRI) and fluoroscopy.

Despite numerous studies documenting its low sensitivity [4-11], plain abdominal imaging is still frequently ordered in the ED [1,2]. The purpose of the present study was to describe the frequency and outcomes of the use of plain abdominal radiographs in the diagnosis of patients presenting with acute non-traumatic abdominal pain to the ED of a medical institution.

## PATIENTS AND METHODS

We retrospectively reviewed the medical records of patients presenting with acute abdominal pain during a 6 month period (January to June 2010). Excluded were patients who did not have results for plain radiography, patients younger than 18 years, pregnant women, patients with a blunt or penetrating trauma, and patients with a clinical diagnosis of renal colic. Institutional review board approval was obtained for the study.

## STUDY PROTOCOL

Only the first radiograph taken for a patient was reviewed. Each interpretation was categorized as follows: (i) 'normal' – when no pathological findings were found, (ii) 'abnormal' – when bowel obstruction (small or large) or free intraperitoneal air was suspected, and (iii) 'non-specific' – when intermediate findings showed non-specific gas distribution throughout the bowel. Each medical record was further evaluated for the performance and results of additional imaging studies (CT or ultrasound), and for clinical management and outcome. The results obtained from CT or ultrasound were compared with the findings from the plain abdominal radiographs. All abdominal radiographs were interpreted by trained residents (with at least 3 years experience). Additional CT and ultrasound examinations were interpreted by senior radiologists.

Major abdominal abnormalities were defined as any finding that may explain the acute episode (such as bowel perforation, bowel obstruction, appendicitis, diverticulitis) or any finding that may have significant implications on patients' general health and outcome (such as malignancy,

Abdominal pain is one of the most common non-trauma complaints of adults presenting to the emergency department (ED) [1-3]. Yet, this complaint is non-specific with etiologies that range from trivial conditions that do not necessitate any medical intervention to life-threatening pathologies. Imaging plays a pivotal role in the decision-making process and may convey a definitive diagnosis. Plain abdominal radiograph remains an inexpensive and rapid imaging modality

abdominal aortic aneurysm, cirrhosis/portal hypertension). Examples of minor abnormalities are gallstones, renal/liver cysts, diverticulosis, hepatomegaly, splenomegaly, hernia, benign lesions and fatty liver.

**STATISTICAL ANALYSIS**

Statistical analysis was performed using SPSS version 12.0 (SPSS Inc., Chicago, USA). Continuous variables are expressed as mean ± SD.

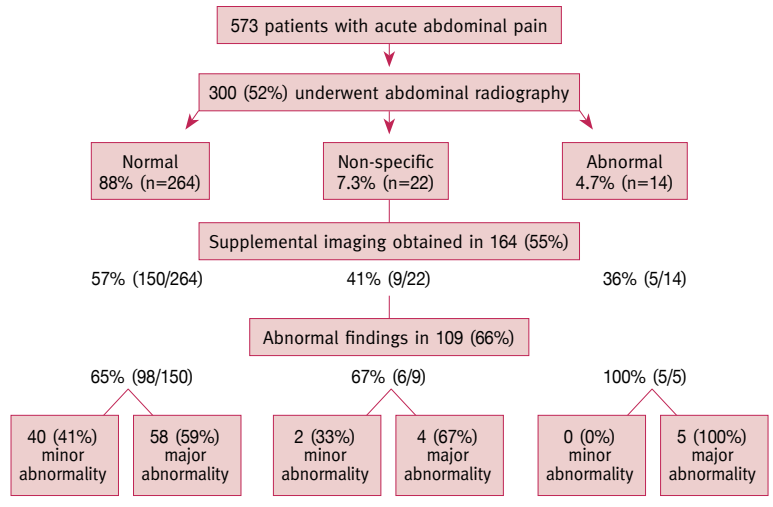
**RESULTS**

Of the 573 patients who presented with acute abdominal pain during the study period and who met study inclusion criteria, 300 (52%) underwent abdominal radiography. Figure 1 shows the number of imaging tests performed and results for the cohort. Of 300 patients, the interpretation of abdominal radiography was categorized as ‘normal’ in 88% (n=264), ‘non-specific’ in 7.3% (n=22), and ‘abnormal’ in 4.7% (n=14). Further imaging was performed in 55% (164) of all the patients with abdominal radiography results. The remaining patients (n=136), including 114 (38% of 300) with normal results, did not undergo further imaging due to resolution of symptoms (44%) or to achievement of diagnosis based on clinical grounds only (40%), or based on other modalities such as laboratory tests or endoscopy (16%). Of the 264 patients with normal abdominal radiography, 57% (n=150) had follow-up imaging; of them, 65% (98 of 150) showed abnormal findings. The proportion of abnormal findings in supplemental imaging increased to 67% (6 of 9) and 100% (5 of 5) for those with non-specific and abnormal abdominal radiography results, respectively. Nine (3%) of 300 patients with abnormal abdominal radiography results were treated without any further radiological studies. Of these patients, one had bowel perforation, one suffered from fecal impaction, one had large bowel obstruction, and six were diagnosed with small bowel obstruction. The calculated sensitivity of abdominal radiographs in detecting major abdominal abnormalities was 20%. Positive and negative predictive values for major abdominal abnormalities were calculated as 35% and 20% respectively.

**DISCUSSION**

In 1982 a prospective study concluded that halving the number of abdominal radiographs performed would not affect the identification of serious pathologies [4]. Since then, several publications have concurred with these conclusions [5-11]. Nevertheless, in our emergency department, as in others [1,2,12], abdominal radiographs continue to be ordered frequently for patients presenting with non-traumatic abdominal pain. Between the years 2001 and 2009, the use of radiographic imaging was documented to increase by 36.4% in emergency

**Figure 1.** The flow of consecutive patients presenting to the emergency department with acute abdominal pain during a 6 month period: numbers and results of abdominal radiography and supplemental imaging



departments in the United States [2]. While this rate was more than the 24.5% increase in annual visits to the department, it was considerably less than the 167% increase in the use of CT during the same period.

In the current study, bowel perforations and obstructions were accurately detected in 3% of the radiographs, with no need for further imaging. This utility of radiographs for detecting bowel obstructions is congruent with the most recent guidelines of the American College of Radiology (ACR) [13]. The ACR recommends abdominal radiograph for adults with the following indications: suspected bowel obstruction or ileus, constipation, or pneumoperitoneum; foreign body assessment; and evaluation of urinary tract stones. Other than for bowel perforations and obstructions, plain radiographs showed low sensitivity in detecting major abnormalities in the current study; supplemental imaging revealed major abnormalities in 58 (22%) of the 264 patients whose radiographs were interpreted as normal. Furthermore, the results of the abdominal radiographs did not seem to predict the performance of supplemental imaging, as CT or ultrasonography was ordered for 57%, 41%, and 36% of those with normal, non-specific, and abnormal findings, respectively. These data suggest that clinical considerations may have had a greater effect than the radiograph results on the ordering of supplemental imaging.

Although the retrospective design of the current study limits our understanding of the decision-making processes that transpired, a number of prospective studies [14-16] concluded that plain radiographs added only minimal value beyond clinical evaluation in the diagnostic workup of patients with acute abdominal pain. Yet radiographs did increase the sensitivity of detecting bowel obstruction.

Many patients in the current study were referred for plain radiographs due to indications that were not delineated by the ACR; for example, localized pain in the right or lower quadrant. For these patients, abnormalities were not detected by plain radiographs. Other studies have also described low clinical utility of abdominal radiographs for such abdominal conditions as biliary disease, appendicitis and pancreatitis [4,5,9,10]. The lack of specific radiographic features for a number of abdominal diseases, and the low soft-tissue contrast of plain radiographs explain the low diagnostic yield of this imaging modality for the differential diagnosis of abdominal pathologies. Educating and refreshing the knowledge of the emergency department staff regarding ACR guidelines may help decrease excessive and inappropriate use of radiographs. This may be a particular challenge due to the high proportion of resident physicians and interns who attend to patients in emergency departments and who may not be aware of the indications for radiographs in general and abdominal radiographs in particular. We suggest that protocols be established to ensure that referrals to X-rays will be approved by radiologists or by experienced physicians from other fields who have sufficient knowledge in the established indications for imaging.

The 88% rate of normal radiograph results was high in the current study, and the rates of abnormal and non-specific results low, 4.7% and 7.3%, respectively, compared to other studies [7,17]. This may be due to more frequent ordering of other imaging modalities during the period of the current study as compared to earlier studies conducted during periods when other imaging modalities were less available [17]. Nevertheless, the ordering of supplemental imaging in about half of those who underwent radiograph imaging in our ED is similar to the proportion reported elsewhere [7].

CT has demonstrated more accuracy than plain radiographs in diagnosing abdominal pathologies, even for bowel obstruction [1,15,18,19]. The introduction of multi-detector computed tomography (MDCT) has dramatically changed acute abdomen workup in the ER [20]. Restricting the use of CT to cases in which results of ultrasound were either negative or inconclusive has been claimed to yield the best sensitivity, with lower exposure to radiation [15]. However, the improved diagnostic certainty achieved by CT and ultrasound was not found to be associated with reduced time in the emergency department [1], reduced length of hospital stay [18], or a decrease in 6 month mortality [18]. A study that examined the changing use of imaging modalities for abdominal pain and outcomes over 35 years, from the sole use of plain radiographs in 1972 to the availability of CT and ultrasound in 2007, concluded that the increases over the years in time, money and resources had only a small impact on diagnostic specificity, without decreasing hospital admission rates or the numbers of missed surgical illness [1].

The wide availability and easy performance are advantages of the radiograph, which may contribute to its persistence,

despite the high rate of false negatives and the availability of other rapid and accurate imaging modalities. Furthermore, while unnecessary radiographs are a source of avoidable radiation exposure, the radiation dose from radiographs is about 7% that from CT, approximately 0.7 mSv compared to approximately 10 mSv [21]. While some investigators conclude that the plain abdominal radiograph offers no utility in the workup of adult patients with acute abdominal pain [7,22], others claim that some patients do benefit from abdominal radiographs: both those who receive accurate diagnoses and those for whom normal results preclude supplementary imaging [23]. To the degree that plain radiographs may avert the use of imaging examinations that pose greater radiation risk and that entail greater financial and professional resources, the radiographs have utility. On the other hand, to the degree that they may delay appropriate treatment, convey avoidable radiation, or entail the unnecessary use of health care resources, they are without utility at best and may even be detrimental [22].

## CONCLUSIONS

This study showed high usage, yet low diagnostic yield, of plain abdominal radiography in adult patients presenting with abdominal pain in the emergency department. Protocols should be established to decrease the indiscriminate use of abdominal radiography.

## Correspondence

**Dr. A.R. Zeina**

Dept. of Radiology, Hillel Yaffe Medical Center, P.O. Box 169, Hadera 38100, Israel

**Phone:** (972-4) 630-4621

**Fax:** (972-4) 630-4884

**email:** raufzeina3@hotmail.com

## References

- Hastings RS, Powers RD. Abdominal pain in the ED: a 35 year retrospective. *Am J Emerg Med* 2011; 29: 711-16.
- Pines JM, Mullins PM, Cooper JK, Feng LB, Roth KE. National trends in emergency department use, care patterns, and quality of care of older adults in the United States. *J Am Geriatr Soc* 2013; 61: 12-17.
- Salvi F, Mattioli A, Giannini E, et al. Pattern of use and presenting complaints of older patients visiting an emergency department in Italy. *Aging Clin Exp Res* 2013; 25: 583-90.
- Eisenberg RL, Heineken P, Hedgcock MW, Federle M, Goldberg HI. Evaluation of plain abdominal radiographs in the diagnosis of abdominal pain. *Ann Intern Med* 1982; 97: 257-61.
- Campbell JP, Gunn AA. Plain abdominal radiographs and acute abdominal pain. *Br J Surg* 1988; 75: 554-6.
- Feyler S, Williamson V, King D. Plain abdominal radiographs in acute medical emergencies: an abused investigation? *Postgrad Med J* 2002; 78: 94-6.
- Kellow ZS, MacInnes M, Kurzencwyg D, et al. The role of abdominal radiography in the evaluation of the nontrauma emergency patient. *Radiology* 2008; 248 (3): 887-93.
- Smith JE, Hall EJ. The use of plain abdominal x rays in the emergency department. *Emerg Med J* 2009; 26: 160-3.
- Jackson K, Taylor D, Judkins S. Emergency department abdominal x-rays have a poor diagnostic yield and their usefulness is questionable. *Emerg Med J* 2011; 28: 745-9.

10. Bhangu A, Richardson C, Winter H, Bleetman A. Value of initial radiological investigations in patients admitted to hospital with appendicitis, acute gallbladder disease or acute pancreatitis. *Emerg Med J* 2010; 27: 754-7.
11. Nagurney JT, Brown DF, Novelline RA, Kim J, Fischer RH. Plain abdominal radiographs and abdominal CT scans for nontraumatic abdominal pain – added value? *Am J Emerg Med* 1999; 17: 668-71.
12. Latham LP, Ackroyd-Stolarz S. Emergency department utilization by older adults: a descriptive study. *Can Geriatr J* 2014; 17: 118-25.
13. ACR-SPR Practice Parameter for the Performance of Abdominal Radiography. Amended 2014 (Resolution 39).
14. Prasannan S, Zhueng TJ, Gul YA. Diagnostic value of plain abdominal radiographs in patients with acute abdominal pain. *Asian J Surg* 2005; 28: 246-51.
15. Laméris W, van Randen A, van Es HW, et al., OPTIMA study group. Imaging strategies for detection of urgent conditions in patients with acute abdominal pain: diagnostic accuracy study. *BMJ* 2009; 338: b2431.
16. van Randen A, Laméris W, Luitse JS, et al, OPTIMA study group. The role of plain radiographs in patients with acute abdominal pain at the ED. *Am J Emerg Med* 2011; 29: 582-9.e2.
17. Ahn SH, Mayo-Smith WW, Murphy BL, Reinert SE, Cronan JJ. Acute non-traumatic abdominal pain in adult patients: abdominal radiography compared with CT evaluation. *Radiology* 2002; 225: 159-64.
18. Sala E, Watson CJ, Beadsmoore C, et al. A randomized, controlled trial of routine early abdominal computed tomography in patients presenting with non-specific acute abdominal pain. *Clin Radiol* 2007; 62: 961-9.
19. Stoker J, van Randen A, Laméris W, Boermeester MA. Imaging patients with acute abdominal pain. *Radiology* 2009; 253: 31-46.
20. Leschka S, Alkadhi H, Wildermuth S, Marincek B. Multi-detector computed tomography of acute abdomen. *Eur Radiol* 2005; 15: 2435-47.
21. Wall BF, Hart D. Revised radiation doses for typical X-ray examinations. Report on a recent review of doses to patients from medical X-ray examinations in the UK by NRPB. National Radiological Protection Board. *Br J Radiol* 1997; 70: 437-9.
22. Gans SL, Stoker J, Boermeester MA. Plain abdominal radiography in acute abdominal pain; past, present, and future. *Int J Gen Med* 2012; 5: 525-33.
23. Eisenberg RL. The role of abdominal radiography in the evaluation of the nontrauma emergency patient: new thoughts on an old problem. *Radiology* 2008; 248: 715-16.