

Atypical Femoral Fractures: Radiological Evaluation and Bisphosphonate Exposure

Liana Tripto-Shkolnik MD^{1*}, Elena Segal MD^{3,7*}, Anat Jaffe MD⁵, Sophia Ish-Shalom MD⁷, Rakefet Bachrach MD², Alicia Nachtigal MD^{6,7*} and Daniela Militianu MD^{4,7*}

¹Metabolic Bone Diseases Clinic, Meuhedet Health Fund, Raanana, Israel

²Medical Management, Clalit Medical Services, Sharon-Shomron District, Israel

³Metabolic Bone Diseases Unit and ⁴Department of Medical Imaging, Rambam Health Care Campus, Haifa, Israel

⁵Endocrinology and Diabetes Unit and ⁶Department of Medical Imaging, Hillel Yaffe Medical Center, Hadera, Israel

⁷Rappaport Faculty of Medicine, Technion-Israel Institute of Technology, Haifa, Israel

ABSTRACT: **Background:** Evidence suggests that prolonged bisphosphonate (BP) treatment predisposes to atypical fractures (AF), but the etiology has yet to be determined. Addressing causality begins with case identification, which requires radiological adjudication. However, many trials based their case findings on coded diagnoses.

Objectives: To investigate the feasibility of case findings by the coding system and the reproducibility of radiological evaluations in two hospitals in Israel, and to compare BP exposure of AF patients to a control group with typical (intertrochanteric of femoral neck) fractures.

Methods: Diagnostic databases from 2007 to 2010 were reviewed and admission X-rays of patients were examined in two steps by two radiologists. Fractures were classified as atypical or not atypical according to published criteria. A 2:1 control group was created. Ambulatory drug acquisition was reviewed.

Results: Of the 198 patients who fulfilled the search criteria, 38 were classified by initial radiological opinion as AF. Subsequent radiological opinion judged 16 as not atypical. Of the AF patients, 80% were exposed to BP. Of those, 81% continued to receive BP treatment for 2.4 years after AF. Only one AF patient was discharged with suspected AF diagnosis. In the control group, 27% were exposed to BP prior to fracture ($P < 0.001$).

Conclusions: Thorough radiological revision is mandatory for proper classification of AF, and even when performed there is significant inconsistency in interpretation. Conclusions drawn from trials based solely on coded diagnoses lead to significant bias. BP exposure was significantly higher in the AF group. Caregiver unawareness of AF leads to improper management.

IMAJ 2015; 17: 554–558

KEY WORDS: atypical fractures, bisphosphonates (BP), osteoporosis, radiological evaluation, drug exposure

The possible connection between prolonged bisphosphonate (BP) use and femoral shaft fractures has generated much concern in recent years. The first such report, published in 2005 by Odvina et al. [1], examined the incidence of unusual fractures as a result of minor trauma. In the intervening years, numerous case reports (as summarized by Giusti et al. [2]), case reviews, and retrospective case-controlled large epidemiological studies have been published. One such controlled mega-trial that retrospectively examined 10 years of medical claims data in the United States showed more frequent BP use in patients with shaft and subtrochanteric fractures than in those with other hip fractures [3]. However, since radiological data were unavailable, the fractures were classified as atypical based on location alone. Another large study, from Canada, demonstrated an increased risk for subtrochanteric/shaft fractures with long-term (over 5 years) BP treatment, but this work, too, lacked X-ray data [4].

In support of the findings of these earlier studies, subsequent research that included radiological data obtained similar results. A study of data from a Level 1 trauma hospital in New York retrospectively analyzed patients with low trauma subtrochanteric fractures and compared them to controls with typical femoral fractures [5]. All X-rays were reviewed, conferring on these cases high reliability in terms of expected distinct fracture patterns [6]. Fourfold more BP use was found in atypical fracture patients. Similar data, pointing to a possible association between femoral shaft fractures and BP exposure, were collected in Singapore [7] and Sweden [8]. Finally, researchers from Switzerland analyzed data – namely, clinical parameters, drug exposure, and X-rays – of patients with atypical femoral fractures and compared them with the corresponding data of patients with classical fractures of the subtrochanteric area, and of controls who did not sustain fractures. All the admission X-rays were reviewed twice. This study found a very strong association between BP use and the risk for atypical fracture, which showed a significant positive correlation with duration of exposure [9]. On the other hand, other reports found no association between BP use and subtrochanteric fractures. For

*These authors contributed equally to the study

instance, a large cross-sectional study from Denmark [10], for which radiological data were unavailable, showed similar percentages of BP use in patients with typical and subtrochanteric fractures, including shaft fractures. Patients with higher alendronate treatment compliance (based on medication possession ratio, MPR) enjoyed a significantly lower risk for fractures, both at the hip and at atypical sites [10].

An additional post hoc analysis of pivotal randomized controlled trials testing BP (alendronate and zoledronic acid) treatment for fracture prevention did not show an increased risk of atypical fractures in the treated group [11], though the studies were not designed for that analysis from the beginning.

The studies reviewed above and numerous others [12] were summarized in a 2010 American Society of Bone and Mineral Research (ASBMR) report [6], in which the major and minor criteria for identifying a fracture as atypical were established. The major criteria, all of which should be present to designate a femoral fracture as atypical, are (i) location in the subtrochanteric region or femoral shaft, (ii) transverse or short oblique orientation, (iii) minimal or no associated trauma, (iv) presence of a medial spike when the fracture is complete, and (v) absence of comminution. A second, recently published (2014) version of the ASBMR report included a revision of the criteria [13]. According to the newer definition, four of the five major criteria (as opposed to all) should be present. The absence of comminution has changed to “non-comminuted” or “minimally comminuted,” and the criterion of transverse or short oblique orientation has changed to “the fracture line originates at the lateral cortex and is substantially transverse, although it may become oblique as it progresses medially across the femur.” From the 2010 version, a minor criterion, “localized periosteal reaction of the lateral cortex,” has been changed in the 2013 version to a major criterion, “localized periosteal or endosteal thickening of the lateral cortex is present at the fracture site (breaking or flaring).” The newer ASBMR position statement further highlights the relationship between AF and BP exposure with a positive correlation between exposure length and the AF risk [13]. A position paper from the International Osteoporosis Foundation (IOF) concluded that the possible association of BP use with atypical subtrochanteric fractures is unproven, and further research and clinical data collection are needed to accurately establish prevalence and risk factors [14]. In their extensive review of BP safety in September 2011, the Food and Drug Administration (FDA) also addressed the issue, concluding, in agreement with two previous position statements [6,14], that atypical fractures are very rare [15]. However, the FDA also stated that although causality has not been determined, the mounting data suggest a strong association between BP use and the incidence of atypical fracture.

In summary, the current evidence suggests that atypical fractures, regardless of whether they are associated with BP use, are rare [16]. Although the current case definition as proposed by ASBMR requires radiological adjudication, many investigations

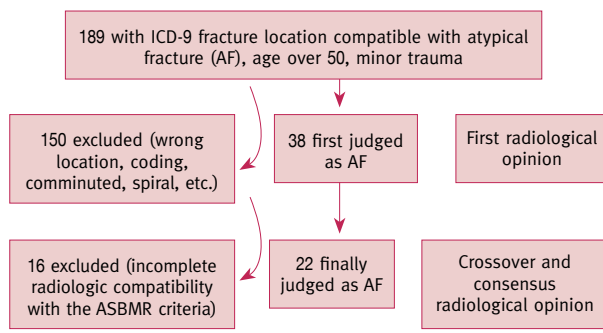
of the possible association between fractures and bisphosphonate use lacked radiological assessment and instead based their case findings solely on coded diagnoses. In the present study, therefore, based on data from two hospitals in central and northern Israel, we reviewed the prevalence of atypical fractures. Our analysis entailed examining the applicability of case findings based on the existing coding system to retrospective studies on fractures, the reproducibility of radiological evaluations, and the clinical parameters and bisphosphonate exposure levels of patients with atypical fractures compared to those with typical femoral fractures.

PATIENTS AND METHODS

The computerized databases of discharge diagnoses for the years 2007–2010 in two hospitals were reviewed. These hospitals, Rambam Health Care Campus in northern Israel and Hillel Yaffe Medical Center in the center of the country, are located 50 km apart. International Classification of Diseases (ICD-9) diagnoses compatible with fracture location below the femoral neck and above the distal femoral condyles were chosen for data retrieval. We used the following discharge codes: subtrochanteric fractures 820.22; supracondylar fractures 821.23, 821.33; shaft fractures 821.01, 821.11.

Patients younger than 50 years of age and those with major trauma were excluded. Admission femoral X-rays of patients with allegedly suitable fracture locations were examined in two steps by two senior radiologists with expertise in bone radiology. First, each radiologist individually reviewed the X-rays of the patients from her medical center; in the second step, a joint crossover examination was performed and a consensus was reached. The fractures were classified as atypical or not atypical according to the published criteria [6,13]. Agreement of both radiologists was required for categorization of the fracture pattern as atypical. Following publication of the updated criteria [13], we re-examined the X-rays to ensure that the fractures still qualified as atypical according to the new criteria. Hospital files and ambulatory drug acquisition data of patients with atypical fractures were reviewed. The information retrieved from the hospital files was: (i) functional status prior to fracture, (ii) use of walking aids, (iii) fracture mechanism (e.g., minimal trauma or no trauma), and (iv) prodromal symptoms.

The control group comprised patients with typical hip fractures in the cervical region matched two-to-one to atypical fracture patients and matched for age, gender, ethnicity (Jewish or Arab), and month of fracture. Data retrieval was based on ICD-9 diagnoses compatible with supratrochanteric location (820.00–820.09). When it was impossible to find an age- and gender-matched control patient within 1 month of the AF date, the period was extended until an appropriate control was found. Fracture locations in control patients were verified by examining their admission X-rays.

Figure 1. Radiological adjudication process

The ambulatory database (from 1999 onwards) was searched for BP acquisition, and the percentage of MPR was calculated (the number of months in each year of treatment that the patient purchased the medication).

RESULTS

A total of 1916 hip fracture patients were treated at Rambam Medical Center from 2007 to 2010, and 1207 patients with femoral fractures were treated at Hillel Yaffe during the same period (total 3123). According to the relevant ICD-9 codes, 189 patients fulfilled the search criteria compatible with subtrochanteric fracture location.

In the initial group, 81 fractures at Hillel Yaffe were coded as subtrochanteric, and of those, 22 (27%) were found to be inter- or intratrochanteric and were therefore excluded. Thirty-eight fractures were classified by the two radiologists (separately) as atypical according to the published criteria [6] [Figure 1]. After crossover radiological examinations were performed and the two examiners reached a consensus, 16 fractures (41%) were judged not compatible with the above-mentioned criteria (mainly because of oblique configuration). A third review of the radiological data (following publication of the updated version of AF criteria) did not change the consensus. Of the remaining 21 patients with 22 atypical fractures (one patient sustained an atypical fracture twice, left and right midshaft, 2 years apart), 20 were women aged 59–91 (mean age 75.5 ± 8.3). Thirteen patients (61.9%) were functionally intact prior to fracture, while 3 (14.2%) used walking sticks and 5 (23%) used walkers. Five patients (23.8%) suffered atraumatic fractures while the other 16 fell from standing height. One patient reported prodromal groin pain.

The control group consisted of 44 patients (42 women, 2 men) whose median age was 76.3 ± 7.9 years. The coded diagnoses in this group were accurate, and 100% of the fractures were validly classified as inter- or pertrochanteric.

Meticulous BP acquisition data from the ambulatory database were available from 1999 onwards for 20 of the 21 patients with atypical fractures – one patient was a tourist, and

alendronate was mentioned in her admissions file. Of the 20 for whom BP acquisition data were available, only 4 patients were BP naïve, while the vast majority (16 patients, 80%) had been exposed to BPs in the past, with treatment durations of 2–11 years (6.8 ± 2.5 years). For all patients, MPR was over 80%.

In the control group of 44 patients, 9 (20.4%) were exposed to BP prior to fracture ($P < 0.001$). Although the durations of exposure did not differ significantly from those of the AF group (5 ± 2.6 years), in contrast to the AF patients, all of whom were exposed to BP until the fracture, three of the nine patients with prior BP exposure discontinued BP treatment several years before sustaining typical fractures (range 2–6 years). Compliance with the BP was lower in the control group, for which the MPR was 70%.

Notably, of the atypical fracture patients with histories of BP exposure, 13 (81%) continued to receive BP treatment for an average of 2.4 years (range 1–5 years) after sustaining the fracture. Included in this group was a female patient who, over a 2 year period, fractured her femoral shaft twice, once on each side, and continued BP treatment during the intervening time between the two fractures and for 3 years after the second fracture. In addition, during their hospitalization in orthopedic departments, only 1 of the 21 patients with 22 atypical fractures had been correctly diagnosed. In fact, the discharge documents of the other 20 patients did not express any concerns that their fractures may have been atypical or in any way out of the ordinary.

Among the patients with radiologically adjudicated atypical fractures, 8 (36%) and 14 (64%) were diagnostically coded as subtrochanteric fractures and femoral shaft fractures, respectively, upon their discharge from hospital.

DISCUSSION

Atypical fractures and their possible etiological connection to prolonged BP use is an intriguing issue that has attracted increasing attention in recent years. But the current data, which comprise studies that either do or do not support the connection between prolonged BP exposure and atypical fractures, are conflicting. The marked differences in trial methodologies between studies pose methodological pitfalls that greatly complicate the task of reaching definitive conclusions. Fundamental to this shortcoming is proper case definition of the atypical fracture, as precision is critical to reliably determine whether a connection exists between BP exposure and the incidence of atypical fractures. As a rule, large analyses of databases have used discharge codes compatible with subtrochanteric location as a case-finding tool.

We have shown here that ICD codes were inaccurate in a significant proportion of cases. Therefore, we conclude that using coded diagnoses alone cannot accurately identify cases of atypical fracture. As such, conclusions drawn from trials based solely on coded diagnoses may lead to significant bias.

To reliably define a fracture as atypical currently requires radiological adjudication. A fracture is classified as atypical if it has transverse or short oblique orientation and a medial spike when the fracture is complete and if comminution is absent. In our study, the X-ray films of participants were examined separately by two senior radiologists with expertise in bone radiology, and only after both experts had analyzed all X-rays did they reach a consensus on each patient. As we have shown here, significant inconsistency in interpretation persists, even in the hands of very experienced professionals. The major point of “disagreement” between the radiologists was the degree of obliqueness according to which a fracture can be classified as atypical. Thorough radiological revision is therefore a prerequisite to obtaining precise and accurate classifications of atypical fractures. Indeed, even when done properly according to the existing guidelines, fracture diagnoses are still prone to the examiner’s subjectivity. Since conclusions about BPs being a causation factor begin with case identification, one should realize that even radiologically adjudicated cases are often a matter of subjective opinion. In our group of patients with precise medication histories, significantly more patients with atypical fractures were exposed to BPs compared to the control group.

The very high ratio of MPR in our group is noteworthy. As has been widely reported, compliance with BP treatment tends to be low, especially in the long term [17]. This finding leads to a cautious hypothesis that exceptionally high compliance with the medication may have contributed to the outcome of atypical fractures, since the degree of bone turnover suppression, due to long-term and accurate BP consumption, may have been profound. Unfortunately, the retrospective nature of our data retrieval precluded our obtaining bone turnover marker data to prove this hypothesis.

Only one patient with AF was correctly diagnosed during hospitalization in the orthopedic department. As mentioned previously, most of the subjects had been treated with BPs, but no recommendations were made regarding a possible need to cease or change treatment. Although there are no firm guidelines regarding when treatment with BP should be stopped in a patient with an atypical fracture, it seems prudent to reconsider whether therapy with a bone turnover-suppressing agent is needed. An anabolic alternative makes pathophysiological sense, and moreover, several reports have indicated the efficacy of treating atypical fracture patients with bone-forming agents [6,18,19]. Nonetheless, it is advisable that such distinctive fractures be recognized and properly addressed during the index hospitalization.

Moreover, 81% of the atypical fracture patients, including a patient with a recurrent fracture, continued to receive oral BPs for an average of more than 2 years after the fracture occurred. As we mentioned earlier, none of the discharge documents specified or characterized the fracture as “odd,” atypical, or as possibly BP related. As a result, primary care physicians may

have assumed that the patients suffered typical osteoporotic fractures and no change of therapy was suggested. Although the cause and effect of BP exposure and atypical fracture is still unproven, most experts recommend that BP treatment be discontinued in those patients, a recommendation that was also suggested in the ASBMR position statement.

The limitations of the current study include the small cohort of patients and the retrospective nature of data retrieval. Since only two radiologists participated in the crossover evaluation, different results might have been observed if more examiners had been involved. The findings regarding suboptimal management of the AF patients both during hospitalization and in ambulatory care might be a result of local practices and are possibly inapplicable elsewhere.

Despite the limitations, our study sheds light on the inaccuracy of coded diagnoses, the subjectivity of radiological assessments, and the extremely high prevalence of past BP exposure with high treatment compliance in atypical fracture patients and corresponding lack of caregiver awareness of this unique entity. Taken together, these findings indicate that the current lack of protocols for diagnosing and treating atypical fractures may lead to improper patient management.

Acknowledgments

The authors would like to thank Mrs. Ariela Ehrlich MLS, and Mr. Patrick Martin for revision and proofreading of the manuscript.

Correspondence

Dr. L. Tripto-Shkolnik

P.O. Box 79, Hod Hasharon 4510002, Israel

Fax: (972-9) 740-6014

email: lianatrish@gmail.com

References

1. Odvina CV, Zerwekh JE, Rao DS, Maalouf N, Gottschalk FA, Pak CY. Severely suppressed bone turnover: a potential complication of alendronate therapy. *J Clin Endocrinol Metab* 2005; 90: 1294-301.
2. Giusti A, Hamdy NA, Papapoulos SE. Atypical fractures of the femur and bisphosphonate therapy: a systematic review of case/case series studies. *Bone* 2010;47: 169-80.
3. Nieves JW, Bilezikian JP, Lane JM, et al. Fragility fractures of the hip and femur: incidence and patient characteristics. *Osteoporos Int* 2010; 21: 399-408.
4. Park-Wyllie LY, Mamdani MM, Juurlink DN, et al. Bisphosphonate use and the risk of subtrochanteric or femoral shaft fractures in older women. *JAMA* 2011; 305: 783-9.
5. Lenart BA, Neviasser AS, Lyman S, et al. Association of low-energy femoral fractures with prolonged bisphosphonate use: a case control study. *Osteoporos Int* 2009; 20: 1353-62.
6. Shane E, Burr D, Ebeling PR, et al. Atypical subtrochanteric and diaphyseal femoral fractures: report of a task force of the American Society for Bone and Mineral Research. *J Bone Miner Res* 2010; 25: 2267-94.
7. Koh JS, Goh SK, Png MA, Kwek EB, Howe TS. Femoral cortical stress lesions in long-term bisphosphonate therapy: a herald of impending fracture? *J Orthop Trauma* 2010; 24: 75-81.
8. Schilcher J, Aspenberg P. Incidence of stress fractures of the femoral shaft in women treated with bisphosphonate. *Acta Orthop* 2009; 80: 413-15.
9. Meier RP, Perneger TV, Stern R, Rizzoli R, Peter RE. Increasing occurrence of atypical femoral fractures associated with bisphosphonate use atypical femoral fractures and bisphosphonate use. *Arch Intern Med* 2012; 172: 930-6.

10. Abrahamsen B, Eiken P, Eastell R. Subtrochanteric and diaphyseal femur fractures in patients treated with alendronate: a register-based national cohort study. *J Bone Miner Res* 2009; 24: 1095-102.
11. Black DM, Kelly MP, Genant HK, et al. Bisphosphonates and fractures of the subtrochanteric or diaphyseal femur. *N Engl J Med* 2010; 362: 1761-71.
12. Rosenthal Y, Arami A, Kosashvili Y, Cohen N, Sidon E, Velkes S. Atypical fractures of the femur related to prolonged treatment with bisphosphonates for osteoporosis. *IMAJ* 2014; 16: 78-82.
13. Shane E, Burr D, Abrahamsen B, et al. Atypical subtrochanteric and diaphyseal femoral fractures: Second report of a task force of the American Society for Bone and Mineral Research. *J Bone Miner Res* 2013; 29: 1-23.
14. Rizzoli R, Akesson K, Bouxsein M, et al. Subtrochanteric fractures after long-term treatment with bisphosphonates: a European Society on Clinical and Economic Aspects of Osteoporosis and Osteoarthritis, and International Osteoporosis Foundation Working Group Report. *Osteoporosis* 2013; 22: 373-90.
15. Weiss M, Ben-Shlomo A, Hagag P, Ish-Shalom S. Discrimination of proximal hip fracture by quantitative ultrasound measurement at the radius. *Osteoporos Int* 2000; 11: 411-16.
16. Ish-Shalom S. Atypical osteoporotic fractures: impact on therapeutic decision making in osteoporosis. *IMAJ* 2014; 16: 110-12.
17. Cramer JA, Gold DT, Silverman SL, Lewiecki EM. A systematic review of persistence and compliance with bisphosphonates for osteoporosis. *Osteoporos Int* 2007; 18: 1023-31.
18. Carvalho NN, Voss LA, Almeida MO, Salgado CL, Bandeira F. Atypical femoral fractures during prolonged use of bisphosphonates: short-term responses to strontium ranelate and teriparatide. *J Clin Endocrinol Metab* 2011; 96: 2675-80.
19. Chiang CY, Zebaze RM, Ghasem-Zadeh A, Iuliano-Burns S, Hardidge A, Seeman E. Teriparatide improves bone quality and healing of atypical femoral fractures associated with bisphosphonate therapy. *Bone* 2013; 52: 360-5.