# Should Intravenous Contrast be Administered in MRI Evaluation of Pediatric Outpatients with Chronic Headache?

Sigal Tal MD*, Michael Abrahamy MD*, Paul Gottlieb MD, Hillel Maresky MD and Anna Ben Ely MD

Department of Radiology, Assaf Harofeh Medical Center, Zerifin, affiliated with Sackler Faculty of Medicine, Tel Aviv University, Tel Aviv, Israel

**ABSTRACT:** **Background:** The practice of administering intravenous contrast to children varies by institution depending on their routine.

**Objectives:** To assess the necessity of routine contrast administration in brain magnetic resonance imaging (MRI) of pediatric outpatients referred for chronic headache workups.

**Methods:** We conducted a retrospective review of consecutive pediatric brain MRI examinations performed during January and February 2014 in 30 pediatric outpatients referred for evaluation of chronic headache. Independent review was performed by two board-certified neuroradiologists. The raters reviewed each MRI first as a non-contrast examination (without seeing the post-contrast images) and then with post-contrast images.

**Results:** No abnormalities were found in six patients. One patient had an indeterminate finding of a tubular cerebellar lesion requiring follow-up. In the remaining patients (n=23), the findings were subclinical and included: mucosal thickening in the paranasal sinuses in 9 patients, cystic changes of the pineal gland in 8 (size 2–9 mm), small developmental venous anomalies in 6, non-specific FLAIR hyperintensities in 4, opacification of the mastoids in 2, and telangiectasia in 1 patient. The subclinical cases that were missed on pre-contrast images were: one small developmental venous anomaly, one telangiectasia and one small pineal cyst, none of which hold clinical significance. All kappa inter-rater and intra-rater agreement scores resulted in values above 0.75, excellent agreement according to Fleiss guidelines.

**Conclusions:** There seems to be little reason to medically justify large-scale use of routine IV contrast administration to evaluate a brain MRI of pediatric patients referred for chronic headache.

*IMAJ* 2015; 17: 545–548

**KEY WORDS:** pediatrics, magnetic resonance imaging (MRI), chronic headache, intravenous contrast, gadolinium

Headache is a common complaint, even in early childhood. Chronic headache is defined as headache occurring for 15 days or more a month for at least 3 months and not the result of another condition. The prevalence of headache increases with age, ranging from 37% to 51% for children aged 7 years and gradually increases to 57–82% by age 15 [1]. Most children have primary headaches such as a migraine or tension headaches, typically chronic or recurrent. Serious intracranial pathology is rare and includes brain tumors, meningitis, venous sinus thrombosis, arterial dissection, subarachnoid hemorrhage, and other disorders that may require prompt management [1]. Brain tumors in children < 15 years of age have an annual incidence approximating only 3 per 100,000 (0.003%) [1]. The need to distinguish primary from secondary headaches presents a major challenge, leading to an increase in referrals for brain magnetic resonance imaging (MRI). The question then arises whether or not to administer intravenous (IV) contrast?

The practice of giving IV contrast to children varies by institution depending on their routine. Recent publications by one group discuss the indiscriminate use of gadolinium in neuroimaging [2,3]. The authors concluded that there is no general need for gadolinium administration in MRI of the brain in children younger than 2 years old, with clinical questions regarding seizures and developmental delay; furthermore, gadolinium-based contrast media administration should be reserved for those with suspected or known brain infection and malignancy [2,3].

The use of IV contrast lengthens the study and increases procedure costs, may cause allergic reactions and, rarely, nephrogenic systemic fibrosis. The aim of our study was to evaluate the necessity of routine IV contrast administration in brain MRI of pediatric outpatients referred for chronic headache workups.

## PATIENTS AND METHODS

This study received institutional review board approval. We conducted a retrospective review of consecutive pediatric brain MRI examinations performed during January and February 2014 in 30 pediatric outpatients referred for evaluation of chronic headache. Excluded were patients who had a concomitant disorder listed in the referral, for example epilepsy.

An independent review of the brain MRI examinations was performed by two board-certified neuroradiologists. The raters reviewed each MRI first as a non-contrast examination

*The first two authors contributed equally to this study

(blinded to the post-contrast images) and then with the post-contrast images. When the interpretation differed between the two raters, the final interpretation was reached by consensus. Kappa statistical analysis was used to assess inter-rater and intra-rater agreement.

## RESULTS

After reviewing the medical files of 70 pediatric outpatients who underwent brain MRIs during January and February 2014, 40 were found not to meet the study criteria. Of the 30 subjects who constitute the basis of the evaluation, there was an almost even distribution of males and females; 14 were male (47%). The mean age at the time of examination was 12.3 years (range 7–17). All the MRI examinations were performed without anesthesia. The MRI studies were performed on 1.5T and 3.0T systems (Siemens Aera and Skyra, Erlangen, Germany) in 12 and 18 patients, respectively. All studies were performed with IV contrast administration and included T1, T2, FLAIR, DWI, and post-contrast T1. Additional SWI sequences were done in Twenty-three patients.

In six patients no abnormalities were found. One patient had an indeterminate finding of a tubular cerebellar lesion, suggestive of a thrombosed venous varix and requiring follow-up [Figure 1]. In the remaining patients the findings were subclinical and included mucosal thickening in the paranasal sinuses in 9 patients, cystic changes of the pineal gland in 8 (size 2–9 mm) [Figure 2], small developmental venous anomalies in 6 [Figure 3], non-specific FLAIR hyperintensities in 4, opacification of the mastoids in 2 patients and telangiectasia in 1 patient. Of the 30 patients examined, there were no cases of headache secondary to space-occupying lesion. Twenty-three patients were found to have incidental and subclinical findings [Table 1]. Twenty cases (87%) of incidental findings were revealed on contrast. The only changes that were missed on pre-contrast images were one small developmental venous anomaly, one telangiectasia and one small pineal cyst.

Kappa inter-rater and intra-rater agreement analysis was performed for subclinical findings resulting in the following (values listed in parentheses):

- radiologist # 1 pre-contrast vs. radiologist # 2 pre-contrast ($\kappa = 0.75$)
- radiologist # 1 post-contrast vs. radiologist # 2 post-contrast ($\kappa = 0.86$)
- radiologist # 1 pre-contrast vs. radiologist # 1 post-contrast ($\kappa = 0.90$)
- radiologist # 2 pre-contrast vs. radiologist # 2 post-contrast ($\kappa = 0.84$).

In two cases (6%), enlargement of glandular tissue was reported by one observer in both pre- and post-contrast studies and omitted by the other observer.

**Table 1.** Brain MRI radiologic findings

| Radiologic finding | No. of patients |
|---|---|
| Mucosal thickening of paranasal sinuses | 9 |
| Benign cystic changes of pineal gland | 8 |
| Small developmental venous anomaly | 6 |
| Non-specific foci of white matter signal changes | 4 |
| Opacification of mastoids | 2 |
| Telangiectasis | 1 |
| Tubular cerebellar lesion | 1 |

## DISCUSSION

The choice whether or not to inject intravenous contrast in pediatric chronic headache sufferers begins with evaluating the appropriateness of referral. Obviously, administration of IV contrast confers added value in diagnosing intracranial lesions and vascular pathology [1]. However, in the patient population of primary headache sufferers, this hypothetical advantage pales in comparison to the low yield of imaging as a screening tool [1]. While the appropriateness of MRI referral for the aforementioned cohort may be in question, we are dealing with a unique situation where the off-site referring physician has been granted approval for the study by the patient's health management organization and its advisory board which includes an off-site radiologist. In our retrospective study, many of these exams may be considered inappropriate according to the 2012 American College of Radiology appropriateness criteria [1]; however, in the context of off-site referrals and off-site authorization, some institutions may find themselves reluctantly accepting these types of exams. It is in this context that we suggest, according to the Hippocratic Oath *primus nos nocerem* (first do no harm), not to inject gadolinium when it is not required or essential to provide added value.

The choice of whether to inject contrast is also based on practical measures, such as the availability of a neuroradiologist or fellow to supervise the exam. At some institutions, pediatric examinations are supervised by radiologists who decide during the course of the examination whether administration of gadolinium is appropriate, while other institutions opt for predefined routine protocols including automatic and routine gadolinium administration [4]. Supervising pediatric MRI examinations confers the added value of theoretically omitting the unnecessary IV contrast administration according to the findings in each specific case and thus shortening the length of the studies by omitting the unnecessary sequences from the standard protocols. Moreover, supervision may increase the quality of the examinations, where the supervising radiologist may request to repeat suboptimal sequences immediately and perform additional sequences, if necessary. When the MRI examinations are

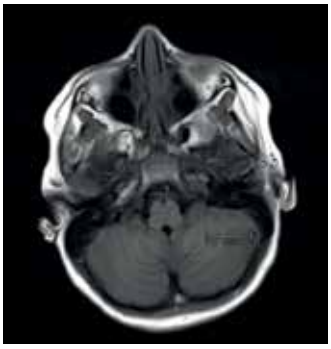

**Figure 1.** Tubular cerebellar lesion visualized on pre-contrast T1

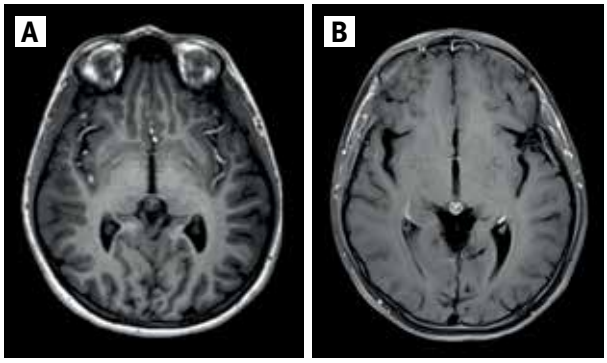


**Figure 2. [A]** Benign cystic changes of the pineal gland on pre-contrast T1. **[B]** Post-contrast T1 image confirms the benign character of these cystic changes because there is no nodular enhancement of the septae

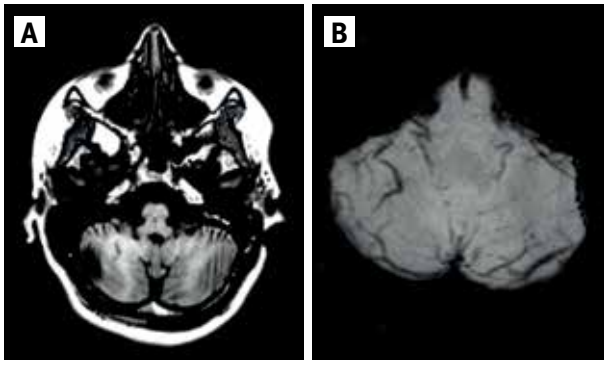


**Figure 3.** A small developmental venous anomaly in the right cerebellar hemisphere, depicted on the pre-contrast T1 images **[A]** as a hypointense linear branching lesion, with associated blooming on SWI images **[B]**

supervised, their protocols become more flexible and patient oriented. However, obvious limitations such as additional staff and additional financial resources result in the reality that many departments cannot afford to supervise all MRI cases.

In some departments where a neuroradiologist or pediatric fellow is actively involved in supervising pediatric MRI examinations, some cases may be initially slated as non-contrast and the supervising fellow can decide to change the protocol based on pre-contrast images. Supervising pediatric MRI examinations, however, may hamper effectiveness by limiting the number of examinations according to regular work shifts. Why individual examinations are not supervised can be attributed to the use of routine protocols selected based on clinical information, the performance of the examinations during off-hours, and time effectiveness [5].

Many institutes rely on routine administration of IV contrast when performing brain MRI in pediatric patients. In this study, clinically significant findings were not missed on pre-contrast images. In view of the discomfort caused by placing the IV catheter, the indiscriminate use of gadolinium adds unnecessary cost and time to the MRI examination. In terms of gantry time, additional post-contrast sequences prolong the examination by approximately one-third [4]. Furthermore, contrast media administration may cause contrast-induced nephropathy, the third leading cause of hospital-acquired acute kidney injury accounting for 10% of all cases [6].

One of the major challenges in pediatric neuroimaging is the acquisition of high-quality diagnostic images. Motion artifacts affect the quality of the examination and, as a result, also the ability to correctly interpret the test. In order to overcome this problem infants are sedated or anesthetized for MRI examinations [7]. Much of the reluctance to perform a non-contrast examination is the inconvenience and potential complications of having to put the child through anesthesia a second time. Therefore, anesthesia cases are often routinely performed with contrast administration, unless they are supervised by a neuroradiologist. As children need to be able to verbally communicate that they are suffering from a chronic headache, they tend to be slightly older (> 7 years). This corresponds with our study where the patients' ages ranged from 7 to 17. Children over age 7 are scanned, where possible, without sedation [8].

This study has several limitations that should be noted. There was a significant difference in the number of years of clinical neuroradiology experience between the two certified neuroradiologists: 15 years for radiologist # 1 ($\kappa = 0.90$ intra-rater) and 4 years for radiologist # 2 ($\kappa = 0.8$), which may have affected the slight albeit clinically insignificant difference in kappa values of agreement before and after administration of contrast ($\kappa = 0.75$, $\kappa = 0.86$, respectively). Of note, according to Fleiss guidelines, a kappa value of $\geq 0.75$ is considered excellent interpretation, which was observed on intra- and inter-rater agreements. Our results should be interpreted with caution because of the relatively small sample size of this study, only 30 patients. A larger population should be evaluated to further investigate this issue and to further explore the appropriateness of the ACR criteria in the setting of off-site referral and authorization.

There seems to be little reason to justify large-scale use of routine contrast administration to evaluate brain MRI in pediatric patients referred for chronic headache. For children not requiring anesthesia, one should consider performing the

examination without IV contrast administration, and in specific cases where a significant finding is noted the patient can be called back to complete the exam with IV contrast.

**Acknowledgments**

Prof. Simon Strauss is gratefully acknowledged for reviewing and providing insightful feedback on this article.

**Correspondence**

**Dr. M. Abrahamy**

Dept. of Radiology, Assaf Harofeh Medical Center, Zerifin 70300, Israel

**Fax:** (972-8) 954-2152

**email:** michael.abrahamy@gmail.com

## References

1. American College of Radiology (ACR) Appropriateness Criteria headache – child. Guideline Summary NGC-9226; Revised 2012 (Guidelines).
2. Petrou M, Foerster B, Maly PV, Eldevik PO, Leber S, Sundgren PC. Added utility of gadolinium in the MRI work-up of seizures in children under the age of two. *J Child Neurol* 2007; 22: 200-3.
3. Foerster BR, Ksar J, Petrou M, et al. Value of gadolinium administration in brain MRI examinations for developmental delay in children less than two years of age. *Pediatr Neurol* 2006; 35: 126-30.
4. Sundgren PC, Leander P. Is Administration of gadolinium-based contrast media to pregnant women and small children justified? *J MRI* 2011; 34: 750-7.
5. Sundgren PC. Is there a need for use of contrast in the pregnant mother and small children? In: Proceedings of the 17th Annual Meeting ISMRM, Honolulu, 2009.
6. Shema L, Ore L, Geron R, Kristal B. Contrast-induced nephropathy among Israeli hospitalized patients: incidence, risk factors, length of stay and mortality. *IMAJ* 2009; 11: 460-4.
7. Golan A, Marco R, Raz H, Shany E. Imaging in the newborn: infant immobilizer obviates the need for anesthesia. *IMAJ* 2011; 13: 663-5.
8. Saunders DE, Thompson C, Gunny R, Jones R, Cox T, Chong WK. Magnetic resonance imaging protocols for paediatric neuroradiology. *Pediatr Radiol* 2007; 37: 789-97.