

Unilateral Obstructive Urinothorax Secondary to Colorectal Carcinoma

Yuval Tal MD PhD^{1*}, Ido Weinberg MD MSc^{3*}, Arie Ben-Yehuda MD¹ and Mordechai Duvdevani MD²

¹Division of Internal Medicine and ²Department of Urology, Hadassah-Hebrew University Medical Center, Jerusalem, Israel

³Section of Vascular Medicine, Massachusetts General Hospital, Boston, MA, USA

KEY WORDS: urinothorax, urinary tract obstruction, colorectal carcinoma, pleural effusion

IMAJ 2015; 17: 321–322

Urinothorax (or urothorax) is the presence of urine in the pleural space. It is rare, is usually iatrogenic, can occur after urinary tract manipulation, or may be due to urinary tract obstruction [1]. It can be bilateral or unilateral, usually on the same side as the obstruction, and resolves after the obstruction is resolved [2]. Obstructive urinothorax in adults is usually secondary to bilateral, and not unilateral obstruction of the urinary tract. When unilateral obstruction causes urinothorax it is usually associated with an occult nephro-pleural tract or a single functioning kidney [1]. Only two previous reports described non-traumatic urinothorax associated with unilateral urinary tract obstruction secondary to tumor. In the first, the authors reported a recurrent pleural effusion secondary to an abdominal mass causing hydronephrosis and massive urinoma, and in the second, Looi and Lee [2] described urinothorax contralateral to a mildly obstructive renal mass without perinephric fluid collection. We report a case of non-traumatic urinothorax associated with unilateral urinary tract obstruction and perinephric fluid accumulation.

PATIENT DESCRIPTION

A 71 year old man presented after a week of fever (38°C), chills and shortness of breath. His medical history consisted of stage II sigmoid adenocarcinoma and a single liver

*The first two authors contributed equally to this study

metastasis that had been excised 5 and 3 years earlier, respectively. Consequently he received 5-fluorouracil and leucovorin as adjuvant therapy for 6 months. Prostate carcinoma, categorized as low risk, had been treated with radiation and short-term treatment with goserelin 2 years prior to the current hospitalization. His past medical history also included pemphigus vulgaris treated with maintenance dose prednisone, and ischemic heart disease without congestive heart failure.

On admission he was afebrile and had no flank pain. Physical examination revealed decreased breath sounds on the left and dullness to percussion. Cardiac examination was normal and there was no jugular venous distension or peripheral edema. Chest X-ray revealed left pleural effusion. Pleural tap resulted in 1300 ml of clear yellowish fluid, with lactate dehydrogenase (LDH) of 504 U/L (634 U/L in the serum) and total protein < 20 g/L. Pleural fluid-to-serum creatinine ratio was 117/80 μmol/L. Urea measured 14 mg/dl in the fluid and 12.6 mg/dl in the serum. Fluid pH was 6.92. Fluid cytology was normal. Computed tomography (CT) of the chest, abdomen and pelvis demonstrated left pleural fluid accumulation, left hydronephrosis and a large perinephric fluid collection [Figure 1A]. Urine cytology revealed cancerous cells. Fluid re-accumulated despite repeated pleural taps. A thoracocentesis was performed and 4 L of fluid were evacuated. Repeat pleural fluid cytological examinations failed to demonstrate cancerous cells. Hydrothorax was eliminated only after insertion of a nephrostomy drain and did not recur. Ureteroscopy was performed, showing external pressure on the left ureter, without any sign of urothelial tumor. The rest of the examination was within normal limits. Positron emission tomography

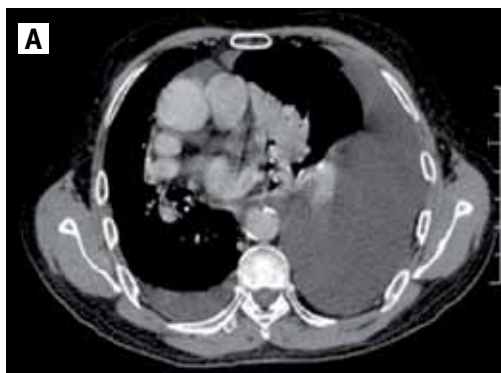(PET)-CT was performed and demonstrated a para-aortic mass, consistent with tumor [Figure 1B]. Laparotomy demonstrated that the tumor involved the ligament of Treitz and the fourth part of the duodenum and penetrated the left ureter. Pathologic examination revealed a well-differentiated adenocarcinoma staining positively for CDx2 and carcinoembryonic antigen (CEA) on immunohistochemistry which was noted to originate from the colon [Figure 1C, D, E].

Following surgery the patient was treated with 2 week cycles of 5-fluorouracil, oxaliplatin, leucovorin and bevacizumab on the assumption that he had metastatic colon cancer, despite a normal surveillance colonoscopy. Oxaliplatin was stopped after 8 months of treatment due to neuropathy. Bevacizumab was discontinued 3 months later because of gastrointestinal bleeding. He was then treated with 5-fluorouracil, leucovorin and irinotecan. Repeat colonoscopies and CT did not show recurrence of tumor.

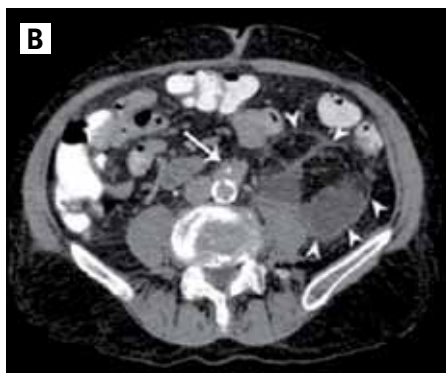COMMENT

We present a case of non-traumatic unilateral hydronephrosis associated with urinoma and urinothorax. To the best of our knowledge this is the first such case secondary to metastasis of colon adenocarcinoma penetrating the ureter. Suggested mechanisms for urinothorax include extension of urine through the diaphragm or its passage via lymphatic connections between the peritoneum and pleural space following the negative intrapleural pressure [2]. The presence of urinoma in our case suggests the first mechanism.

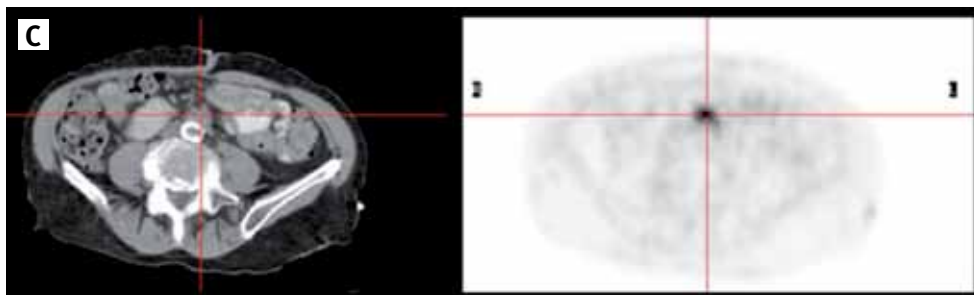
Urinothorax has been previously described in relation to bilateral urinary tract obstruction, urinary tract manipulations, inflammation, malignancy, trauma, shock wave



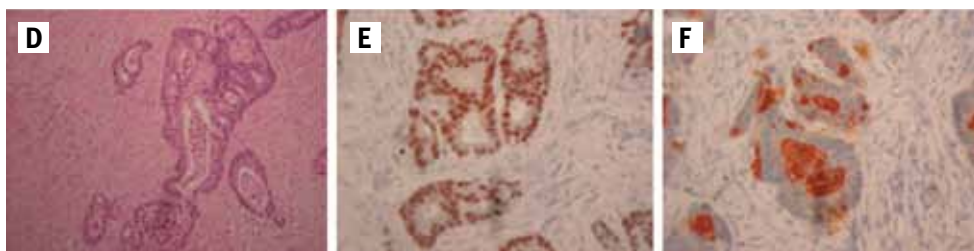[A] Axial CT image of the patient's chest showing a large left pleural effusion displacing the mediastinum to the right



[B] Axial CT image of the patient's abdomen, showing a retroperitoneal mass (arrow) and fluid collection around the left kidney (arrowheads)



[C] Axial PET image of the patient's abdomen showing radionucleotide uptake correlating to the retroperitoneal mass



[D] Well-differentiated adenocarcinoma, composed of well-defined malignant glands (hematoxylin & eosin, original magnification x 200). The neoplastic epithelial cells are immunoreactive for the colonic markers CDx2 **[E]** and CEA **[F]** (original magnification x 400)

lithotripsy, and posterior urethral valve. Congenital cases also exist. It has been suggested that urinorhox can be either obstructive, following bilateral urinary tract obstruction, or traumatic, which is usually unilateral [1]. Unilateral ligation of the ureter in dogs failed to produce urinorhox. A recently published case described a unilateral urinoma secondary to obstruction from nephrolithiasis in a patient with multiple metastases. Although the obstruction resulted in a large abdominal bulging mass, it did not evolve to urinorhox [3]. Comprehensive review of the literature

also failed to find additional non-traumatic unilateral causes for urinorhox. Obstructive urinorhox was considered different to traumatic and was defined as bilateral. Accordingly, only two cases of unilateral non-traumatic urinary tract obstruction associated with urinorhox were previously described.

Urinorhox is the only cause of a transudate with low pH (pH < 7.3), although the LDH in the fluid may be relatively high [1]. A pleural fluid-to-serum creatinine ratio greater than 1 may be sensitive, albeit not specific [1]. This is consistent with our

case. The urea concentration in the pleural fluid was similar to that of the serum. Urea has a low molecular weight and diffuses rapidly through the pleura [4]. Of note, in most previous reports no biochemical characteristics of the fluid were provided and the diagnosis was made according to the clinical relationship with urinary tract obstruction, also present in our case [1].

Spontaneous urinorhox is a rare clinical manifestation and seldom anticipated; diagnosis and treatment can be misleading. A therapeutic trial with furosemide can actually elevate pleural fluid quantity by increasing urine output, thus producing more fluid. As in the case presented, treatment of the urinary tract obstruction resolves the urinorhox. Recently a large retrospective trial was published in support of non-operative management of urinomas; however, the research referred only to blunt trauma-related renal injuries and conclusions could not be drawn for the management of non-traumatic obstructions [5].

In conclusion, non-traumatic, unilateral urinorhox is a rare clinical manifestation of upper urinary tract obstruction. Elimination of the obstruction can alleviate or even eliminate the process. We therefore suggest that in the presence of unilateral hydrothorax urinorhox be suspected and sought, especially in patients with a history of metastatic cancer.

Correspondence

Dr. Y. Tal

Allergy and Clinical Immunology Unit, Dept. of Medicine, Hadassah-Hebrew University Medical Center (Ein Kerem Campus), P.O. Box 12000, Jerusalem 91120, Israel

email: yuvalt@hadassah.org.il

References

- Garcia-Pachon E, Romero S. Urinorhox: a new approach. *Curr Opin Pulm Med* 2006; 12: 259-63.
- Looi LM, Lee P. An unusual case of unilateral transudative pleural effusion. *Chest* 2006; 130: 328S.
- Tsai CF, Liao CY, Lin CH, Shiao CC. Huge urinoma presenting as a bulging mass. *Nephrology* 2013; 18: 477.
- Laskaridis I, Kampantais S, Toutziaris C, et al. Urinorhox – an underdiagnosed cause of acute dyspnea: report of a bilateral and of an ipsilateral urinorhox case. *Case Rep Emerg Med* 2012; 2012: 395653.
- van der Wilden GM, Velmahos GC, Joseph DK, et al. Successful nonoperative management of the most severe blunt renal injuries: a multicenter study of the research consortium of New England Centers for Trauma. *JAMA Surg* 2013; 148: 924-31.