

Presacral Mass Discovered during Pregnancy followed by Myasthenia Gravis

Barak Benjamin MD¹, Roy Zaltzman MD PhD², Baruch Shpitz MD¹, Carlos R. Gordon MD DSc² and Shmuel Avital MD¹

Departments of ¹Surgery B and ²Neurology, Meir Medical Center, Kfar Saba, affiliated with Sackler Faculty of Medicine, Tel Aviv University, Tel Aviv, Israel

KEY WORDS: presacral area, Castleman's disease, myasthenia gravis, pregnancy

IMAJ 2015; 17: 318–320

The presacral area is the site of fusion of the spine and differentiation of the posterior cloaca in the embryonic period and contains bony, neural, vascular, lymphoid and intestinal tissue. For this reason, although presacral masses are a relatively rare clinical entity, their differential diagnosis is extensive, including both benign and malignant lesions. The majority of these lesions are of cloacal origin (chordomas, developmental cysts, duplication cysts, dermoid cysts, teratomas, anterior meningoceles, and adrenal rest tumors – together constituting two-thirds of presacral masses), osseous tumors (Ewing's tumor, osteogenic sarcomas), nerve tissue tumors (ependymomas, neurofibromas), inflammatory masses (e.g., retrorectal abscess), and other lesions such as rectal gastrointestinal stromal tumor (GIST), neuroendocrine tumors, endometriosis, and lymphomas.

The traditional approach to presacral masses is surgical excision without prior biopsy in order to avoid secondary infection of the tumor and needle-tract tumoral seeding. Exceptions to this rule are when the biopsy tract can be included within the resection margins easily, or when imaging suggests a tumor that might benefit from neoadjuvant therapy (e.g., GIST).

We describe here the unusual case of a young woman who presented with a presacral mass during pregnancy, followed soon after by signs of myasthenia gravis.

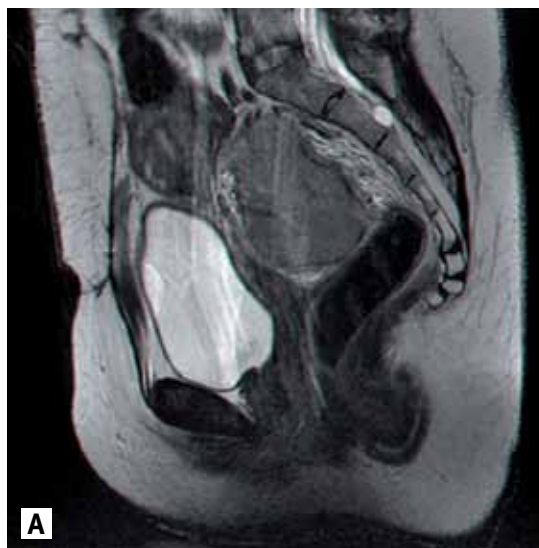PATIENT DESCRIPTION

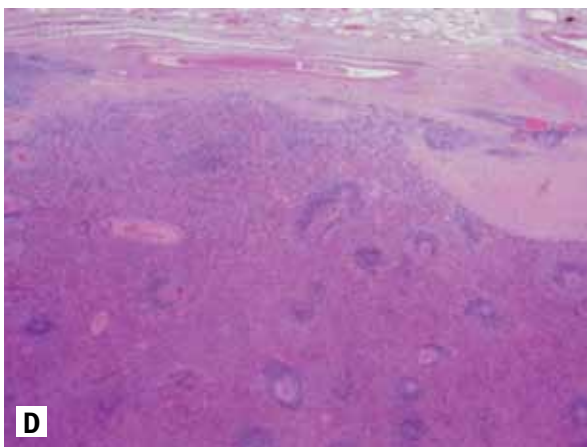
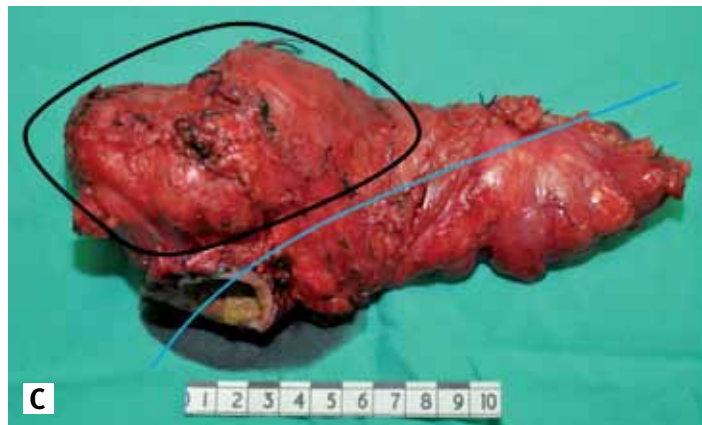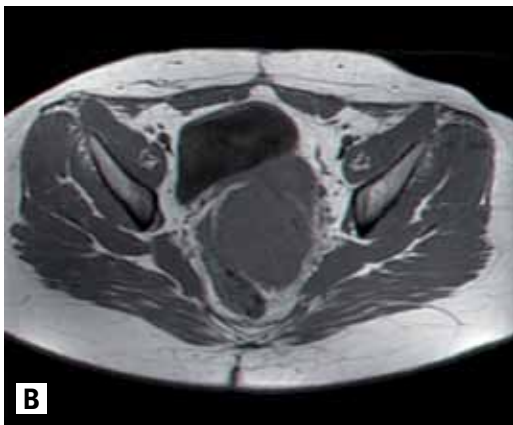
A 29 year old woman, in her 20th week of pregnancy, admitted to our gynecology department with acute lower abdominal pain in August 2010 and underwent explorative laparoscopy for a suspected ovarian torsion. Due to inability to visualize the adnexae the operation was converted to laparotomy; the ovaries were found to be normal, but a hard fixed mass 6 cm in diameter was palpated in the left posterior pelvis. No further steps were taken and the patient was referred to magnetic resonance imaging (MRI), which identified a presacral non-cystic mass measuring 6 cm deviating slightly to the left of the midline [Figure 1A]. It was decided at this point that any further workup would be delayed until after delivery. At term, an elective cesarean section was performed, yielding a healthy child. Shortly after the birth the mother was admitted to the neurology department

with complaints of episodic double vision, ptosis, dysarthria and dysphagia that appeared during prolonged activity. Based on a positive edrophonium test and high acetylcholine receptor (AChR) antibodies titer, the diagnosis of myasthenia gravis was made. Treatment with pyridostigmine and prednisone was initiated with good clinical response. Further evaluation on chest computed tomography (CT) revealed some remnant thymic tissue and a thymectomy was considered. At the same time, a follow-up pelvic MRI was done, which showed enlargement of the presacral mass, now measuring 8 cm in diameter, involving the rectal wall with a thin division-plane separating it from the sacral bone [Figure B].

At this point it was decided that the presacral mass should be addressed first, and the patient was scheduled for surgery (June 2011). Operative findings included a hard mass in the posterior mesorectum deviating to the left and encasing the bowel, but

[A] Pelvic MRI, sagittal view, shows a large presacral mass compressing the rectum. A clear posterior plane separates the mass from the sacral bone





[B] Pelvic MRI, axial view. A posterior mass left to the midline is displacing the uterus and the rectum

[C] The excised specimen. The tumor, encased by the mesorectum, is encircled in black. The blue line represents the longitudinal axis of the rectum

[D] Hematoxylin-eosin stain shows distinctive follicles with expanded mantle zones of small lymphocytes, forming rings that surround atretic germinal centers. Note the marked vascularity and perivascular hyalinization

with no lateral or sacral involvement. A low anterior resection with total mesorectal excision was performed [Figure C]. The postoperative course was uneventful.

Pathological examination of the specimen revealed an enlarged lymph node showing changes indicative of Castleman's disease, predominately the hyaline vascular type [Figure D].

The patient's myasthenic signs worsened (ptosis, dysphagia, dysarthria, and slight weakness in the facial, neck flexor and proximal upper limb muscles) in the months following the operation despite treatment with prednisone, pyridostigmine and azathioprine. In November 2011 she underwent a thymectomy. Pathology showed an involuted thymus, mostly substituted by fatty tissue, with lymphoid tissue but no follicular hyperplasia.

At follow-up 23 months after the removal of the presacral mass and 18 months

after the thymectomy, the patient feels well and has had no pelvic recurrence. The myasthenia is well controlled without weakness or fatigue; she is still under treatment with prednisone, pyridostigmine and azathioprine. As a result of the prednisone treatment the patient suffers severely from a cushingoid habitus.

COMMENT

Castleman's disease is a peculiar type of benign lymph node hyperplasia, first described by Benjamin Castleman in 1956 [1]. The disease can arise in any lymphoid tissue in the body, and there have even been reports of extranodal locations. Castleman's disease presents in two forms, distinct both clinically and pathologically. The localized form, usually pauci-symptomatic, is the hyaline vascular (HV) type, characterized by a solitary enlarged lymph node. On

histology, specimens show distinctive follicles with expanded mantle zones of small lymphocytes forming concentric rings that surround atretic germinal centers with predominant vascularity and perivascular hyalinization [2].

Frequently located in the mediastinum, the hyaline vascular type may also develop in the lungs, the mesentery, the retroperitoneum, and the pelvis, as in our patient. The treatment of choice in such cases is complete surgical excision, which is curative [2]. By contrast, the multicentric form of the disease, namely the plasma cell (PC) type, is usually symptomatic, with constitutional signs, peripheral adenopathy and hepatosplenomegaly. Histological changes are less distinctive compared to the HV type. The disease usually affects an aggregate of lymph nodes, in contrast to the unicentric type of Castleman's disease. The etiology of this type of disease has not yet

been elucidated. In some cases it has been linked to a chronic herpes virus 8 infection and over-expression of interleukin-6. Treatment options for the PC Castleman type include chemotherapy, glucocorticoids, radiation, and sometimes surgical intervention to alleviate symptoms.

Myasthenia gravis (MG) is an autoimmune neuromuscular junction disorder, characterized by muscular weakness and fatigue and caused by anti-AChR antibodies. About a quarter of MG cases have other autoimmune conditions. Myasthenia gravis can occur as a paraneoplastic syndrome, where an immune response against an epitope expressed on the neoplastic cells, typically thymoma cells, involves the neuromuscular junction and produces symptoms. A thymoma can be found in as many as 15% of MG patients, and other malignancies such as breast and colon cancer can be found in an additional 5–10% of the patients. It is interesting to note that Castleman himself described the angio-follicular hyperplasia bearing his name as “resembling thymoma” [1].

Our patient reported her myasthenic symptoms shortly after delivery. However, her disease could have started “silently” during pregnancy and exacerbated when pregnancy ended. The onset of MG can be triggered during pregnancy or postpartum. Furthermore, MG is unmasked or exacerbated in approximately one-third of patients during their pregnancy. There are very few reports on thymoma and MG concomitantly discovered during pregnancy [3]. MG patients can have a normal pregnancy

and delivery but the course is unpredictable [3]. There is a 40% chance of exacerbation of MG during pregnancy and an additional 30% risk in the puerperium. Interestingly, amelioration of MG symptoms or even complete remission may occur in some women in the second or third trimester, thought to be related to the physiologic immunosuppression that occurs during those phases of gestation [4]. Shorter disease history and infection predispose to puerperal exacerbation. Sudden and frequently severe exacerbations, including respiratory insufficiency, may occur in the first 3 weeks postpartum [4]. The sudden drop in alpha-fetoprotein (AFP) concentration is implicated as a possible cause of this phenomenon. In addition, puerperium complications, especially infection, seem to increase the risk for exacerbations of MG symptoms during this period.

So far, only 12 other cases of patients with Castleman’s disease and myasthenia gravis have been reported in the literature, with varying results regarding remission of myasthenic symptoms after tumor removal; most of them showed no improvement [3-5]. Therefore, though it might be tempting to consider the synchronous occurrence of two disorders of immunological pathophysiology as more than mere coincidence, no causal relation has yet been proven, and it is questionable whether a connection between the two actually exists. Recently, Jakubiková et al. [4] reported on a patient with myasthenia gravis, localized Castleman’s disease, pemphigus and antiphospholipid syndrome,

and hypothesized that the temporal coincidence of these clinical entities may be related to a common immunological pathway, such as B cell activation. Consequently, they offered treatment with monoclonal antibodies against CD-20 (rituximab). Rituximab treatment was shown to be efficacious as a neoadjuvant treatment for unicentric Castleman’s diseases (hyaline vascular type) [5]. It was also shown to be an efficacious and well-tolerated treatment for refractory and non-refractory myasthenia gravis [5]. Therefore, its use allows for dose reduction or withdrawal of corticosteroids attenuating their undesirable side effects.

Correspondence

Dr. B. Benjamin

Dept. of Surgery B, Meir Medical Center, Kfar Saba 4428164, Israel

Fax: (972-9) 747-1305

email: barak.benjamin@gmail.com

References

1. Castleman B, Iverson L, Menendez VP. Localized mediastinal lymphnode hyperplasia resembling thymoma. *Cancer* 1956; 9: 822-30.
2. Bucher P, Chassot G, Zufferey G, Ris F, Huber O, Morel P. Surgical management of abdominal and retroperitoneal Castleman’s disease. *World J Surg Oncol* 2005; 3: 33.
3. Emson HE. Extrathoracic angiofollicular lymphoid hyperplasia with coincidental myasthenia gravis. *Cancer* 1973; 31: 241-5.
4. Jakubiková M, Pitha J, Latta J, Ehler E, Schutzner J. Myasthenia gravis, Castleman disease, pemphigus, and anti-phospholipid syndrome. *Muscle Nerve* 2013; 47: 44-51.
5. Cronin DMP, Warnke RA. Castleman disease: an update on classification and the spectrum of associated lesions. *Adv Anat Pathol* 2009; 16 (4): 236-46.