

# Valve-Sparing Aortic Root Surgery in a Patient with Loeys-Dietz Syndrome

Michael Shpoliansky BSc\*, Dan Spiegelstein MD\*, Amihai Shinfeld MD and Ehud Raanani MD

Department of Cardiac Surgery, Sheba Medical Center, Tel Hashomer, affiliated with Sackler Faculty of Medicine, Tel Aviv University, Tel Aviv, Israel

**KEY WORDS:** Loeys-Dietz syndrome (LDS), aorta, aneurysm, valve sparing, reimplantation

IMAJ 2015; 17: 185–187

**L**oeys-Dietz syndrome (LDS) is a rare life-threatening condition, with autosomal-dominant inheritance, which is caused by heterozygous mutations in the genes encoding transforming growth factor-beta receptors 1 and 2. It is characterized by a triad of tortuous arteries and aortic aneurysms, cleft palate or bifid uvula, and hypertelorism. We present the case of a 15 year old patient with LDS that was surgically evaluated and treated in our institution by valve-sparing aortic root replacement surgery, using the modified David's reimplantation technique. Management of this case and possible surveillance options for LDS patients are discussed.

## PATIENT DESCRIPTION

A 15 year old Caucasian girl was admitted to our hospital for planned aneurysm repair surgery. She had initially been diagnosed with Marfan syndrome in childhood. Since then she has undergone bi-annual echocardiography follow-up. At the age of 11, 4 years before her current presentation to our department, she underwent renewed genetic investigation and was diagnosed with LDS. Since then she has been under surveillance at our outpatient clinic and treated with beta-blockers. The patient is developing normally and does not clinically

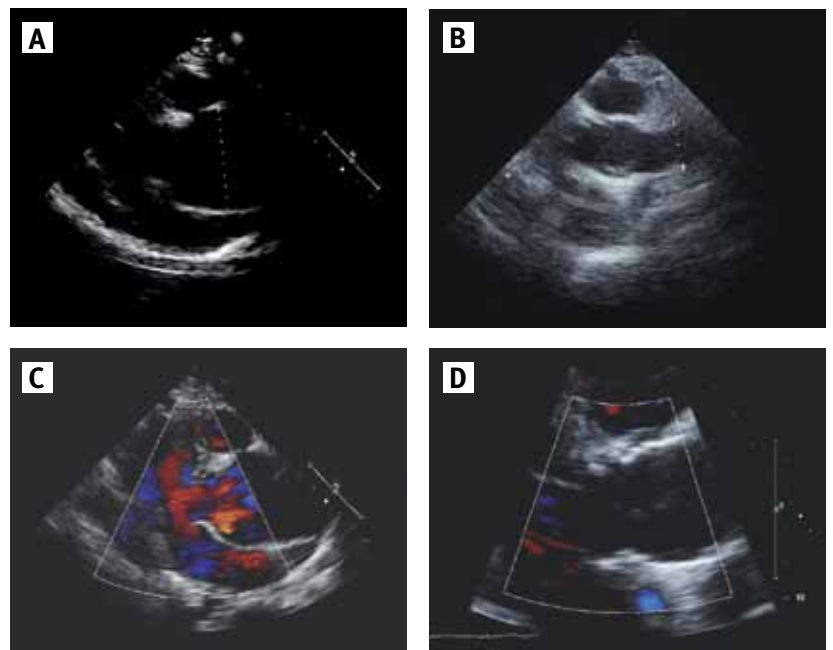
exhibit the full stigmata of the syndrome. She is restricted in physical activity, corresponding with New York Heart Association (NYHA) class II. Indication for surgery was aortic root dilatation of 48 mm and proximal ascending aorta dilatation of 53 mm. Compared with previous echocardiographic examinations, there was a progressive dilatation of the aortic root and the proximal ascending aorta of 11 mm and 19 mm respectively over the past 2 years. These findings were also verified by computed tomography (CT) examination. Left ventricular ejection fraction (LVEF) was 60%, the aortic valve was tri-leaflet with mild to moderate aortic regurgitation,

and mild tricuspid regurgitation was also noted.

David's valve-sparing aortic root surgery was applied using a Valsalva 28 mm Dacron graft. The intraoperative transesophageal echocardiography (TEE) did not show aortic regurgitation. The postoperative course was uneventful and the patient was discharged 6 days after surgery.

Follow-up echocardiography 4 weeks after surgery revealed normal aortic root and sinuses (34 mm), normal proximal ascending aorta (34 mm), normal left ventricular structure and function (LVEF 60%), and minimal aortic, mitral and tricuspid regurgitation [Figure 1].

**Figure 1.** Pre- and postoperative echocardiography: **[A]** Preoperative: long-axis parasternal view. **[B]** Postoperative: long-axis parasternal view. **[C]** Preoperative: Doppler imaging of regurgitation across the aortic valve. **[D]** Postoperative: Doppler imaging of regurgitation across the aortic valve



\*The first two authors contributed equally to this manuscript

**COMMENT**

The patient presented with LDS, proximal ascending aortic aneurysm and aortic root dilatation. Subsequently, she developed aortic insufficiency due to sinotubular junction dilation, which pulls the cusps apart, and exhibited symptoms correlating with NYHA II. LDS has autosomal-dominant inheritance with variable penetrance and is caused by heterozygous mutations in the genes encoding transforming growth factor-beta receptors 1 and 2 (*TGFBR1* and *TGFBR2*, respectively). The severity of the clinical presentation in these patients is predictive of the outcome [1]. These patients may present with other features, such as velvety and translucent skin, craniosynostosis, malar hypoplasia, retrognathia, blue sclera, patent ductus arteriosus, abnormal skeletal features, dural ectasia, atrial septal defects, developmental delay, cervical spine abnormalities, and joint laxity. Mutations in either *TGFBR1* or *TGFBR2* predispose patients to particularly aggressive vascular disease with a median and mean age of death at 37 and 26 years, respectively.

The leading cause of death is thoracic aortic dissection, followed by cerebral bleeding [1]. Patients with LDS tend to develop aneurysms of other vessels (53%), requiring annual total body magnetic resonance imaging (MRI) screening. Patients with LDS should also be advised of and evaluated for other life-threatening manifestations of the disease, including cervical spine instability, spontaneous or traumatic organ rupture, and catastrophic complications of pregnancy. In the original 2006 study by Loeys and Dietz [1], 6 of the 12 women with LDS who became pregnant had a major complication either during pregnancy or in the immediate postpartum period: aortic dissection in four and uterine rupture in two.

In general, the diameter above which repair is recommended in other aortic root dilatation diseases (e.g., Marfan syndrome) is 50 mm [1]. However, patients with LDS tend to experience aortic dissections at smaller aortic diameters, less than 50 mm, which has led to a stricter approach towards

these patients in the ACC/AHA/AATS 2010 guidelines for the diagnosis and management of patients with thoracic aortic disease. According to these guidelines, surgical repair is recommended in LDS patients at an aortic diameter of  $\geq 42$  mm by TEE (internal diameter) or  $\geq 44$ -46 mm by CT/MRI (external diameter). In addition to these guidelines, taking into consideration the patient's lean body weight (48 kg) and short height (152 cm), the rationale to operate was clear.

Conventionally, surgical treatment for patients with connective tissue disorders and aneurysm or dissection involving the ascending aorta has been replacement of the aortic root and valve (Bentall and De Bono procedures) with a mechanical or bioprosthetic valve inserted into a Dacron graft and attached to the aortic annulus. Over time, composite valve graft has become a durable low risk operation [2]. On the other hand, some patients have complications associated with prosthetic valves, which include valve obstruction and endocarditis for all valve types, thromboembolism, and need for life-long oral anticoagulants in case of mechanical valves, and a high rate of structural failure with biological or bioprosthetic valves.

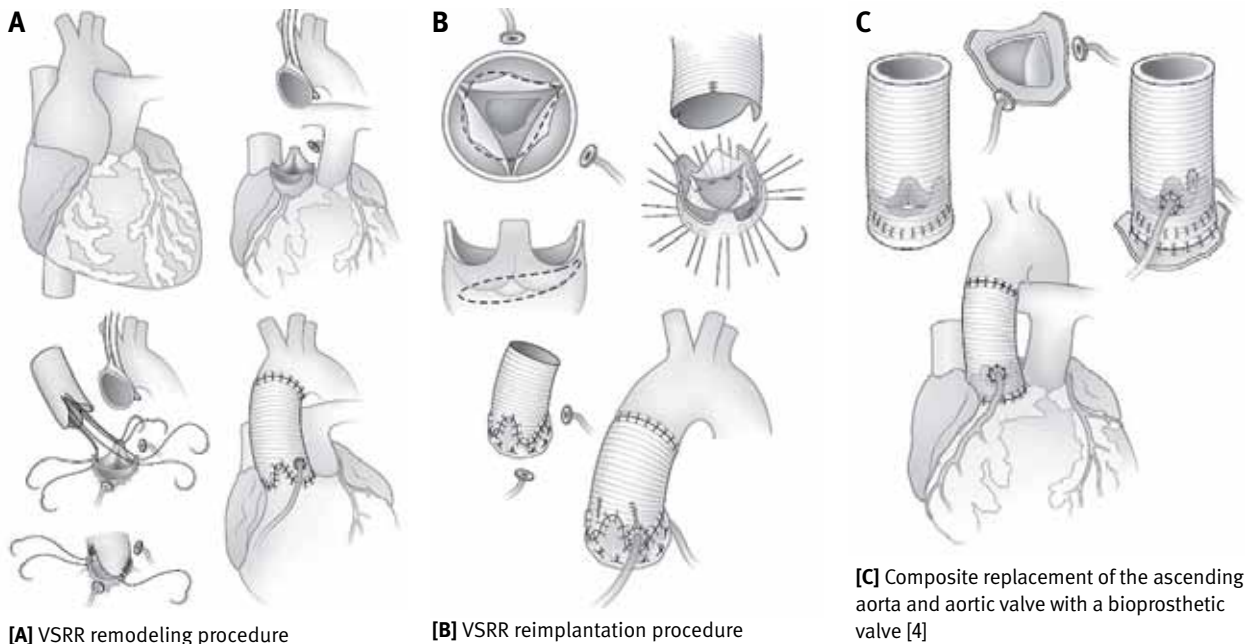
Another option gaining popularity for those wishing to avoid anticoagulation is valve-sparing aortic root replacement (VSRR). In a 2011 review from Johns Hopkins Hospital, relative contraindications for VSRR included marked leaflet fenestration and asymmetry, acute aortic dissection in unstable patients, giant root with marked leaflet irregularities, and bicuspid aortic valves with extensive calcification, severe prolapse, marked fenestrations, or a combination of these anomalies [3]. None of these, however, was present in our patient. In the same study, there were no operative or late deaths, no thromboembolic events, and no endocarditis at midterm follow-up.

VSRR operations can be subdivided into two general groups: the David "reimplantation" procedure and the Yacoub "remodeling" procedure [2]. In the remodeling technique (Yacoub procedure), the abnormal sinuses are resected and the

Dacron graft is tailored to recreate three neo-sinuses and then sutured to the remaining aortic wall and annulus. This technique is quicker (compared to the reimplantation technique), saves one suture line, and requires far less extensive dissection and mobilization of the aortic root. An advantage of this approach is that the graft billows, mimicking the natural sinuses of Valsalva, allowing more natural leaflet motion and theoretically reducing cusp-closing stresses, thereby enhancing long-term valve durability. There are two drawbacks to a remodeling procedure: a) absence of fixation of the aortic annulus, which predisposes to postoperative annular dilatation and recurrent aortic regurgitation; and b) two (instead of one) exposed aortic suture lines, which predisposes to bleeding [2]. Indeed, the incidence of postoperative bleeding is higher after the Yacoub procedure, rendering it less predictable than the reimplantation technique, especially in patients with connective tissue disorders. The reimplantation technique (David procedure) can be distinguished from the remodeling technique by use of a third aortic suture line. The abnormal sinuses are resected and the intact valve, commissures and aortic annulus are then sutured inside the graft, which is "necked down" at both the bottom and top ends to create pseudosinuses [Figure 2]. This technique gives the surgeon unlimited flexibility in terms of the sizes for making the annulus, neo-sinuses, and sinotubular ridge, as well as the "height" of the neo-sinuses. Therefore, since they can be individualized for each patient [2] this method is preferred by most surgeons. Furthermore, this strategy is believed to prevent dilatation because the entire aortic valve is secured inside the graft. In both procedures, after the graft has been successfully attached to the aortic root, the other end of the graft is attached to the aorta, and the coronary arteries are reimplanted into holes in the appropriate positions on the graft.

Over the course of the last years, our department has become a national referral center for patients suffering from thoracic

**Figure 2.** Aortic root replacement



aortic aneurysms and has gained extensive experience in this field. Since 2004, we have performed 81 VSRR surgeries, using the David reimplantation technique. Sixty-five of the patients (80%) were males; their mean age at the time of surgery was 45; 30 of these patients (37%) were diagnosed with Marfan syndrome. This was the first case of LDS in our practice.

Due to the young age of our patient we performed a valve-sparing procedure in order to avoid the aforementioned complications associated with prosthetic aortic valve aortic regurgitation and the need for life-long oral anticoagulants, especially given her possible desire to conceive in the future. Moreover, our goal was to select a procedure that would predict better durability, believing that this patient has a higher risk for progression of the aortic root dilata-

tion due to her syndrome. Therefore, we chose the reimplantation-type procedure which, although more difficult to perform, would probably prevent future postoperative dilatation of the aortic annulus.

In conclusion, the long-term results of aortic valve-sparing operations are excellent. In a 20 year analysis of outcomes in more than 300 patients at the Toronto General Hospital, the overall freedom from reoperation in the aortic valve at 10, 15 and 20 years was 97.1%, 94.2% and 94.2% respectively. In young patients with inherited connective tissue disorders, reimplantation of the aortic valve is preferred because it provides more stable aortic valve function. Remodeling of the aortic root is ideal for older patients with normal aortic annulus and primarily ascending aortic aneurysms [5].

**Correspondence**

**Dr. E. Raanani**  
 Head, Dept. of Cardiac Surgery, Sheba Medical Center, Tel Hashomer 52621, Israel  
**Phone:** (972-3) 530-2710  
**Fax:** (972-3) 302-410  
**email:** ehud.raanani@sheba.health.gov.il

**References**

1. Loeys BL, Schwarze U, Holm T, et al. Aneurysm syndromes caused by mutations in the TGF-beta receptor. *N Engl J Med* 2006; 355: 788-98.
2. Miller DC. Valve-sparing aortic root replacement in patients with the Marfan syndrome. *J Thorac Cardiovasc Surg* 2003; 125 (4): 773-8.
3. Patel ND, Cameron DE, Vricella LA, et al. Valve-sparing aortic root replacement in Loeys-Dietz syndrome. *Ann Thorac Surg* 2011; 92: 556-61.
4. David TE. Surgery of the aortic root and ascending aorta. In: Selke FW, del Nido PJ, Swanson SJ, Sabiston and Spencer's Surgery of the Chest. 8th edn. Philadelphia: Saunders Elsevier, 2010: 1032-34.
5. David TE. Aortic valve sparing operations: outcomes at 20 years. *Ann Cardiothorac Surg* 2013; 2 (1): 24-9.

**“On stage, I make love to 25,000 different people, then I go home alone”**

Janis Joplin (1943-1970), American singer-songwriter

**“All progress has resulted from people who took unpopular positions”**

Adlai Stevenson (1900-1965), American politician and diplomat