

# Use of Low Dose Computed Tomography with 3D Reconstructions for the Prenatal Evaluation of Suspected Skeletal Dysplasia

Yael Adler-Levy MD<sup>1</sup>, Simcha Yagel MD<sup>2</sup>, Michael Nadjari MD<sup>2</sup>, Yaakov Bar-ziv MD<sup>1</sup>, Natalia Simanovsky MD<sup>1</sup> and Nurith Hiller MD<sup>1</sup>

Departments of <sup>1</sup>Radiology and <sup>2</sup>Obstetrics & Gynecology, Hadassah University Hospital, Mount Scopus, and Hebrew University Medical School, Jerusalem, Israel

**ABSTRACT:** **Background:** Sonographic evaluation of congenital skeletal dysplasias is often challenging. Ultrasound may be limited in demonstrating the skeleton and may overlook specific signs of skeletal abnormality. Computed tomography (CT) with 3D reconstruction was proposed as an aid in the diagnosis of skeletal dysplasias.

**Objectives:** To describe our experience with 3D-CT imaging for the evaluation of suspected skeletal dysplasias.

**Methods:** The study group comprised 20 pregnant women carrying 22 fetuses, referred for further evaluation by CT following sonographic suspicion of fetal skeletal dysplasia at 17–39 weeks of gestation. Examinations were performed using various CT protocols. Radiation exposure was decreased during the study period, with eventual lowering of the dose to 1–3 mSv. Meticulous review of the skeleton and long bone measurements were performed on 3D reconstructions. For cases of pregnancy termination, the postmortem diagnosis was compared retrospectively with the CT findings.

**Results:** Very low dose CT protocols provided excellent diagnostic images. Of 22 fetuses suspected of having skeletal dysplasia on ultrasound, 8 were found by CT to be dysplastic and in 7 the pregnancy was terminated. Postmortem findings, when available, concurred with the CT diagnosis. The remaining 14 fetuses within this cohort were found to be normal according to CT and were carried to term.

**Conclusions:** 3D-CT may be a valuable complimentary imaging tool to ultrasound for the diagnosis of skeletal dysplasias. With low dose protocols, this examination is relatively safe, and in the appropriate clinical context may assist in making difficult decisions prenatally.

*IMAJ 2015; 17: 42–46*

**KEY WORDS:** computed tomography (CT), skeletal dysplasia, prenatal diagnosis, 3D reconstruction, 3D-CT

are exceedingly rare, with prevalence estimated at 3–4 per 10,000 newborns.

Prenatal ultrasound is currently the accepted initial modality for fetal assessment. The sensitivity of two-dimensional (2D) ultrasound for the detection of fetal skeletal abnormalities is approximately 60% [2,3]. Recent studies have found that three-dimensional (3D) ultrasound is superior to 2D ultrasound for depicting and characterizing skeletal dysplasia [4]; thus, it is currently accepted as a complementary technique to 2D ultrasound, especially in complex cases.

However, experience is needed in 3D ultrasound data acquisition, analysis, and navigation in volume reconstruction. Moreover, equivocal ultrasound findings, the rarity of these conditions, variable phenotypes, and lack of a precise genetic diagnosis in many cases often make prenatal diagnosis challenging.

Magnetic resonance imaging (MRI) is a lengthy examination and thus limited for in utero evaluation of skeletal dysplasia due to fetal movement during the scan. Accurate diagnosis of skeletal dysplasia is of clinical importance as these abnormalities entail severe disability, may be accompanied by other malformations, and are sometimes lethal. The findings may affect management or enable prognostic evaluation.

Recent studies have shown that the use of CT with 3D reconstruction may improve diagnostic accuracy for skeletal dysplasia as well as provide information and diagnostic characteristics that are supplementary to findings on 3D ultrasound [5–8]. In this study we present our experience with the use of CT with 3D reconstruction for prenatal evaluation of suspected skeletal dysplasia and suggest a low dose CT protocol for performing the examination.

## PATIENTS AND METHODS

We retrospectively reviewed the clinical files and imaging data of women referred to our Diagnostic Imaging Center during pregnancy between January 2009 and May 2012 for helical CT evaluation when 3D ultrasound raised suspicion of skeletal dysplasia. We included all patients with suspected skeletal dysplasia referred for prenatal CT by the treating physician. All patients were counseled about the potential biological risk associated

The skeletal dysplasias constitute a heterogeneous group of disorders, some profoundly affecting growth and development of the musculoskeletal system [1]. The current classification includes more than 150 different entities, most of which

with exposure to ionizing radiation, and all signed an informed consent for the CT examination.

Ultrasound examinations were performed by obstetricians proficient in prenatal ultrasound. In all our cases repeated sonographic results were equivocal for skeletal dysplasia. CT examinations were performed on one of three scanners: 16-slice (LightSpeed, GE HealthCare, Milwaukee, WI, USA) (n=10), 64-slice (Brilliance, Philips, Eindhoven, The Netherlands) (n=6), or 128-slice (Optima 660, GE HealthCare) (n=4).

The CT technique was not consistent in all examinations. In the earliest cases, which were referred with high sonographic suspicion of severe dysplasia and possible termination of pregnancy, higher virtually standard scan parameters were employed with higher radiation dose. With time and experience, lower dose protocols were adopted.

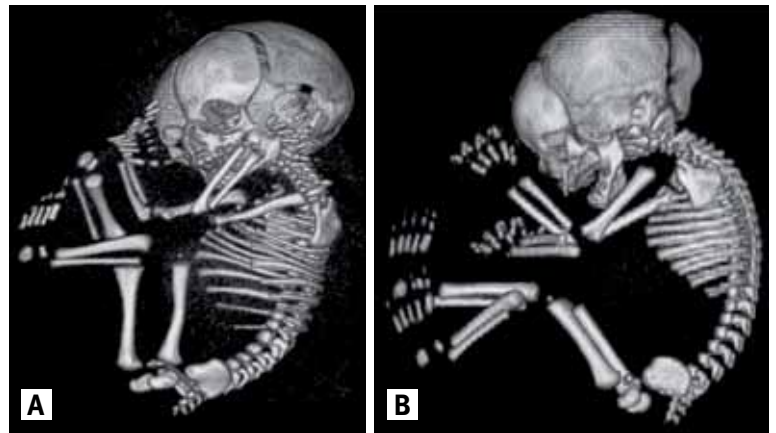
CT was performed starting with an abdominal scout view for precise scan planning and optimal limitation of the scan duration. The scan was performed craniocaudally and included only the uterus. Examinations were performed with 80–120 kV and 30–400 mAs. Slice thickness was either 1.25 mm or 0.75 mm, pitch was between 1 and 1.3, and rotation time was 0.5 sec. The CT dose index (CTDI) ranged between 2 and 10, and radiation exposure ranged from 0.7 to 10 mSv.

The first examination of a fetus with sonographic suspicion of encephalocele was associated with radiation exposure of 10 mSv and was performed with an older 16-slice GE machine. Radiation doses were reduced gradually; according to our standard protocol for patients of average build we use 80 Kv, automated 150 mAs, 0.5 sec rotation time, pitch 1 and slice thickness 1.25 mm. Using this protocol, later examinations were performed with radiation doses ranging from 0.7 to 1.2 mSv (CTDI 1.5–2) with good diagnostic acumen [Figure 1]. For patients with a higher body mass index, the same protocol is used but kilovoltage is increased to 100 and mAs to 150. This protocol is associated with average radiation exposure of approximately 3–3.5 mSv (CTDI 5–6). In three cases examined at earlier gestational ages (16, 17 and 24 weeks), when ossification is predicted to be limited, the same low dose protocol was used with radiation exposure of approximately 1 mSv. No diagnostic limitation was encountered.

CT volume data were transferred to an independent workstation (Advantage Windows 4.5, GE HealthCare or MxView, Philips). Post-processing, including coronal and sagittal multiplanar reconstructions, maximal intensity projection and 3D (volume-rendering) reconstruction, was performed with digital removal of the maternal pelvic bones and ribs, using dedicated software. Images were reviewed by two expert radiologists with more than 20 years experience in abdominal and musculoskeletal radiology (N.H. and Y.B.Z.).

Multiplanar reconstructions were reviewed in standard abdominal and bone windows. 3D reconstructions were rotated

**Figure 1.** Prenatal 3D-CT at gestational week 35 in two different women



**[A]** A 35 year old woman scanned with a higher radiation dose, contrast-to-dose index (CTDI) 10, 7 mSv

**[B]** A 29 year old woman scanned with lower dose (CTDI 4, 1.9 mSv). Both protocols provided good diagnostic acumen

in all planes. Maximal skull biparietal diameters as well as maximal length of long bones, including the femur, tibia, fibula, humerus, radius and ulna, were carefully measured bilaterally, using workstation software. The entire spinal column, including vertebral bodies and posterior elements, as well as rib shape and number were assessed. The shape of the skull, nasal bridge, mandible, thorax, iliac bones and long bones were also meticulously evaluated. Humerus-to-ulna and femur-to-tibia ratios were calculated for each fetus to exclude possible rhesomelic dwarfism. The longest measurement of each long bone was compared with standard gestational age-adjusted ultrasound measurements to rule out micromelia. The CT findings were then compared with the ultrasound results. In cases of pregnancy termination, the post-mortem diagnosis was compared retrospectively to findings from the fetal CT study. In cases carried to term, CT and ultrasound results were compared to the neonatal physical examination.

## RESULTS

The study included 20 women carrying 22 fetuses (maternal age 39–22 years, mean 31). Examinations were performed during gestational weeks 16–39; the median gestational age at evaluation was 31 weeks.

Indications for prenatal CT included suspected short limb dysplasia or rhesomelia (femur length < 3rd percentile) on repeated ultrasound examinations (n=12), suspected limb dysplasia (n=2), suspected spine deformity (n=2), combined spine and limb deformity (n=1), suspected skull defect (n=2), and a suspicion of osteogenesis imperfecta based on the finding of an in utero fracture of the tibia (n=1).

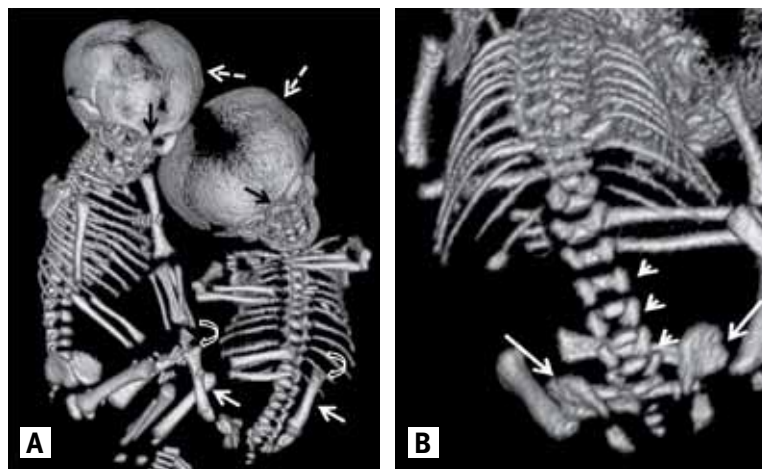
Table 1 summarizes the case series. All CT examinations were diagnostic, including studies of the three fetuses inves-

**Table 1.** Summary of findings in our patients

Patient no.	GA (wk)	Findings at prenatal ultrasound	Findings at prenatal CT	Radiation	Outcome
1	34	Alobar holoprosencephaly, right skull defect	Skull defect with a large encephalocele	10 mSv	TOP, pathology confirmed
2	37	Suspected osteogenesis imperfecta	Fractured tibia, normal skeleton	6 mSv	Full term, alive and well
3	29	Right skull defect, suspected encephalocele, oligohydramnios, foot deformity	No skull defect, oligohydramnios, foot deformity	7 mSv	TOP, Potter syndrome, no skull defect
4	17	Suspected hemivertebra, hypoplastic left thigh, calf and foot bones	D9–L2 hemivertebra with rib deformities and hypoplastic left thigh, calf and foot bones	7 mSv	TOP, pathology confirmed
5	34	Suspected vertebral anomaly	D10 hemivertebra	6 mSv	TOP, pathology confirmed
6	39	Short limb dysplasia (P < 3)	Normal fetus (P < 3)	6 mSv	Full term, alive and well
7	35	Short limb dysplasia (P < 3)	Normal fetus (P < 3)	7 mSv	Full term, alive and well
8	33	Twin 1, suspected achondroplasia	Achondroplasia	5.5 mSv	Selective feticide, achondroplasia confirmed
9	33	Twin 2, normal?	Normal fetus	5.5 mSv	Full term, alive and well
10	33	Twin 1, short limb dysplasia (P < 3)	Normal fetus (P < 3)	1.2 mSv	Full term, alive and well
11	33	Twin 2, short limb dysplasia (P < 3)	Normal fetus (P < 3)	1.2 mSv	Full term, alive and well
12	34	Short limb dysplasia (P < 3)	Normal fetus (P < 3)	2 mSv	Full-term, alive and well
13	34	Short limb dysplasia (P < 3)	Normal fetus (P < 3)	2 mSv	Full term, alive and well
14	24	Caudal regression syndrome	Caudal regression syndrome	2 mSv	TOP, pathology confirmed
15	33	Short limb dysplasia (P < 3)	Normal fetus (P < 3)	0.75 mSv	Full term, alive and well
16	32	Short limb dysplasia (P < 3)	Normal fetus (P < 3)	0.7 mSv	Full term, alive and well
17	36	Short limb dysplasia (P < 3)	Normal fetus (P < 3)	3 mSv	Full term, alive and well
18	32	Short limb dysplasia (P < 3)	Normal fetus (P < 3)	3 mSv	Full term, alive and well
19	28	Short limb dysplasia (P < 3)	Normal fetus (P < 3)	0.9 mSv	Full term, alive and well
20	35	Short limb dysplasia (P < 3)	Normal fetus (P < 3)	1.9 mSv	Full term, alive and well
21	31	Dysplastic left calf	Hypoplastic left calf bones	2.2 mSv	Full term, pathology confirmed
22	16	Bilateral curved short calf bones	Bilateral curved short calf bones	1.1 mSv	TOP, pathology confirmed

GA = gestational week, TOP = termination of pregnancy, P < 3 = lower than the 3rd percentile

**Figure 2. [A]** Prenatal 3D-CT of a twin pregnancy (gestational week 33, 5.5 mSv) in a 27 year old woman (cases 8 and 9, Table 1). Note discrepancy in size between the fetuses. The shorter twin has a larger biparietal diameter (dashed arrows) and depressed nasal bridge as compared to the normal twin (black arrows). Shorter femoral bones (solid white arrows) with metaphyseal abnormality (curved arrow) are also revealed in the abnormal fetus **[B]** 3D-CT of the abnormal fetus revealing squared iliac bones (arrows) and reversed tapering of the intrapedicular distance of lumbar vertebrae (arrowheads)



tigated relatively early in pregnancy, at gestational weeks 16, 17 and 24.

Twelve women, including 2 carrying twins (a total of 14 fetuses), were referred for evaluation of suspected short limb dysplasia. CT ruled out disease in 13 of these fetuses where long bones were found to be within normal limits (> 3rd percentile); all were normal upon delivery at term.

In one twin pregnancy (cases 8-9), one fetus was suspected of having short limb dysplasia (case 8). A diagnosis of achondroplasia was made at CT based on large biparietal diameter, small nasal bridge, square iliac bones, and reverse tapering of vertebral interpedicular diameter, as well as humeral-to-ulnar and femoral-to-tibial ratios < 1 [Figure 2]. Prenatal genetic examination in case 8 revealed mutations in the *FGFR3* gene. One fetus was referred due to suspicion of osteogenesis imperfecta (case 2), but this was ruled out and a normal baby was delivered at term.

In the seven remaining fetuses, various severe skeletal malformations were suspected on 3D ultrasound. The following CT diagnoses were made: large skull defect with encephalocele (case 1); severe oligohydramnios with foot deformity, without skull defect (case 3); caudal regression syndrome (case 14); D10 hemivertebra with unilateral absent rib at

the same level (case 5); unilateral hypoplastic left tibia and fibula (case 21); and bilateral hypoplastic curved tibias and fibulas with combined limb and spinal anomalies, including severe scoliosis due to D9 to L2 hemivertebra with missing and fused ribs on the same side and levels, as well as proximal focal femoral deficiency (case 4) [Figure 3]. CT diagnoses significantly increased the physician's level of confidence when presenting management options to the parents of these fetuses. Six of these pregnancies were terminated. The parents of one fetus with unilateral hypoplastic left tibia and fibula were informed of the implications of the dysplasia, but they decided to bring the pregnancy to term (case 21).

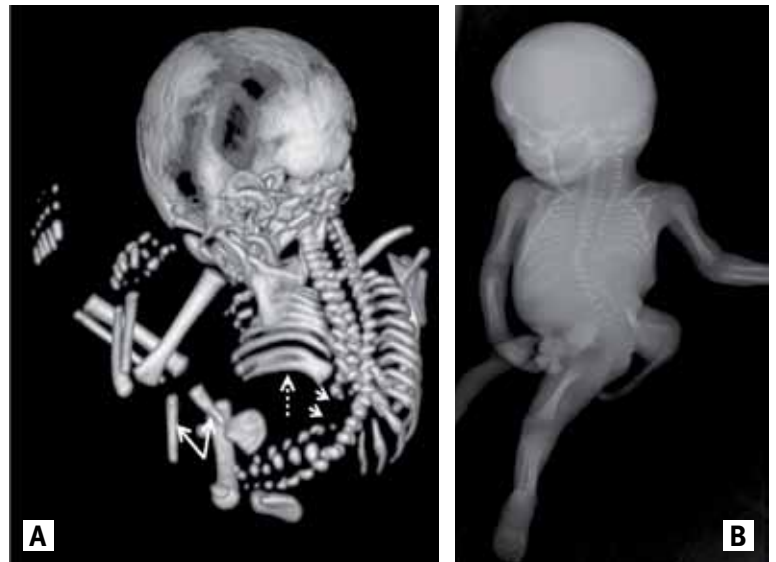### DISCUSSION

Prenatal diagnosis of skeletal dysplasia poses both a technical and intellectual challenge for the treating physician in a sensitive clinical setting. The rarity and diversity of these pathologies, the limited visualization using 2D and 3D ultrasound techniques, and the possibility that parents may wish to terminate a pregnancy with a severe dysplasia indicate the need for an accurate and definitive diagnostic tool.

Previous case series described the use of 3D helical CT for the diagnosis of hypochondroplasia [9], chondrodysplasia punctata [10], proximal focal femoral deficiency [11], long bone aplasia [12], thanatophoric dysplasia [13], and Apert syndrome [14]. A review of the literature revealed only four small series describing the added value of 3D-CT in the assessment of skeletal dysplasia. The first series described by Ruano et al. [7] included six patients, a series by Cassart et al. [5] reviewed 11 patients, a series of six patients was presented by Ulla et al. [8], and an additional and more recent study by Myazaki et al. [6] included 17 pregnant women. Both Ruano et al. [7] and Cassart et al. [5] showed superior diagnostic results using CT scanning with 3D reconstructions, as compared with standard prenatal 2D and 3D ultrasound, but the authors did not describe how these findings changed prenatal management. Ulla and co-authors [8] presented cases where CT scanning enabled definitive diagnosis following an inconclusive ultrasound examination. Myazaki et al. [6] showed that the capability of fetal CT to delineate the skeleton was comparable to the postnatal skeletal survey, and CT altered prenatal management in 59% of the cases in their series.

Our results are in concordance with these earlier studies. CT proved important, especially in cases of suspected micromelic dysplasia. In 13 fetuses, CT diagnosis ruled out skeletal dysplasia and profoundly affected management with favorable results. CT has an evident advantage over ultrasound for anatomic evaluation of the fetal skeleton, as the reconstructed 3D image can be rotated in any plane, allowing meticulous measurement of the maximal length of the long bones free of the fetal motions that may limit sonographic evaluation. Unlike ultrasound, CT measurements are not distance dependent; hence, they may be

**Figure 3. [A]** Prenatal 3D-CT at gestational week 17 in a 29 year old woman (case 4, Table 1) demonstrates scoliosis, D9–L2 hemivertebra (arrowheads), rib fusion on the left hemithorax (dashed arrow), and short hypoplastic bones in the left lower limb (solid arrows). The diagnosis of proximal focal femur dysplasia was confirmed genetically **[B]** X-ray of the fetus taken after birth showing the same findings



more accurate. CT is less vulnerable to image degradation by maternal body habitus, and obviates problems of acoustic shadowing seen on ultrasound. With CT, only ossified bone can be demonstrated, while on ultrasound both ossified and chondral non-ossified bone is included in measurements. Therefore, the use of standard ultrasound percentile charts for CT-based measurements is questionable. However, since CT examinations during pregnancy are relatively rare, CT-dedicated growth charts are not likely to be created in the near future.

CT is extremely helpful in cases of multifetal pregnancies where sonographic differentiation and measurements of individual fetuses can be difficult. In cases where ultrasound was highly suspicious for substantial skeletal malformation, a confident diagnosis was achieved with CT, enabling easier decision making with respect to pregnancy termination or continuation.

The primary concern regarding CT in pregnancy is fetal radiation exposure. In 2008, the American College of Radiology (ACR) compiled practice guidelines for imaging pregnant patients and provided an approximation of fetal risk at various gestational ages with differing radiation exposure. The ACR suggested that theoretical risks are not likely at doses below 100 mGy (100 mSv) [15]. As a rule, radiation exposure should be minimized to a level that is 'as low as reasonably achievable' (ALARA) without compromising diagnostic capability. Demonstration of bony structures with CT does not usually require high radiation dose protocols. Low dose radiation protocols entail reducing the scan range and field of view to

the minimum necessary, increasing the pitch to  $> 1$ , decreasing kilovoltage (especially for small-sized women), decreasing tube current, and using automated mA modulation. New-generation CT machines possess powerful reconstruction algorithms that reduce image noise, allowing reduction of the tube current or voltage required for the examination.

In our experience, radiation exposure can be reduced to as low as 1–2 mSv, especially in slender patients, without compromising image quality. We found this holds true even at relatively young gestational ages where skeletal ossification is at an early stage. This level of radiation exposure is acceptable and is equivalent to a single abdominal X-ray or 9 months exposure to natural environmental radiation.

Our study has a number of limitations, most of them inherent to the nature of the study. The series is relatively small. Moreover, since many obstetricians are not familiar with the role that helical CT can play in prenatal diagnosis of skeletal dysplasia, CT referrals for this indication are sparse and it is difficult to obtain a larger series. CT examinations were performed with various scan protocols on three different machines. The optimal protocol we suggest is suitable for new-generation CT machines that allow very low radiation exposure.

In conclusion, repeated ultrasound examinations are the primary tool for prenatal diagnosis of skeletal malformations. Helical CT with 3D reconstruction may serve as an important adjunctive to prenatal 2D and 3D ultrasound for the evaluation of possible skeletal dysplasia and may play an important role in decision making in problematic cases.

#### Acknowledgments

The authors wish to thank Sara Cohen and Shifra Fraifeld, research associates in the Departments of Obstetrics and Gynecology and Radiology, for their contribution to the preparation of this manuscript.

#### Correspondence

Dr. N. Hiller

Dept. of Radiology, Hadassah University Hospital, Mount Scopus, P.O. Box 24035, Jerusalem 91240, Israel

email: hiller@netvision.net.il

#### References

1. International nomenclature and classification of the osteochondrodysplasias (1997). International Working Group on Constitutional Diseases of Bone. *Am J Med Genet* 1998; 79 (5): 376-82.
2. Doray B, Favre R, Viville B, Langer B, Dreyfus M, Stoll C. Prenatal sonographic diagnosis of skeletal dysplasias. A report of 47 cases. *Ann Genet* 2000; 43 (3-4): 163-9.
3. Parilla BV, Leeth EA, Kambich MP, Chilis P, MacGregor SN. Antenatal detection of skeletal dysplasias. *J Ultrasound Med* 2003; 22 (3): 255-8; quiz 59-61.
4. Krakow D, Williams J 3rd, Poehl M, Rimoin DL, Platt LD. Use of three-dimensional ultrasound imaging in the diagnosis of prenatal-onset skeletal dysplasias. *Ultrasound Obstet Gynecol* 2003; 21 (5): 467-72.
5. Cassart M, Massez A, Cos T, et al. Contribution of three-dimensional computed tomography in the assessment of fetal skeletal dysplasia. *Ultrasound Obstet Gynecol* 2007; 29 (5): 537-43.
6. Miyazaki O, Nishimura G, Sago H, Horiuchi T, Hayashi S, Kosaki R. Prenatal diagnosis of fetal skeletal dysplasia with 3D CT. *Pediatr Radiol* 2012; 42 (7): 842-52.
7. Ruano R, Molho M, Roume J, Ville Y. Prenatal diagnosis of fetal skeletal dysplasias by combining two-dimensional and three-dimensional ultrasound and intrauterine three-dimensional helical computer tomography. *Ultrasound Obstet Gynecol* 2004; 24 (2): 134-40.
8. Ulla M, Aiello H, Cobos MP, et al. Prenatal diagnosis of skeletal dysplasias: contribution of three-dimensional computed tomography. *Fetal Diagn Ther* 2011; 29 (3): 238-47.
9. Bonnefoy O, Delbosc JM, Maugey-Laulom B, Lacombe D, Gaye D, Diard F. Prenatal diagnosis of hypochondroplasia: three-dimensional multislice computed tomography findings and molecular analysis. *Fetal Diagn Ther* 2006; 21 (1): 18-21.
10. Miyazaki O, Nishimura G, Sago H, Watanabe N, Ebina S. Prenatal diagnosis of chondrodysplasia punctata tibia-metacarpal type using multidetector CT and three-dimensional reconstruction. *Pediatr Radiol* 2007; 37 (11): 1151-4.
11. Otera Y, Morokuma S, Yumoto Y, et al. Prenatal three-dimensional images of proximal focal femoral deficiency produced by helical computed tomography. *Fetal Diagn Ther* 2009; 25 (3): 349-53.
12. Sohda S, Hamada H, Oki A, Iwasaki M, Kubo T. Diagnosis of fetal anomalies by three-dimensional imaging using helical computed tomography. *Prenat Diagn* 1997; 17 (7): 670-4.
13. Tsutsumi S, Sawai H, Nishimura G, Hayasaka K, Kurachi H. Prenatal diagnosis of thanatophoric dysplasia by 3-D helical computed tomography and genetic analysis. *Fetal Diagn Ther* 2008; 24 (4): 420-4.
14. Mahieu-Caputo D, Sonigo P, Amiel J, et al. Prenatal diagnosis of sporadic Apert syndrome: a sequential diagnostic approach combining three-dimensional computed tomography and molecular biology. *Fetal Diagn Ther* 2001; 16 (1): 10-12. American College of Radiology. ACR practice guideline for imaging pregnant or potentially pregnant adolescents and women with ionizing radiation. Reston, VA: American College of Radiology; 2008. [WWW document]. URL [http://www.acr.org/~media/ACR/Documents/PGTS/guidelines/Pregnant\\_Patients.pdf](http://www.acr.org/~media/ACR/Documents/PGTS/guidelines/Pregnant_Patients.pdf)