

A Case Series of Congenital Hepatic Hilar Cyst: Recommendations for Diagnosis and Management

Yaniv Berger MD¹, Riccardo A. Superina MD¹, Andrew Zbar MD¹, Nora Balint-Lahat MD², Nir Horesh MD¹ and Ron Bilik MD¹

¹Department of Pediatric Surgery, Safra Children Hospital and ²Department of Pathology, Sheba Medical Center, Tel Hashomer, affiliated with Sackler Faculty of Medicine, Tel Aviv University, Tel Aviv, Israel

ABSTRACT: **Background:** Congenital hepatic hilar cysts are rare. Some are simple and do not require intervention, but some biliary cystic malformations impose the risk of morbidity and mortality.

Objectives: To assess a series of five patients presenting with congenital hepatic hilar cysts.

Methods: We retrospectively reviewed all cases presenting to our pediatric surgical service between January 2010 and December 2012 and found to have a congenital hepatic hilar cyst. Data regarding clinical, radiological, operative and pathological features were analyzed.

Results: Five children with congenital cyst of the hepatic hilum were identified; four of them were diagnosed prenatally. Four children had undergone surgical intervention: one with intrahepatic choledochal cyst, one with epidermoid cyst, and two with biliary atresia and an associated cyst of the common bile duct. In another case of choledochal cyst the treatment was conservative. All children except one had a good prognosis; one child with biliary atresia required liver transplantation.

Conclusions: The differential diagnosis of congenital hepatic hilar cyst includes a broad spectrum of pathologies. It is essential to diagnose biliary atresia as early as possible. Signs such as smaller cysts in association with a hypoplastic gallbladder and direct hyperbilirubinemia may be suggestive of biliary atresia.

IMAJ/2015; 17: 32–36

KEY WORDS: hepatic hilar cyst, biliary atresia, choledochal cyst, epidermoid cyst, Kasai porto-enterostomy

Congenital hepatic cysts are comparatively rare, but the rate of diagnosis during pregnancy is increasing due to the routine use of prenatal ultrasound [1]. The differential diagnosis of a solitary hepatic cyst includes simple cyst, choledochal cyst, biliary atresia, mesenchymal hamartoma, cystic tumors (including embryonal sarcoma, dermoid and teratoma), ciliated foregut cyst, and mesenchymal cysts [2]. Since most congenital hepatic cysts are parenchymal in origin and simple in nature (consisting of a basic cuboidal epithelium with peripheral loose connective tissue), many cases do not require specific treatment as they spontaneously regress over time [3]. Although there is

a broad differential diagnosis of congenital hepatic hilar cysts, it is imperative to differentiate these from associated cases of choledochal cysts with or without biliary atresia [4,5].

We report a series of five patients presenting with hepatic hilar cysts to our pediatric surgical service at the Safra Children Hospital. Their clinical and imaging features are described and recommendations regarding their clinical management are provided.

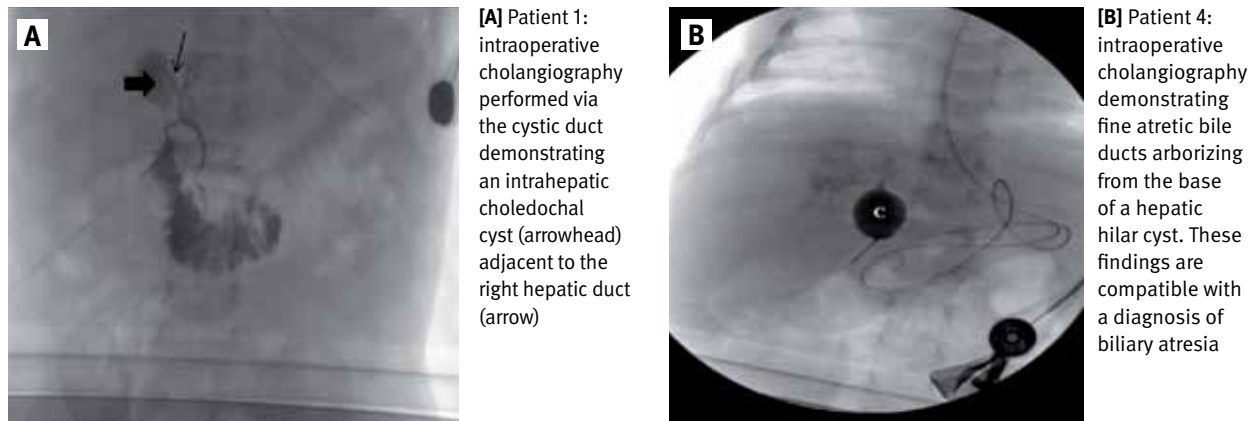
PATIENTS AND METHODS

All cases presenting to our pediatric surgical service between January 2010 and December 2012 and found to have a congenital hepatic hilar cyst were retrospectively reviewed. Data regarding clinical, radiological, operative and pathological features were analyzed. Five children with congenital cyst of the hepatic hilum were identified; four of them were diagnosed prenatally. Four children had undergone surgical intervention (at average age 6.3 ± 6.2 months) and in one case the treatment was conservative. All patients were operated on by the same surgical team. The median follow-up was 27 months (range 9–45 months). The Institutional Review Board of the local Hospital Ethics Committee approved the assessment of case studies. Table 1 presents a clinical summary of the cases.

PATIENT 1

A cystic lesion (maximal diameter 18 mm) at the hepatic hilum was detected on routine prenatal ultrasound performed in the third trimester. A full-term girl was born without hepatosplenomegaly. Postnatal ultrasound at 3 days demonstrated a 19 mm round cyst located anterior to the bifurcation of the portal vein without dilatation of the intra- or extrahepatic bile ducts and with a normal gallbladder; these findings were compatible with type II choledochal cyst. HIDA scan confirmed the diagnosis of an intrahepatic choledochal cyst with passage of the tracer into the cyst after 5 minutes. At age 7 months the patient underwent a laparotomy with excision of the intrahepatic choledochal cyst without need for bile duct reconstruction. The intraoperative findings confirmed a normal gallbladder, normal common bile duct, and 2 cm intrahepatic cyst located between the anterior and posterior branches of the right hepatic duct. Intraoperative

Figure 1. Intraoperative cholangiograms



C = cyst

cholangiography showed a fine communication between the cyst and the branches of the right hepatic duct [Figure 1]. Histology showed a benign cystic lesion with a fibrotic vascularized wall and no definitive epithelial lining. The child remains well and asymptomatic 2 years after surgery.

PATIENT 2

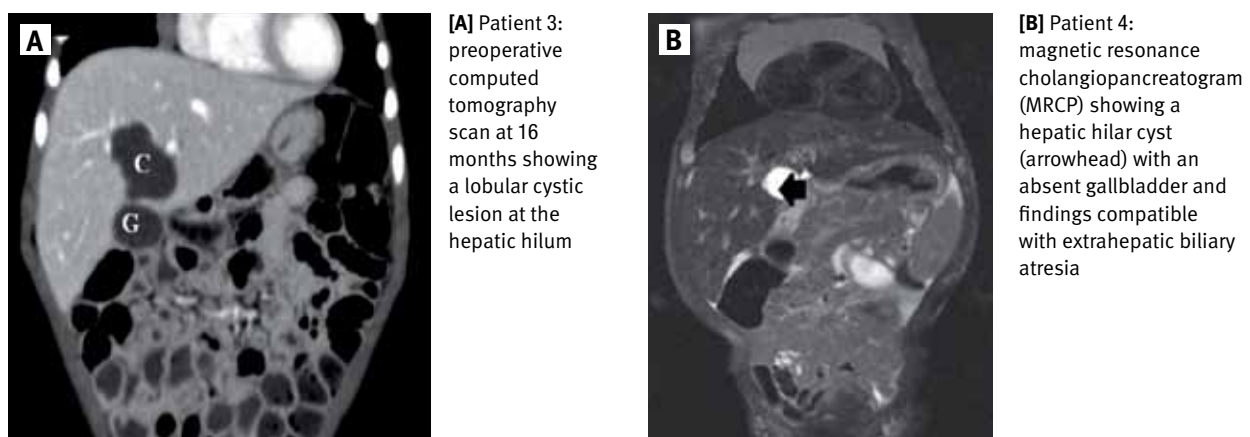
A 16 mm cyst at the hepatic hilum located posterior to a small gallbladder was detected on a routine prenatal ultrasound at the 29th gestational week. Magnetic resonance imaging at the 30th gestational week demonstrated a 14 mm hepatic hilar cyst connected to a small gallbladder with an irregular wall, findings suggestive of choledochal cyst. A full-term girl was born with normal bilirubin and liver enzymes. A postnatal ultrasound showed normal liver echogenicity without dilatation of the intra- or extrahepatic bile ducts; also depicted was a small

shrunken gallbladder and a 22 mm cyst of the hepatic hilum with a thin regular wall. The baby was discharged from hospital at the age of 5 days and was treated conservatively, at her parents' request. Serial ultrasound examinations demonstrated stable size of the cyst. She remains asymptomatic at 2 years follow-up and is scheduled to undergo elective surgery in early 2015.

PATIENT 3

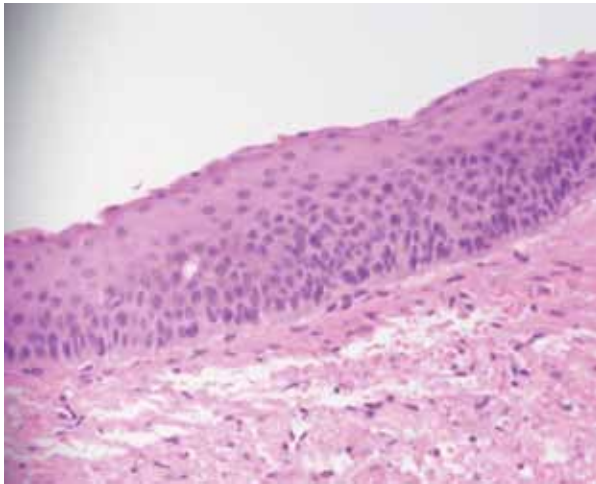
A 9 month old boy with a perinatal diagnosis of a hepatic cyst was born at full term and was asymptomatic with normal laboratory evaluation and development. Repeat ultrasound examination showed a lobular cystic lesion located at the hepatic hilum with a maximal diameter of 32 mm that contained echogenic sediment, raising the diagnosis of a choledochal cyst. Figure 2 shows a comparative computed tomography scan. HIDA scan showed non-filling of the cyst with the tracer and normal pas-

Figure 2. Cross-sectional studies



C = cyst, G = gallbladder

Figure 3. Hematoxylin-eosin staining of the specimen. The cyst lining consisted of non-keratinizing squamous epithelium, and the wall of the cyst comprised fibrotic tissue with limited dispersed and disorganized smooth muscle fibers and foci of chronic inflammation



sage of the tracer into the bowel. At age 16 months a laparotomy was performed with excision of an intrahepatic cyst that was located inside segment IV and had no connection to the bile ducts on intraoperative cholangiography. Histology showed the lesion to be a cystically dilated duct lined with non-keratinizing squamous epithelium and associated with focal reactive changes only. The duct wall comprised fibrotic tissue with limited dispersed and disorganized smooth muscle fibers and foci of chronic inflammation [Figure 3]. These findings are compatible with a diagnosis of epidermoid cyst. The postoperative course was uneventful and the child is well and asymptomatic 3.5 years after surgery. Serial ultrasound examinations have been normal.

PATIENT 4

A 6 week old boy was referred to our hospital after his parents noticed jaundice. The child was born at full term after a normal pregnancy and was discharged from hospital at age 3 days with a total bilirubin level of 12.8 mg/dl. At postnatal follow-up his bilirubin level rose to 13 mg/dl (direct bilirubin level 6.5 mg/dl, alkaline phosphatase level 1300 IU/L). Ultrasound examination performed at age 6 weeks showed a normal gallbladder with a 19 mm cyst located between the left and right branches of the portal vein with close proximity to the proximal part of an irregular and dilated left hepatic duct. These findings were suggestive of a choledochal cyst. Magnetic resonance cholangiopancreatography (MRCP) showed findings compatible with extrahepatic biliary atresia [Figure 2]. Laparotomy performed at 7 weeks showed that the liver was already cirrhotic. A cystic lesion in the hepatic hilum was connected to a hypoplastic gallbladder. Intraoperative cholangiography demonstrated fine bile ducts arborizing from the base of the cyst [Figure 1]. The cystic mass was excised by

means of a Kasai porto-enterostomy. Histology of the liver was compatible with a ductal plate malformation and the cyst was lined with columnar epithelium showing occasional foci of squamous metaplasia. Although the early postoperative course was uneventful, there were recurrent episodes of cholangitis and the child underwent liver transplantation at age 9 months.

PATIENT 5

A cyst of the hepatic hilum was detected on routine prenatal ultrasound at the 23rd gestational week. No gallbladder was detected. A fetal MRI scan could not identify the gallbladder. A full-term baby was born and postnatal ultrasound performed at 3 days showed a 16 mm cystic lesion of the hepatic hilum consistent with a type I choledochal cyst, as well as a small gallbladder and minimal dilatation of the intrahepatic bile ducts. A HIDA scan showed homogeneous tracer uptake within the liver but the intrahepatic and extrahepatic bile ducts were not seen, findings consistent with the diagnosis of biliary atresia. Laparotomy at 12 days showed a soft cholestatic liver with a cystic lesion of the hepatic hilum connected to a hypoplastic gallbladder. Intraoperative cholangiography confirmed fine arborizing bile ducts emanating from the base of the cyst. Following cyst excision, a Kasai porto-enterostomy was performed. Histologic examination of the liver specimen showed dysmorphic bile ducts, cholangiolar proliferation, and features of a ductal plate malformation. These histological findings are consistent with the diagnosis of biliary atresia. The postoperative course was uneventful, with bilirubin and liver enzyme levels gradually returning to normal. The child remains asymptomatic and anicteric with normal level of bilirubin 2.5 years after surgery.

DISCUSSION

Congenital biliary duct cysts are anomalies of the biliary tree characterized by cystic dilatation of portions of the extrahepatic and/or intrahepatic biliary ducts, and may manifest as jaundice, right upper quadrant pain, or a palpable abdominal mass. These cysts may also be asymptomatic and detectable only by prenatal ultrasound or imaging in the postnatal period performed for unrelated symptoms. These conditions are rare, accounting for 1% of benign biliary disease, with a very low incidence in Western populations (1: 150,000 births) [6].

Current surgical management of choledochal cysts includes total cyst excision with biliary reconstruction using Roux-en-Y choledochojejunostomy or choledochoduodenostomy, or simple cyst excision depending on the anatomy of the cyst as defined by the original classification of biliary cysts proposed by Alonso-LEJ et al. in 1959 [7]. This classification system was updated by Todani et al. [8] and is the one we use. This system describes five main types; our cases of choledochal cysts (patients 1 and 2) are classified as type II according to the Todani et al. classification.

Table 1. Summary of cases

Patient no.	Diagnosis	Cyst maximal diameter (mm)	Gallbladder	Direct bilirubin level at admission (mg/dl)	Operative procedure	Outcome
1	Intrahepatic choledochal cyst	20	Normal	0.7	CE	Asymptomatic
2	Choledochal cyst	22	Small	0.7	–	Asymptomatic
3	Epidermoid cyst	32	Normal	0.2	CE	Asymptomatic
4	Biliary atresia with choledochal cyst	19	Hypoplastic	6.5	CE + PE	Liver Transplantation
5	Biliary atresia with choledochal cyst	16	Hypoplastic	5.7	CE + PE	Asymptomatic

CE = cyst excision, PE = porto-enterostomy

Biliary atresia with simultaneous cystic lesions of the bile ducts constitute rare malformations and may make the preoperative diagnosis confusing [9]. It may be difficult to differentiate between biliary atresia and true choledochal cysts. Some types of biliary atresia (type I cystic and type IIId), which account for approximately 5% of all cases, manifest as biliary cystic malformation [10]. Muise et al. [11] suggested that biliary atresia associated with cystic disease is a distinct subtype most commonly associated with type 1 biliary atresia, an absence of other congenital anomalies, and an overall better prognosis. These cases (patients 4 and 5 in our series) are extremely rare; Takahashi and colleagues [12] reported an incidence of 12 cases over a period of 45 years, out of 200 cases of biliary atresia [12]. Earlier detection and diagnosis of biliary atresia associated with cystic structures in the hilum may contribute to a better prognosis after porto-enterostomy in these infants.

An algorithm for management of antenatally diagnosed biliary cystic lesions was proposed by Davenport and Hadzic [13]: namely, the first study after birth should be a confirmatory ultrasound scan at age 1 week, and if the intrahepatic bile ducts are not dilated, further studies (radionuclide scan, endoscopic retrograde cholangiography, liver biopsy) are needed to differentiate between non-obstructed choledochal cyst and biliary atresia. Cholangiographic determination of bile duct continuity can be further assessed by endoscopic retrograde cholangiopancreatography (ERCP), magnetic resonance cholangiopancreatography (MRCP), percutaneous transhepatic cholangiography (PTC), or intraoperative cholangiography (IOC). Computed tomography cholangiography is useful in showing continuity of the cyst with the main biliary tree as well as its relationship to surrounding structures, where it is more accurate than ultrasound in visualizing the intrahepatic bile ducts, the distal bile duct and the pancreatic head; high quality images without respiratory artifacts may be superior to MR scans in some infants [14]. In cases where dilated intrahepatic ducts are detected, MRCP may help to distinguish type I choledochal cyst from type IV variants, which may alter the operative approach [15].

The presence of biliary atresia must be defined early in the first weeks of life as this requires early surgical treatment to prevent liver damage. Previous studies described clinical and radiological characteristics of hepatic hilar cysts that can help

differentiate between biliary atresia and choledochal cysts. According to the study of Casaccia et al. [4], a small anechoic hepatic hilar cyst and absent gallbladder are sonographic findings suggestive of biliary atresia in contrast to choledochal cyst; Jiexiong et al. [5] reached similar conclusions in their study. Saito and co-authors [10] concluded that the changes in biliary cyst size reflect the amount of bile excreted from the liver and the patency of the bile ducts throughout gestation. Biliary cystic malformation cases with a small cyst throughout gestation can include some biliary atresia cases, and these cases are related to poorer bile flow and more severe liver fibrosis [10]. According to the study of Tanaka and co-researchers [16], findings consistent with biliary atresia as compared with choledochal cyst include cyst size smaller than 21 mm and direct bilirubin level greater than 2.5 mg/dl. In all patients in this study a gallbladder was demonstrated by ultrasound examination, but the appearance of the gallbladder did not help to differentiate between the two groups. In our study as well, small cyst size, hypoplastic gallbladder, and high level of direct bilirubin at admission were features noted in the two patients with biliary atresia as compared to the other patients [Table 1].

The current management for choledochal cyst in most cases involves complete cyst excision with biliary reconstruction. The timing of surgery remains controversial. Foo et al. [17] evaluated the clinical outcomes of patients whose diagnosis was made prenatally compared to those diagnosed after birth, and showed that those diagnosed prenatally had earlier surgery and fewer adverse complications [17]. This issue is debatable since in older infants (age > 3 months) biliary-enteric anastomoses are technically easier to perform [18]. Although the surgical management of biliary cystic disease is successful in 90% of cases, early morbidity can occur in 2.5–25% of patients and includes biliary or pancreatic fistula, biloma and cholangitis [19]. Late-term complications occur in 25% of patients. These include delayed anastomotic stricture, cholangitis, choledocholithiasis, liver failure and even cholangiocarcinoma. Regarding hepatic hilar epidermoid cysts (as described in patient 3), these cysts are extremely rare and probably should be excised due to their possible malignant potential [20].

In summary, congenital hepatic hilar cysts are rare, and the differential diagnosis includes a broad spectrum of pathologies,

as presented in our study, ranging from benign conditions to biliary cystic malformations that require early surgical intervention. The diagnosis may be challenging, and specialized imaging should be performed to define the anatomic connection between the cyst and the biliary tree and the developmental status of the gallbladder in order to differentiate those cases with attendant biliary atresia, which requires urgent surgery. Small hepatic hilar cysts, hypoplastic gallbladder and high levels of direct bilirubin are suggestive of biliary atresia.

Correspondence

Dr. Y. Berger

Dept. of Surgery B, Sheba Medical Center, Tel Hashomer 52621, Israel

Fax: (972-3) 530-8157

email: bergeryaniv@hotmail.com

References

- Bronstein M, Nizar K, Weiner Z. Significance of early prenatal diagnosis of fetal hepatic cyst. *J Clin Ultrasound* 2009; 37: 65-8.
- Rogers TN, Woodley H, Ramsden W, Wyatt JL, Stringer MD. Solitary liver cysts in children: not always so simple. *J Pediatr Surg* 2007; 42: 333-9.
- Charlesworth P, Ade-Ajayi N, Davenport M. Natural history and long-term follow-up of antenatally detected liver cysts. *J Pediatr Surg* 2007; 42: 494-9.
- Casaccia G, Bilancioni E, Nahom A, et al. Cystic anomalies of the biliary tree in the fetus: is it possible to make a more specific prenatal diagnosis? *J Pediatr Surg* 2002; 37: 1191-4.
- Jiexiong F, Minju L, Hongfeng T, Weizhong G, Shaoyong Y. Clinical and pathological characteristics of cystic lesions of the extrahepatic bile duct in neonates. *Acta Paediatr* 2003; 92: 1183-9.
- Jabłońska B. Biliary cysts: etiology, diagnosis and management. *World J Gastroenterol* 2012; 18: 4801-10.
- Alonso-LEJ F, Rever WB, Pessagno DJ. Congenital choledochal cyst, with a report of 2, and an analysis of 94, cases. *Int Abstr Surg* 1959; 108: 1-30.
- Todani T, Watanabe Y, Narusue M, Tabuchi K, Okajima K. Congenital bile duct cysts: classification, operative procedures, and review of thirty-seven cases including cancer arising from choledochal cyst. *Am J Surg* 1977; 134: 263-9.
- Torrisi JM, Haller JO, Velcek FT. Choledochal cyst and biliary atresia in the neonate: imaging findings in five cases. *AJR Am J Roentgenol* 1990; 155 (6): 1273-6.
- Saito T, Horie H, Yoshida H, et al. The perinatal transition of the hepatobiliary cyst size provides information about the condition of bile flow in biliary cystic malformation cases. *J Pediatr Surg* 2006; 41 (8): 1397-402.
- Muise AM, Turner D, Wine E, Kim P, Marcon M, Ling CC. Biliary atresia with choledochal cyst: implications for classification. *Clin Gastroenterol Hepatol* 2006; 4: 1411-14.
- Takahashi Y, Matsuura T, Saeki I, Zaizen Y, Taquchi T. Excellent long-term outcome of hepaticojejunostomy for biliary atresia with a hilar cyst. *J Pediatr Surg* 2009; 44: 2312-15.
- Davenport M, Hadzic N. Prenatal diagnosis of liver and biliary tract disease. *Semin Neonatol* 2003; 8 (5): 347-55.
- Fumino S, Ono S, Kimura O, Dequchi E, Iwai N. Diagnostic impact of computed tomography cholangiography and magnetic resonance cholangiopancreatography on pancreaticobiliary maljunction. *J Pediatr Surg* 2011; 46: 1373-8.
- Murphy AJ, Axt JR, Crapp SJ, Martin CA, Crane GL, Novvorn HN 3rd. Concordance of imaging modalities and cost minimization in the diagnosis of pediatric choledochal cysts. *Pediatr Surg Int* 2012; 28: 615-21.
- Tanaka N, Ueno T, Takama Y, Fukuzawa M. Diagnosis and management of biliary cystic malformations in neonates. *J Pediatr Surg* 2010; 45: 2119-23.
- Foo DC, Wong KK, Lan LC, Tam PK. Impact of prenatal diagnosis on choledochal cysts and the benefits of early excision. *J Paediatr Child Health* 2009; 45: 28-30.
- Tsai MS, Lin WH, Hsu WM, Lai HS, Lee PH, Chen WJ. Clinicopathological features and surgical outcome of choledochal cyst in different age groups: the implication of surgical timing. *J Gastrointest Surg* 2008; 12: 2191-5.
- Takeshita N, Ota T, Yamamoto M. Forty-year experience with flow-diversion surgery for patients with congenital choledochal cysts with pancreaticobiliary maljunction at a single institution. *Ann Surg* 2011; 254: 1050-13.
- Chiu B, Melin-Aldana H, Superina RA. Management of an epidermoid cyst of the intrahepatic ducts. *J Pediatr Surg* 2005; 40 (12): e31-3.