

A Novel Porcine Model for Chemically Inducible Crohn's-Like Reaction

Yehiel Ziv MD^{1*}, Avinoam Nevler MD^{2,3}, Ehud Willenz DVM⁴, Ofer Doron⁴, Andrew Zbar MD², Aino Shperber MD⁵ and Judith Sandbank MD⁵

¹Coloproctology Unit, Division of Surgery, Assaf Harofeh Medical Center, Zerifin, affiliated with Sackler Faculty of Medicine, Tel Aviv University, Tel Aviv, Israel

²Department of Surgery and Transplantation, Sheba Medical Center, Tel Hashomer, affiliated with Sackler Faculty of Medicine, Tel Aviv University, Tel Aviv, Israel

³Bornstein Talpiot Medical Leadership Program 2012, Sheba Medical Center, Tel Hashomer, Israel

⁴Lahav Research Institute, Israel

⁵Department of Pathology, Assaf Harofeh Medical Center, Zerifin, affiliated with Sackler Faculty of Medicine, Tel Aviv University, Tel Aviv, Israel

ABSTRACT: **Background:** New animal models provide insights into the pathogenesis of different types of inflammatory bowel disease as well as novel pathways for new therapeutic options. However, the scarcity of large animal models hinders the research and development of new surgical procedures and technological devices in inflammatory bowel disease surgery. Common small animal inducible models involve chemical agents that result in the development of acute intestinal inflammation.

Objectives: To assess a novel method for the induction of Crohn's-like colitis using intramural injection of sclerosants in a porcine model.

Methods: Seven domestic pigs underwent several experimental protocols to assess the efficacy of intramural colonic injections of two different compounds (lauromacrogol, and phenol in almond oil). Twenty-five different large bowel segments were treated with intramural injections of the compounds. The animals were followed for 6 weeks, and treated colonic segments were resected for histopathological examination.

Results: Intramural injection of lauromacrogol resulted in non-specific, mild reactive foreign body changes only. Injection of various dosages of 5% phenol in almond oil caused a range of histopathological changes varying from focal fibrosis to Crohn's-like reactions comprising acute and chronic infiltrates, mucosal ulceration and focal necrosis with enteric and lymphoid non-caseating granulomas.

Conclusions: Intramural colonic phenol in almond oil injection in pigs induces inflammatory reactions that histologically resemble Crohn's disease in humans.

IMAJ 2015; 17: 19–23

KEY WORDS: porcine model, Crohn's disease, sclerosant, pathology, inflammatory bowel disease

Inflammatory bowel disease (IBD) is a chronic intestinal inflammatory condition characterized by two major forms,

***This article is dedicated to the memory of Prof. Yechiel (Hilik) Ziv, a colleague, mentor and dear friend, who passed away shortly before publication of this issue**

The first two authors contributed equally to this study

Crohn's disease (CD) and ulcerative colitis, both of which have a multifactorial etiology in the presence of a genetically predisposed host [1,2]. Animal models continue to provide new insights into the pathogenesis of the different types of inflammatory bowel disease and into novel therapeutic options [3]. These experimental approaches have included antigen- or microbially induced colitis, chemical and physical models of inflammation, adoptive T cell transfer models, and transgenic and knockout gene models of disease [4].

In some experimental models of IBD, enteric bacterial antigens are required for the activation of pathogenic T cells and professional antigen-presenting dendritic cells for the induction of colitis [5] where there is a dysregulation, particularly in CD, of pro-inflammatory cytokines towards Th1 cell predominance along with mesenchymal cell and fibroblast proliferation [6]. This is accompanied by an altered expression of adhesion molecules and co-stimulatory molecular species [7] and supplemented by an altered production of protective mucosal mucins, weakening the mucosal barrier and enabling chemically induced mucosal injury [8]. Common animal models of induced acute intestinal inflammation include the rectal administration of acetic acid, indomethacin [9], haptens (principally using trinitrobenzene sulfonic acid which induces Crohn's-like reactions) [10], peptidoglycan polysaccharides [11], and various forms of radiation-induced colitis [12]. Most of these models have been tested and studied in rodents [13]. However, some researchers have used larger animal models including rabbits and pigs [14], as it is expected that porcine models with their omnivorous diet have numerous parallels with the human gastrointestinal system. This preliminary study employed a novel method for the induction of colitis by direct injection of sclerosing agents into the colonic wall in a porcine model, producing similar histological features to CD.

MATERIALS AND METHODS

EXPERIMENTAL ANIMALS

Animal care and all experiments were conducted in accordance with the research protocol approved by the Animal Bioethics

Table 1. Injection protocols

Protocol no.	No. of bowel segments	Animal code	Sclerosant agent and dosage		Follow-up period (weeks)	
			Phenol 5% in almond oil	Lauromacrogol		
				0.5%		1%
1	11	# LRI 1272		0.5 ml x 3*	0.5 ml x 3*	6
		# LRI 1273	0.5 ml x 3* 1 ml x 3* 1.5 ml x 3*			
2	2	# LRI 1504	1.5 ml x 3* 1 ml x 4*			5
3	10	# LRI 1739 # LRI 1740	1 ml x 6* 1.5 ml x 6* 2.5 ml x 4* 2 ml x 6*			7
4	2	# LRI 1556 # LRI 1557	1 ml x 4* into the rectum with 1.2 ml methylene blue solution			6

*Injection points

Figure 1. Intraluminal assist device used for symmetric intramural sclerosant injection

Committee and the local Institutional Review Board [14]. Seven female pigs of domestic breed (large white X Landrace, *Sus scrofa domestica*) were obtained from the Lahav Research Institute (LRI) with a mean body weight of 28 ± 4 kg. Animals were fed a daily balanced swine diet, except on the day of surgery, with free water access at all times. Several synchronous experimental protocols were used to assess the safety, efficacy, concentration and dosage of two different compounds and to define the optimal administration regime [Table 1].

PROTOCOL 1

Two female pigs were prepared for surgery with feeding withheld 6 hours prior to surgery. A preoperative enema was administered 30 minutes before the operation. Animals were placed in the lithotomy position and sedated with intramuscular ketamine hydrochloride (10 mg/kg), xylazine (1–2 mg/kg) and intravenous diazepam (5–10 mg/animal). The pigs were intubated and artificially ventilated. A midline ventral incision was made and a 30 cm segment of the descending colon was isolated with non-crushing clamps. Colitis was induced in five/six distinct colonic segments at 3 cm intervals by intramural

injection of sclerosant material (5% phenol in almond oil solution or lauromacrogol 0.5% and 1%) into the bowel wall at three distinct points along the bowel wall circumference of each segment by creation of a subserosal halo. Each treated bowel segment was marked by placement of an adjacent titanium staple for identification and each segment was injected with a different dosage of the sclerosant (total = 0.5 ml, 1 ml, 1.5 ml, 3 ml, or 4.5 ml) to determine reactivity and the optimal dosage for creation of a diffuse transmural fibrotic colonic reaction.

PROTOCOL 2

One female pig was prepared as above. Colitis was induced in two distinct colonic segments by injecting 5% phenol in almond oil solution into the bowel wall using a spinal injection needle and an intraluminal assist device for symmetric intramural injection [Figure 1]. There were three injection points in the first segment and four in the second segment, and a different total bowel wall dosage (4 ml and 4.5 ml) was administered.

PROTOCOL 3

Colitis was induced in two female pigs in five distinct ring segments of the bowel wall by intramurally injecting 5% phenol in almond oil solution in four/six points along the bowel wall circumference. Each segment received a different total dosage (6 ml, 9 ml, 10 ml, 12 ml).

PROTOCOL 4

Two female pigs were prepared as above, but without preparation for laparotomy. A straight rectal assist device containing four different needle tunnels was inserted transanally. Proctitis was induced in the rectum by injection of 5% phenol in almond oil solution into the rectal wall using a spinal injection needle (22G, 0.717 mm diameter, 12.7 cm length) extending 2–3 mm from the assist device. Each of the four injection points on the circumference was injected with 1 ml of sclerosant and 1.2 ml of methylene blue as a tissue marker for later rectoscopic viewing of the injection site.

EXPERIMENTAL PROCEDURE FOR ALL PIGS

The pigs were observed until full recovery from anesthesia and regularly followed for an average of 6 weeks (5–7 weeks). Their general manner as well as signs of gastrointestinal distress (abdominal pain, vomiting, constipation, diarrhea, anorexia, significant weight loss) were evaluated. Analgesia (dypirone 30 mg/kg intramuscularly) was administered postoperatively and further analgesia on subsequent days was administered based on individual signs of distress. The animals were euthanized after a predefined follow-up period by the administration of a barbiturate overdose followed by potassium chloride. The treated segments of the colon were resected and sent for histopathological examination to the Department of Pathology and Cytology at Assaf Harofeh Medical Center.

RESULTS

PROTOCOL 1

Histopathological examination of the resected colon that was injected with the lauromacrogol solution (0.5%, 1%) (# LRI 1272) demonstrated non-specific mild foreign body reactivity only. Histopathological examination of the 5% phenol in the almond oil case (# LRI 1273) showed prominent submucosal fibrosis at two sites (0.5 ml and 1 ml injection at three points). The fibrotic reaction showed early fibroblastic proliferation associated with mild, predominately chronic inflammatory cell infiltrates extending along the bowel wall for 1.2–1.5 cm. Other findings included mild non-specific foreign body reactivity and minimal subserosal oligocellular fibrotic foci.

PROTOCOL 2

Histopathological examination of the resected colon that was injected with 5% phenol in almond oil solution (# LRI 1504) showed irregular fibrotic foci in the submucosa combined with necrotizing, non-caseating and non-necrotizing granulomata with acute and chronic inflammatory infiltrates and non-polarizing foreign body material within the center of granulomata. Inflammatory response extended from the submucosa through the muscularis mucosa to the muscularis propria. Mesenteric lymph nodes also demonstrated a granulomatous response. The inflammatory process was similar at the sites of 1.5 ml (three injection site points) compared with 1 ml (4 injection site points). Figure 2 shows mucosal ulceration at the site of injection with the presence of a chronic transmural inflammatory cell infiltrate and a non-caseating granuloma of the bowel wall.

PROTOCOL 3

Histopathological examination of the first specimen (# LRI 1739) showed submucosal fibrosis, fatty necrosis and a granulomatous reaction. The lowest phenol dosage (1 ml at six injection points) only showed focal fibrosis in the submucosa. The second dosage site (1.5 ml at six injection points) revealed focal, but more extensive, non-specific, fibrosis in the submucosa and subserosa. The third dosage site (2.5 ml at four injection points) showed focal, but more extensive circumferential fibrosis. Analysis of the highest total dosage (2 ml at six injection points) revealed extensive fibrosis and some granulomatous reaction. Histopathological examination of the second specimen (# LRI 1740) showed submucosal fibrosis alternating in severity from mild to severe, with most of the fibrotic reaction surrounding fatty foci. The lower phenol dosages (1 ml at six injection points, 1.5 ml at six injection points, and 2.5 ml at four injection points) yielded mild septal fibrosis with focal fibrotic zones. Analysis of the highest total dosage (2 ml at six injection points) showed focal fibrotic foci at the submucosal surface without extension into the rest of the bowel wall.

tion points) only showed focal fibrosis in the submucosa. The second dosage site (1.5 ml at six injection points) revealed focal, but more extensive, non-specific, fibrosis in the submucosa and subserosa. The third dosage site (2.5 ml at four injection points) showed focal, but more extensive circumferential fibrosis. Analysis of the highest total dosage (2 ml at six injection points) revealed extensive fibrosis and some granulomatous reaction. Histopathological examination of the second specimen (# LRI 1740) showed submucosal fibrosis alternating in severity from mild to severe, with most of the fibrotic reaction surrounding fatty foci. The lower phenol dosages (1 ml at six injection points, 1.5 ml at six injection points, and 2.5 ml at four injection points) yielded mild septal fibrosis with focal fibrotic zones. Analysis of the highest total dosage (2 ml at six injection points) showed focal fibrotic foci at the submucosal surface without extension into the rest of the bowel wall.

PROTOCOL 4

Histopathological examination of the first specimen (# LRI 1556) showed multiple small fibrotic foci extending 1.6–2.0 cm along the bowel wall with a chronic inflammatory infiltrate combined with granulomata. The second specimen (# LRI 1557) showed no discrete histologic changes.

Table 2 summarizes the histopathological reactivity in our protocols as well as previously reported responses to other injected agents.

DISCUSSION

In this small preliminary study, a large animal model demonstrated basic histopathological changes that resembled CD when 1–1.5 ml of 5% phenol in almond oil was injected at multiple points in the colonic wall. This model resulted in the development of non-caseating granulomata with acute and chronic inflammatory infiltrates centering round non-polarizing foreign body material and extending transmurally from the submucosa

Figure 2. Hematoxylin and eosin (H&E) photomicrograph showing **[A]** colonic mucosal ulceration, chronic inflammation and a central granuloma (original magnification x2), **[B]** Transmural acute and chronic inflammatory cell infiltrates with ulcerations and areas of focal fibrosis (original magnification x2), and **[C]** Non-caseating granuloma (original magnification x10)

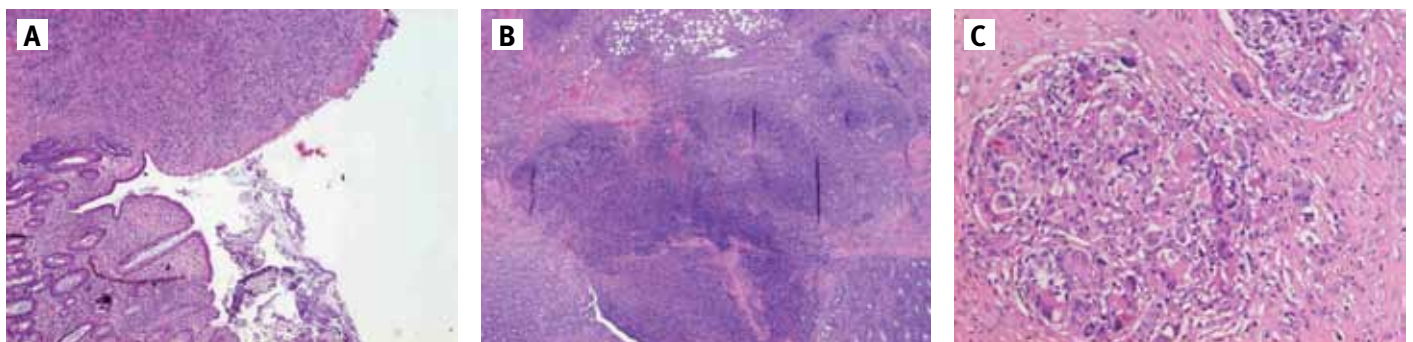


Table 2. Comparison of the histopathological response in study injection protocols and other reported agents

	Phenol	Trinitrobenzene sulfonic acid	Peptidoglycan polysaccharides	Indomethacin	Crohn's disease	Ulcerative colitis
Mucosal ulcers	+	+	+/-	+	+	+
Transmural inflammation	+	+(only around ulcers)	+	+(only around ulcers)	+	-
Granulomas	+	+/-	+	+/-	+	-
Fibrosis	+	+(only around ulcers)	+	+(only around ulcers)	+	+/-
Lymphoid aggregates	+	+/-	+	-	+	-

through the muscularis mucosa to the muscularis propria. Granulomata were also detected in adjacent pericolic mesenteric lymph nodes. The inflammatory effect of 5% phenol in almond oil was dose dependent: higher doses of sclerosant resulted in more extensive submucosal fibrosis with fatty necrosis, along with circumferential fibrosis and sporadic granulomatous response, but without transmural spread of the inflammatory response; lower phenol dosages resulted in focal submucosal or subserosal fibrotic changes only; local rectal infiltration of low dose phenol caused localized transmural fibrotic foci combined with a chronic inflammatory infiltrate and granulomas.

To the best of our knowledge phenol-induced colitis in other animal models has not been described; this protocol is our original idea. Many animal IBD models can be used to evaluate new anti-inflammatory drugs. These models, however, usually demonstrate acute, self-limiting colitis. The spontaneous colitis models developed in the cotton-top tamarin monkey and the C3H/HeJBir mouse mimic additional features of human IBD. Inflammation is chronic and is regulated by multiple genetic factors. The differential genetic susceptibility of inbred rat strains to chronic inflammation has been well utilized in laboratory research: namely, Lewis rats injected with bacterial products, peptidoglycan polysaccharide or indomethacin develop chronic relapsing enterocolitis, whereas closely related Buffalo or Fisher rat strains develop only transient inflammation. These models are also useful to test the specific inhibition of inflammatory mediators and target molecules. Over-expression (transgenic) or deletion (knockout) of specific genes has led to the development of rodent models of spontaneous colitis [15].

Prior to the 1980s, there was a limited number of experimental model systems modeling Crohn's-related inflammation. More recently, there has been an expansion of largely mouse models that have focused on immune and non-immune cell subsets and soluble mediators involved in immune dysregulation secondary to predominant mucosal damage [16]. Such models can be classified into four main categories: a) the administration of specific chemical agents (as in our study); b) the development of models in spontaneously occurring colitis in mutant mouse strains, such as the C3H/HeBir [17] and SAMP1/Yit mice [18]; c) gene knockout and transgenic

colitis strains [19]; and d) studies following T cell reconstitution in primarily immunodeficient mice [20]. Some local chemical models, including intrarectal instillation of the hapten trinitrobenzene sulfonic acid, require an initiator such as ethanol to induce a severe inflammatory response and result in preliminary transmural tissue necrosis followed by mucosal regeneration. This approach relies on a transient increase in intestinal permeability, allowing the chemical agent to reach the submucosal space where there is a break in T cell tolerance to naturally occurring mucosal antigens, which is then associated with distorted mucosal regeneration. This Crohn's-like response to exogenous agents runs a different course in different inbred mouse strains, indicative of an inherent genetic predisposition to particular diseases [21].

In certain experimental conditions, chemically induced colitis is dependent on the underlying T helper cell predominance and its inherent prevailing cytokine protocol favoring a Th2 response in ulcerative colitis-like models with interleukin (IL)-4 and transforming growth factor-beta (TGF β) over-expression, where IL-4 has a pathogenic role and TGF β limits the severity of observed inflammation. By contrast, Th1 predominance is implicated in the pathogenesis of CD [22]. The exact cytokine expression profile defines the features that histologically resemble either a Crohn's-like or an ulcerative colitis-like response, polarizing the cytokine reaction with differential response severity depending on the murine strain used and the dose of the chemical agent [23]. Our studies require expansion to determine if phenol in appropriate doses induces a cytokine pattern that is more indicative of a Crohn's-like reactivity so that it may be considered an acceptable experimental animal model. In this respect, recent evidence has suggested that in addition to the Th1/Th2 IBD paradigm there is a critical involvement of the IL-23/IL-17 pathway in the pathogenesis of Crohn's-like experimental disease [24]. In this regard, heterodimeric IL-23 appears to be a basic contributor to the development of the type of Th1-mediated chronic colitis observed in several murine Crohn's-like models, including the IL-10 KO mouse model, the CD45RB model, the *Helicobacter hepaticus*-induced colitis model, and the CD40-dependent innate immune mediated colitis model.

Granuloma formation in particular appears to be mediated by a unique subset of infiltrating IL-23-producing dendritic cell subsets, which produce IL-12 and induce interferon-gamma as part of the Th1 lymphocytic response necessary for Crohn's-like inflammatory responses [25].

These models, however, have been scarcely researched in large animal models, resulting in a lack of adequate acute and chronic operable animal models to allow long-term follow-up. Our preliminary studies in a porcine model have shown that local intramural colonic phenol in almond oil injection may induce inflammatory reactions in the porcine colon and its adjacent lymph nodes that histologically resemble CD in humans. It remains to be assessed whether the cytokine pattern derived from lymphocytes in this model also reflects the inflammatory mediator profile that is noted in the Crohn's intestine, making it a potentially more valuable comparative model. Moreover, this simple porcine model may potentially provide an opportunity to assess the responsiveness to anti-tumor necrosis factor-alpha therapy using simple objective histological markers of reduced inflammation and mucosal healing. Although murine models have provided incontrovertible evidence that a dysregulated immune response and an abnormal cytokine profile are pivotal for the development of IBD, in any animal model of CD, the issues of IBD homology with human illness and the development of reproducible indices of inflammatory severity are complex. Currently, it is believed that different responses to transient intestinal injury occur either in genetically susceptible or genetically resistant hosts. Considering this genetic background, the chronic pathological inflammatory process is initiated by a relatively non-specific environmental trigger which rather than being associated with mucosal repair and down-regulation of T cell responsiveness is actually followed by an aggressive T cell response. This exaggerated response results in chronic inflammatory cell dysregulation, poor epithelial barrier function, limited mucosal restitution, and defective bacterial elimination.

In conclusion, these preliminary studies offer a previously undescribed Crohn's-like model in a large animal. It is our belief that the use of a simple and reliable large animal model of Crohn's disease will advance the understanding of disease pathogenesis and treatment response and allow a significantly better evaluation of the current surgical treatment of CD.

Correspondence

Dr. A. Nevler

Dept. of General Surgery and Transplantation, Sheba Medical Center,

Tel Hashomer 52621, Israel

Phone: (972-3) 530-2235

Fax: (972-3) 530-8157

email: dr.nevly@gmail.com

References

1. Sartor RB. Mechanisms of disease: pathogenesis of Crohn's disease and ulcerative colitis. *Nat Clin Pract Gastroenterol Hepatol* 2006; 3: 390-407.

2. Xavier RJ, Podilsky DK. Unravelling the pathogenesis of inflammatory bowel disease. *Nature* 2007; 448: 427-34.

3. Kawada M, Arihiro A, Mizoguchi E. Insights from advances in research of chemically induced experimental models of human inflammatory bowel disease. *World J Gastroenterol* 2007; 13: 5581-93.

4. Elson CO, Cong Y, McCracken VJ, Dimmitt RA, Lorenz RG, Weaver CT. Experimental models of inflammatory bowel disease reveal innate, adaptive, and regulatory mechanisms of host dialogue with the microbiota. *Immunol Rev* 2005; 206: 260-76.

5. Ostanin DV, Bao J, Koboziev I, et al. T cell transfer model of chronic colitis: concepts, considerations, and tricks of the trade. *Am J Physiol Gastrointest Liver Physiol* 2009; 296: G135-46.

6. Pucilowska JB, Williams KL, Lund PK. Fibrosis and inflammatory bowel disease: cellular mediators and animal models. *Am J Physiol Gastrointestinal Liver Physiol* 2000; 279: G653-9.

7. Hart AL, Al-Hassi HO, Rigby RJ, et al. Characteristics of intestinal dendritic cells in inflammatory bowel diseases. *Gastroenterology* 2005; 129: 50-65.

8. Van der Sluis M, De Koning BA, De Bruijn AC, et al. MUC2-deficient mice spontaneously develop colitis, indicating that MUC2 is critical for colonic protection. *Gastroenterology* 2006; 131: 117-29.

9. Morris GP, Beck PL, Herridge MS, Depew ST, Szewczuk MR, Wallace JL. Hapten-induced model of chronic inflammation and ulceration in the rat colon. *Gastroenterology* 1989; 96: 795-803.

10. Saha S, Jing X, Park SY, et al. Peptidoglycan recognition proteins protect mice from experimental colitis by promoting normal gut flora and preventing induction of interferon-gamma. *Cell Host Microbe* 2010; 8: 147-62.

11. Langberg CW, Hauer-Jensen M, Sung CC, Kane CJ. Expression of fibrogenic cytokines in rat small intestine after fractionated irradiation. *Radiother Oncol* 1994; 32: 29-36.

12. Hoffmann JC, Pawlowski NN, Kühl AA, Höhne W, Zeitz M. Animal models of inflammatory bowel disease: an overview. *Pathobiology* 2002-2003; 70: 121-30.

13. Wirtz S, Neurath MF. Mouse models of inflammatory bowel disease. *Adv Drug Deliv Rev* 2007; 59: 1073-83.

14. Negaard A, Loberg EM, Naess PA, Eriksen M, Klow NE. Feasibility of MRI in experimentally induced inflammatory small bowel disease: a pilot study in a porcine model. *Dig Dis Sci* 2010; 55: 14-20.

15. Stadnicki A, Colman RW. Experimental models of inflammatory bowel disease. *Arch Immunol Ther Exp (Warsz)* 2003; 51: 149-55.

16. Boismenu R, Chen Y. Insights from mouse models of colitis. *J Leukocyte Biol* 2000; 67: 267-78.

17. Sundberg JP, Elson CO, Bedigian H, Birkenmeier EH. Spontaneous, heritable colitis in a new substrain of C3H/HeJ mice. *Gastroenterology* 1994; 107: 1726-35.

18. Matsumoto S, Okabe Y, Setoyama H, et al. Inflammatory bowel disease-like enteritis and caecitis in a senescence accelerated mouse P1/Yit strain. *Gut* 1998; 43: 71-8.

19. Mombaerts P, Mizoguchi E, Grusby MJ, Glimcher LH, Bahn AK, Tonegawa S. Spontaneous development of inflammatory bowel disease in T cell receptor mutant mice. *Cell* 1993; 75: 275-82.

20. Dieleman LA, Ridwan BU, Tennyson GS, Beagley KW, Bucy RP, Elson CO. Dextran sulfate sodium-induced colitis occurs in severe combined immunodeficient mice. *Gastroenterology* 1994; 107: 1643-52.

21. Elson CO, Cong Y, Brandwein S, et al. Experimental models to study molecular mechanisms underlying intestinal inflammation. *Ann N Y Acad Sci* 1998; 859: 85-95.

22. Neurath MF, Finotto S, Glimcher LH. The role of Th1/Th2 polarization in mucosal immunity. *Nat Med* 2002; 8: 567-73.

23. Strober W, Fuss IJ, Blumberg RS. The immunology of mucosal models of inflammation. *Annu Rev Immunol* 2002; 20: 495-549.

24. Yen D, Cheung J, Scheerens H, et al. IL-23 is essential for T cell-mediated colitis and promotes inflammation via IL-17 and IL-6. *J Clin Invest* 2006; 116: 1310-16.

25. Mizoguchi A, Ogawa A, Takedatsu H, et al. Dependence of intestinal granuloma formation on unique myeloid DC-like cells. *J Clin Invest* 2007; 117: 605-15.