Large Solitary Splenic Diffuse Large B Cell Lymphoma in a Hepatitis C Virus-Infected Patient

Meirav Kedmi MD, Tzvi Fridlander MD, Yaron Ilan MD and Oren Shibolet MD

Division of Internal Medicine, Hadassah-Hebrew University Medical Center, Jerusalem, Israel

Key words: hepatitis C virus, splenic high grade lymphoma

IMAJ 2005;7:346–347

Hepatitis C virus-associated lymphoproliferative disorders are a group of heterogeneous diseases that include low, intermediate and high grade lymphomas as well as non-malignant B cell expansion [1]. We describe a patient with HCV infection who presented with a rare solitary splenic diffuse large B cell lymphoma.

Patient Description

A 55 year old woman was admitted with a 2 month history of weight loss, low grade fever and arthralgia involving the metacarpophalangeal and proximal interphalangeal joints. The patient was diagnosed as suffering from HCV infection, thought to be contracted through blood transfusions she received during labor 16 years earlier. She was asymptomatic and had not received antiviral therapy previously. Two months prior to her admission, she sustained a blunt trauma to the left upper abdominal quadrant and underwent abdominal ultrasound that showed splenomegaly, with two hyperechoic lesions, one in the upper pole measuring 10.5 cm and the other in the lower pole measuring 3.5 cm. Her medical history was unremarkable, and she was not taking any medications.

On physical examination she had low grade fever (37.4°C) and a palpable spleen. There were no signs of arthritis and no lymphadenopathy. Laboratory results included normal blood count and liver function tests. HCV serology was positive. Polymerase chain reaction for hepatitis C RNA was positive with a 1B genotype. Serologic markers for hepatitis A and B viruses, cytomegalovirus, Ebstein-Barr virus and human immunodeficiency virus, as well as antinuclear antibodies, antineutrophil cytoplasmic antibodies, antiparietal cell antibodies, anti-smooth muscle, antimitochondrial and anti-LKM antibodies were all negative. C3 and alpha fetoprotein were within normal limits; cryoglobulin levels were undetectable. Abdominal computerized tomography demonstrated splenomegaly with two large hypodense lesions – the upper measuring 10.5 x 10.1 x 11.5 cm [Figure], and the lower measuring 3.5 x 3.5 x 3.2 cm. There were no focal lesions in the liver. An ultrasound-guided spleen biopsy was taken, and histopathology showed splenic tissue replaced with atypical lymphoid cells, with multiple mitoses and many apoptotic cells. These cells were positive for CD20 and negative for CD3. The pathologic diagnosis was diffuse large B cell lymphoma. Bone marrow biopsy did not show involvement by lymphoma, and B cell rearrangement (Bcl-2) was negative in the marrow. The patient was treated with a CHOP regimen (cyclophosphamide, daunorubicin, oncovin, prednisone) and is currently in remission.

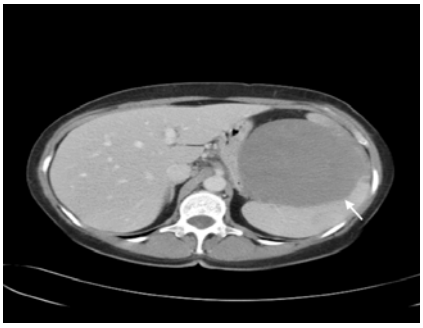

The spleen is enlarged. There is a hypodense upper pole lesion measuring 10.5 x 10.1 x 11.5 cm. There are no focal lesions in the liver and no lymphadenopathy is seen.

Comment

HCV-associated lymphomas are a group of heterogeneous diseases. They include low, intermediate and high grade lymphomas, with nodal distribution of the first type being most common. In cryoglobulinemic patients, the most frequently reported type is immunocytoma. Splenic B cell lymphoma with villous lymphocytes and hepatosplenic lymphoma have also been reported in patients with HCV infection [1]. Here we report a patient with HCV and splenic diffuse large B cell lymphoma. This kind of lymphoma is rare in HCV-infected patients, and has seldom been described [Table]. Although liver biopsy was not performed, the normal liver function tests and the lack of CT findings do not support significant liver involvement.

Table. Aggressive splenic B-cell lymphoma in HCV-infected patients

Yoshikawa M, et al. Acute hepatic failure due to hepatosplenic B-cell non-Hodgkin's lymphoma in a patient infected with HCV. *J Gastroenterol* 1998.
Ascoli V, et al. Extranodal lymphomas associated with HCV infection. *Am J Clin Pathol* 1998.
Gil J, et al. Fulminant hepatosplenic B cell lymphoma in a young patient with HCV-chronic hepatitis. *Leukemia* 1998.
Satoh T, et al. The relationship between primary splenic malignant lymphoma and chronic liver disease associated with hepatitis C virus infection. *Cancer* 1997.
Fukutomi T, et al. Case report: primary splenic non-Hodgkin's B cell lymphoma in a patient with chronic hepatitis C. *J Gastroenterol Hepatol* 1996.

HCV = hepatitis C virus

Studies from Italy, North America and Japan have demonstrated a high prevalence of HCV infection (7–37%) in patients with B cell non-Hodgkin's lymphoma [2–4], suggesting a pathogenetic link between the two. The finding of HCV antigens in lymphoma tissue lends support to this concept. HCV is an RNA virus that cannot integrate into the genome and its oncogenic potential is not yet fully understood. It has been proposed that chronic infection with HCV stimulates lymphocytes, resulting in clonal B cell expansion, which eventually may lead to frank malignancy [3]. Bcl-2 translocation t(14:18) is the typical chromosomal abnormality for follicular lymphomas. Bcl-2, an anti-apoptotic protein, is translocated to the area of the heavy chain immunoglobulin, and is overexpressed. High rates of B cell clonality and Bcl-2 translocation have been reported in patients infected with HCV with and without cryoglobulinemia. It was suggested that HCV core protein might directly induce cell expansion by inhibiting apoptotic cell death, as shown in transfected cells *in vitro*.

In view of the low general incidence of lymphoma in HCV-infected patients and the lack of efficient screening methods, it may prove ineffective to screen HCV patients for the presence of lymphoma. To date, no studies assessing this modality have been published. It was recently reported that villous B cell lymphoma in HCV-infected patients can regress following antiviral therapy [1]. However, whether to treat patients with antiviral therapy solely for the prevention of lymphoma and whether to add antiviral treatment to conventional chemotherapeutic regimens in an effort to prevent recurrence of lymphoma remain open questions [5].

References

1. Oliveier H, Francois L, Jean-Piere B, et al. Regression of splenic lymphoma with villous lymphocytes after treatment of hepatitis C virus infection. *N Engl J Med* 2002;347:89–94.
2. Zuckerman E, Zuckerman T. Hepatitis C and B-cell lymphoma: the hemato-hepatologist linkage. *Blood Rev* 2002;16:119–25.
3. Luppi M, Longo G, Ferrari M, et al. Clinicopathological characterization of hepatitis C virus-related B-cell non-Hodgkin's lymphomas without symptomatic cryoglobulinemia. *Ann Oncol* 1998;9:495–8.
4. Fiorilli M, Mecucci C, Farci P, Casato M. HCV-associated lymphomas. *Rev Clin Exp Hematol* 2003;7:406–23.
5. Kelaidi C, Rollot F, Park S, et al. Response to antiviral treatment in hepatitis C virus-associated marginal zone lymphomas. *Leukemia* 2004;18:1711–16.

Correspondence: Dr. O. Shibolet, Gastroenterology Unit GRJ715, Massachusetts General Hospital, 55 Fruit Street, Boston 02411, MA, USA.
Phone: (1-617) 726-6122
Fax: (1-617) 726-3673
email: oshibolet@partners.org