IMAJ • VOL 12 • FEBRUARY 2010

# Obstructed Defecation Syndrome: Diagnosis and Therapeutic Options, with Special Focus on the STARR Procedure

Ada Rosen MD

Department of Surgery A, Wolfson Medical Center, Holon and Sackler Faculty of Medicine, Tel Aviv University, Ramat Aviv, Israel

**KEY WORDS:** obstructed defecation syndrome, STARR procedure, constipation, rectocele

*IMAJ* 2010; 12: 104–106

Chronic constipation is a common self-reported bowel symptom that affects 2–30% of people in the western world. It has a considerable impact on health costs and quality of life. About 30–50% of constipated patients have obstructed defecation [1,2].

The classical symptoms are pain at defecation, extreme straining to defecate, extended time on the toilet, long interval between two evacuations (5–10 days), perineal pain/discomfort when standing, feeling of incomplete evacuation, and fragmented defecation [1].

Once a patient with these complaints enters a pelvic floor clinic, a very detailed diagnostic workup is necessary to assess the exact cause of obstruction and to tailor the most appropriate treatment. The diagnostic workup starts with a general investigation that includes: history of symptoms, physical examination (digital anal examination and anoscopy), blood tests, barium enema or colonoscopy, and rectal biopsy if needed. This is followed by specific anorectal tests, such as anorectal manometry, balloon expulsion test, rectal compliance, electromyography, nerve stimulation, transit studies, defecography, and endoanal ultrasound.

We distinguish between two types of constipation caused by obstructed defecation: functional and mechanical. The functional type causes idiopathic megarectum, anismus, descending perineal syndrome, and solitary rectal ulcer syndrome [3].

- **Megarectum** is an enlarged rectal diameter up to 6 cm at the level of the pelvic brim, or total rectal capacity of over 450 ml of air on manometry. In special cases in children, megarectum is due to a damaged mienteric plexus and abnormal motor function of the rectum [3]. Treatment is surgical – anorectal myectomy or the Duhamel procedure.
- **Anismus**, also known as spastic pelvic floor and pelvic floor dyssynergia, is a malfunction of the external anal sphincter and puborectalis muscle during defecation. This is a paradoxical contraction: failure to relax the pelvic floor and anal muscles during defecation [3]. The treatment for anismus is difficult since patients with functional defecation disorders are often unresponsive to conservative medical management such as stool softeners and niphedipine. Biofeedback training has a success rate of 70–78% [4,5]. Treatment with botulinum toxin injection may provide temporary improvement, but it remains an investigational treatment. Surgical division of the puborectalis muscle can also be offered to these patients [6].
- **Descending perineum syndrome** is caused by excessive straining and weakened perineal muscles (possible stretching damage to the pudendal nerves) [3]. Treatment can be conservative, such as the use of stool softeners, sphincter exercises and avoidance of straining. Treatment may also be surgical, namely, post-anal repair, which corrects the anorectal angle.
- **Solitary rectal ulcer** 4–10 cm from the anal verge usually occurs on the anterior wall (68%). In these cases we often encounter a hyperactive puborectalis muscle with paradoxical contractions. It is frequently associated with straining and prolapse (partial or complete). Treatment consists of administration of local steroids and stool softeners (to prevent straining), as well as biofeedback [4,5]. If prolapse is present, it should be surgically repaired.

Mechanical causes of obstructed defecation are stricture, neoplasm, enterocele, intussusception, rectal prolapse, and rectocele.

- **Stricture** usually follows surgery or trauma. Treatment can be conservative (use of stool softeners and enemas), invasive (use of dilators, YAG laser, or diathermy), or surgical (resection, sphincterotomy or anoplasty).
- **Neoplasm**, which should be ruled out by colonoscopy.
- **Enterocele** is the herniation of small bowel into the pouch of Douglas. Treatment is laparoscopic closure of the enlarged pouch of Douglas. [7].
- **Rectal prolapse/intussusception** is a partial (mucosal) or complete protrusion of the entire thickness of the rectal wall through the anal sphincter.

It is classified as first degree when the protrusion is invisible, second degree when it is visible on straining, and third degree when visible externally. It is caused by diastasis of the levators, deep Douglas pouch, redundant rectosigmoid, patulous anus, or loss of rectal horizontal position (due to loose attachment to the sacrum). Treatment is surgical by the abdominal approach (Ribshtain procedure, which is a fixation of the stretched rectum to the sacrum with or without a mesh), the perineal approach (Altemeier operation that involves a sleeve resection of the prolapsed rectum and colon with a primary anastomosis performed transanally, or the Thiersch ring), or transanal (the STARR procedure: namely, stapled transanal rectal resection).

- **Rectocele** is defined as a herniation of the rectal wall through a defect in the rectovaginal septum in the direction of the vagina. It was traditionally considered as a defect in the rectovaginal septum, not the rectum. Possible causes are erect bipedal posture, vaginal childbirth, chronic increase in abdominal pressure (constipation, straining), or congenital or inherited weakness in the pelvic support system. Classical symptoms are incomplete rectal emptying or bulge in the vagina. Evacuation is often digitally supported. The definitive objective diagnosis of rectocele is most commonly made by defecography. This also assesses the size of the rectocele and the emptying capacity. The surgical indications for rectocele repair are controversial, but most surgeons advocate operative repair when a symptomatic rectocele is large (> 3 cm), or if it fails to empty sufficiently on defecography. The treatment of rectocele is surgery, the surgical approach can be transvaginal [8], transperineal [9], or transanal [10-12].

The overall success rate of various surgical procedures is 80–95%.

**Figure 1.** Stapled transanal rectal resection resection (STARR) [20]

**STARR** (stapled transanal rectal resection) is a new surgical procedure that was launched by Longo in 2001. It is a minimally invasive transanal operation for rectocele and mucosal/rectal prolapse using a double circular stapler [Figure 1].

In January 2006, the European STARR registry was initiated. According to the results published in 2009 on 2838 patients, the improvement in rectal function and quality of life was statistically significant [13]. A multicenter study conducted in Spain between 2001 and 2006 concluded that this procedure is associated with low morbidity and short hospital stay and is an effective treatment option for obstructed defecation syndrome [14]. According to a Milan study reported in 2009, STARR is safe and effective in the treatment of solitary rectal ulcer associated with internal rectal prolapse and has minimal complications and no recurrence after 2 years [15].

Recently, a new device – the CCS-30 Contour Transtar – was developed by the same Professor Longo. A multicenter prospective study from Naples confirms that the device is effective and safe and has functional results similar to those of the conventional STARR [16]. This procedure (with both techniques), according to most authors, is effective; the postoperative pain is mild, and the procedure is very much accepted among colorectal surgeons for the treatment of rectocele as well as for internal rectal prolapse in patients with obstructed defecation. Yet, it should be emphasized that STARR is associated with complications such as postoperative bleeding, chronic proctalgia, rectovaginal fistula, stricture, and fecal

**Figure 2.** S.T.A.R.R.
Written and agreed upon by the group of S.T.A.R.R. Pioneers Oct. 26-28, 2006

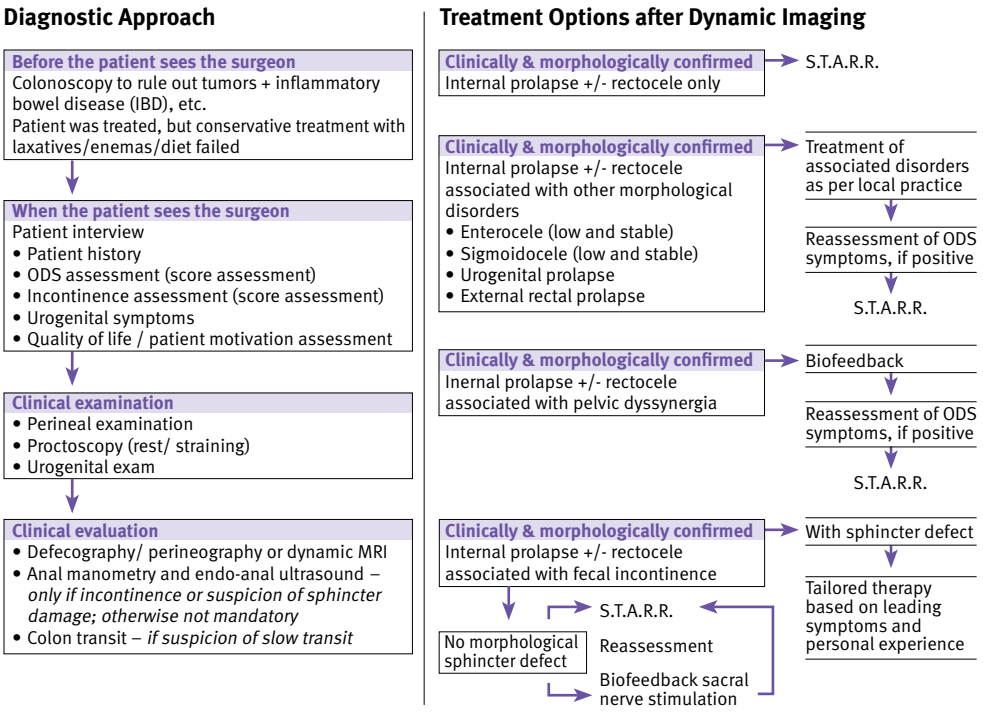

incontinence [17,18]. Some of these are "learning curve" complications and can be avoided. In patients with enterocele and puborectalis dyssynergia, this procedure is contraindicated (unless the enterocele is repaired simultaneously on laparoscopy) [19]. All authors stress that if this procedure is performed in selected cases by skilled specialists, most complications can be avoided [18].

In view of conflicting reports on the safety and efficacy of the STARR procedure, a European group of experts was founded in October 2006; and in June 2008, following a consensus conference with evidence-based conclusions, they published guidelines on inclusion and exclusion criteria as well as a diagnostic and therapeutic algorithm for the STARR procedure in ODS [20] [Figure 2].

These recommendations were based on the experience of 11 specialists in coloproctology and pelvic floor disease, pioneers in the STARR procedure, and it was concluded after a 100% consensus within the group [20]. They also concluded that this procedure can be performed with either of the devices, depending on the size of the prolapse or rectocele and on the personal experience of the surgeon. Patient selection is crucial, as is the use of the standardized diagnostic and therapeutic approach. From my personal experience with STARR and TRANSTAR procedures, I maintain that when performed with caution, after a very careful selection of patients, both procedures are safe and carry good results in patients with obstructed defecation syndrome.

**Correspondence:**
**Dr. A. Rosen**
Dept. of Surgery A, Wolfson Medical Center, Holon 58100, Israel
**Phone:** (972-3) 670-4480
**Fax:** (972-3) 670-4815
**email:** adarosen@netvision.net.il

## References

1. Lembo A, Camilleri M. Chronic constipation. *N Engl J Med* 2003; 349: 1360-8.
2. Surrenti E, Rath DM, Pemberton JH, Camilleri M. Audit of constipation in a tertiary referral gastroenterology practice. *Am J Gastroenterol* 1995; 90: 1471-5.
3. Bharucha AE, Wald A, Enck P, Rao S. Functional anorectal disorders. *Gastroenterology* 2006; 130: 1510-18.
4. Chiarioni G, Whitehead WE, Pezza V, Morelli A, Bassotti G. Biofeedback is superior to laxatives for normal transit constipation due to pelvic floor dyssynergia. *Gastroenterology* 2006; 130: 657-64.
5. Chiarioni G, Salandini L, Whitehead WE. Biofeedback benefits only patients with outlet dysfunction, not patients with isolated slow transit constipation. *Gastroenterology* 2005; 129: 86-97.
6. Kamm MA, Hawley PR, Lennard-Jones JE. Lateral division of the puborectalis muscle in the management of severe constipation. *Br J Surg* 1988; 75: 661-3.
7. Zacharin FR, Hamilton NT. Pulsion enterocele: long-term results of an abdominoperineal technique. *Obstet Gynecol* 1980; 2: 141-8.
8. Porter WE, Steele A, Walsh P, Kohli N, Karram MM. The anatomic and functional outcomes of defect-specific rectocele repairs. *Am J Obstet Gynecol* 1999; 181: 1353-8.
9. van Laarhoven CJ, Kamm MA, Bartram CI, Halligan S, Hawley PR, Phillips RK. Relationship between anatomic and symptomatic long-term results after rectocele repair for impaired defecation. *Dis Colon Rectum* 1999; 42: 204-11.
10. Block JR. Transrectal repair of rectocele using obliterative suture. *Dis Colon Rectum* 1986; 29: 707-11.
11. Khubchandani IT, Sheets JA, Stasik JJ, Hakki AR. Endorectal repair of rectocele. *Dis Colon Rectum* 1983; 26: 792-6.
12. Sehapayak S. Transrectal repair of rectocele: an extended armamentarium of colorectal surgeons. A report of 335 cases. *Dis Colon Rectum* 1985; 28: 422-33.
13. Jane DG, Schwandner O, Stuto A. Stapled transanal rectal resection for obstructed defecation syndrome: one year results of the European SRARR Registry. *Dis Colon Rectum* 2009; 52: 1205-12.
14. Arroyo A, Gonzales-Argente FX, Garcia-Domingo M, et al. Prospective multicenter clinical trial of stapled transanal rectal resection for obstructed defecation syndrome. *Br J Surg* 2008; 95: 1521-7.
15. Boccasanta P, Venturi M, Calabro G, Maccioco M, Roviaro GC. Stapled transanal rectal resection in solitary rectal ulcer associated with prolapse of the rectum: a prospective study. *Dis Colon Rectum* 2008; 51: 348-54.
16. Renzi A, Talento P, Giardiello C, Angelone G, Izzo D, Di SamoG. Stapled transanal rectal resection by a new dedicated device for the surgical treatment of obstructed defecation syndrome caused by rectal intussusaption and rectocele: early results of a multicenter prospective study. *Int J Colorectal Dis* 2008; 23: 999-1005.
17. Gagliardi G, Pescatori M, Altomare DF, et al. Results, outcome, predictors and complications after stapled transanal resection for obstructed defecation. *Dis Colon Rectum* 2008; 51: 186-95.
18. Pescatori M, Gagliardi G. Postoperative complications after procedure for prolapsed hemorrhoids (PPH) and stapled transanal rectal resection (STARR) procedure. *Tech Coloproctol* 2008; 12: 7-19.
19. Carriero A, Picchio M, Martellucci J, Talento P, Palimento D, Spaziani E. Laparoscopic correction of enterocele associated to stapled transanal rectal resection for obstructed defecation syndrome. *Int J Colorectal Dis* 2009. [Epub ahead of print]
20. Schwandner O, Stuto A, Jayne D, et al. Decision-making algorithm for the STARR procedure in obstructed defecation syndrome. Position statement of the group of STARR Pioneers. *Surg Innov* 2008; 15: 105-9.