

## Bisphosphonate and Estrogen Replacement Therapy for Postmenopausal Periodontitis

Ronit Haimov-Kochman MD<sup>1</sup>, Tuvia Kochman DMD MPA<sup>3</sup>, Ayala Stabholz DMD<sup>2</sup> and Drorith Hochner-Celinkier MD<sup>1</sup>

<sup>1</sup>Department of Obstetrics and Gynecology, Hadassah University Hospital, Mount Scopus, and <sup>2</sup>Department of Periodontics, Hadassah University Hospital, Ein Kerem, Jerusalem, Israel

<sup>3</sup>Central Dental Clinics, Meuhedet Healthcare Services, Jerusalem, Israel

**Key words:** bisphosphonate, estrogen replacement therapy, periodontitis, menopause

*IMAJ 2004;6:173–177*

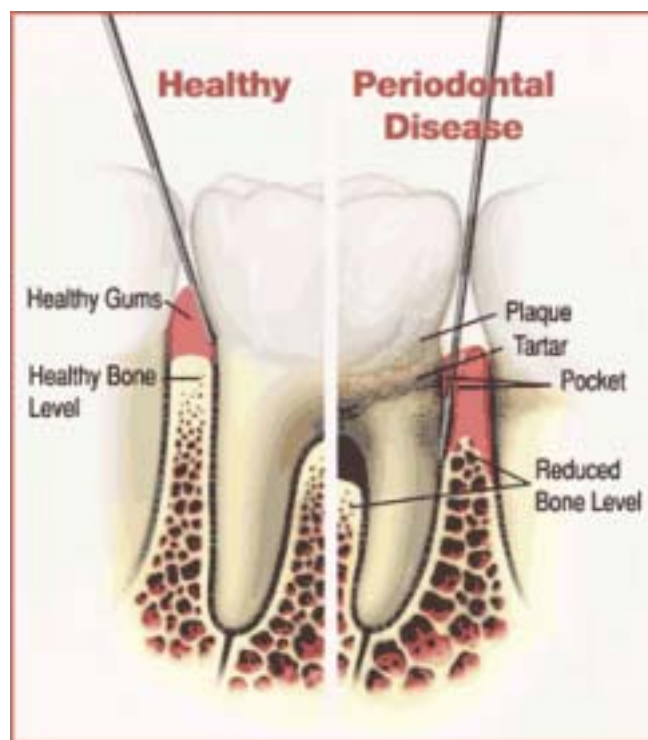
Periodontal diseases affect one-third of the overall United States population and 42% of individuals over the age of 65 are edentulous [1]. The term "periodontal disease" refers to both gingivitis and periodontitis. Gingivitis is an inflammatory condition of the soft tissues surrounding the teeth, the gingiva, and is a direct immune response to the dental microbial plaque building up on teeth. The main symptoms of gingivitis are redness, swelling and bleeding of the gums, with no involvement of the supporting structures of the teeth such as the periodontal ligament and the alveolar bone. Gingivitis can often be controlled by removing the hard and soft deposits from the tooth surfaces. Periodontitis, which succeeds gingivitis in susceptible individuals, is characterized by destruction of the supporting structures of the teeth including the periodontal ligament, bone and soft tissues. Periodontitis is also influenced by the individual's immune and inflammatory responses but, in contrast to gingivitis, it occurs in only a subset of the population and if not treated leads to tooth loss.

Periodontal diseases are infectious diseases that develop as a result of bacterial accumulation on the tooth surface where the gingiva and the tooth meet. Experimental short-term clinical studies have shown that microorganisms quickly colonize clean tooth surfaces after subjects discontinue oral hygiene procedures. In the healthy mouth, more than 350 species of microorganisms have been found. Periodontal infections are linked to fewer than 5% of these species. When oral hygiene is neglected, the bacterial flora on the tooth surface and in the gingival sulcus gradually shift from Gram-positive aerobic to Gram-negative anaerobic species. Some of these Gram-negative anaerobic bacteria are considered pathogenic to the periodontal tissues and are involved in the development and progression of destructive periodontitis. Some of these periodontal pathogens produce a variety of enzymes and toxins that initiate inflammatory and immune responses, which in turn result in periodontal tissue breakdown and lead to teeth loss.

The initiation and progression of periodontal diseases are modified by local and systemic conditions as well as drug intake. Local factors include plaque retention areas associated with defective restorations, malpositioned teeth, or periodontal pockets that result from preexisting periodontal disease. Apart from hereditary factors, certain systemic disorders render patients more susceptible to these inflammatory conditions. These include

diabetes mellitus, low immunity status, AIDS, poor nutrition, and some medications (glucocorticoids, calcium channel blockers, immunosuppressive drugs). A consistent positive association between smoking and loss of periodontal attachment has been reported and confirmed in both cross-sectional and longitudinal studies [2].

The alveolar process, which projects from the basal jaw bone, contains the teeth and the sockets in which they are suspended [Figure 1]. Proper development of the alveolar process depends on tooth eruption and is maintained as long as the tooth is retained. When the teeth fail to develop (e.g., anodontia) the alveolar process fails to form, and when teeth are extracted most of the alveolar process is resorbed, leaving the basal bone as the major



**Figure 1.** Anatomic comparison of healthy and periodontitis-affected tooth and its supporting structures.

constituent of the jawbone. The alveolar bone is composed of outer and inner cortical plates of compact bone that enclose the spongy trabecular bone. The remodeling process of the alveolar bone allows wound healing following periodontal therapy and migration of teeth during orthodontic tooth movement.

In healthy periodontal tissues, the roots of the teeth fit into individual sockets in the alveolar bone and are held firmly in place by the periodontal ligament. Both the periodontal ligament and the alveolar bone are major factors in tooth anchorage, and together with the tooth cementum constitute the attachment apparatus of the tooth. Connective tissue degradation and alveolar bone resorption around periodontally involved teeth could lead to their loss.

### **Treatment modalities for periodontitis**

The main goal of periodontal treatment is to control the infection by eliminating or reducing causative factors in order to allow inflammation to resolve and gingival tissues to heal. Treatment of periodontal diseases generally falls into two categories: a) procedures designed to halt the progression of disease, and b) procedures designed to regenerate structures destroyed by the disease. All periodontal treatments require good basic daily oral hygiene care. The impact of systemic diseases on the cause or treatment of periodontal disease should be addressed, as should certain behavioral changes. Patients should quit smoking, since smoking has been shown to be one of the strongest risk factors for periodontitis. The initial phase of therapy is aimed at eliminating as many of the local causes of periodontal disease as possible, including bacterial plaque and calculus, faulty restorations and any other local factors that appear to be associated with periodontal inflammation or patient discomfort. Topical and systemic antibiotics might be beneficial to some periodontal conditions as adjunct to the mechanical therapy. Following re-evaluation of the healing response to this initial treatment, some patients might require additional treatment such as periodontal surgery to correct the effects of periodontal disease on the periodontal tissues, teeth or masticatory system. After the active treatment is completed, supportive periodontal therapy is an essential part of any periodontal treatment plan that will otherwise fail or prove ineffective.

### **Periodontitis in women**

Female hormones were found to have an effect on the gingival tissues. Changes in sex hormone levels during puberty, pregnancy, menstruation and menopause have long been associated with the development of gingivitis. Gingivitis may flare up at the premenstrual period when progesterone levels are high. Progesterone dilates blood vessels, increasing the inflammatory process, and blocks the repair of collagen. During pregnancy, the risk for gingivitis increases and is referred to as "pregnancy gingivitis." In some cases, a tumor-like hyperplasia that resembles pyogenic granuloma is found on the gingiva of pregnant women and is called "pregnancy tumor." During menopause, women may experience oral dryness, increased dental caries, dysesthesia, taste alteration, atrophic gingivitis, periodontitis and osteoporotic jawbone unsuitable for conventional dental devices and implants [3].

Higher levels of inflammatory bone-active cytokines such as interleukins-1 and 6 were measured in the gingival fluid of menopausal estrogen-deficient women compared to premenopausal women [4]. Several studies have addressed the association between the presence of periodontitis and osteoporosis. Both diseases share several risk factors such as older age and smoking, and therapies designed to influence systemic bone mineral density in the axial skeleton may be associated with less tooth loss and a slower loss of alveolar bone.

### **Systemic osteoporosis and oral bone loss**

The possible association between osteoporosis and oral bone loss was first suggested in 1960 [5]. These early investigators studied vertebral bodies, which they believed best resembled the alveolar bone for their similar trabecular consistency as well as for the lack of muscular insertions in these bones. Subsequent histomorphometric and microradiographic studies showed that after menopause there was a marked increase in the cortical porosity of the mandible, especially in the alveolar bone. Bone turnover rate is higher in the alveolar bone than in long bones. Therefore, it was suggested that a systemic imbalance in bone resorption and deposition might be manifested earlier in the alveolar process than in other sites [6]. A concomitant decrease in oral bone mass appeared to be gender-specific, with loss of 1.5% per year of bone mineral content in females and 0.9% in males. A correlation between bone density of the jaws and other bones such as the metacarpals, vertebrae and femurs was later found [7–16], although two early studies did not note a significant correlation [17,18] [Table 1]. The majority of the studies reported age-related lower mandibular bone mineral content in women, which was more pronounced in menopausal women. However, these studies were hindered by small sample sizes, limited control of potential confounding factors, and varying definitions of both periodontal disease and osteoporosis. Epidemiologic evidence that suggested such a correlation was published in 1990. In a 3 year prospective study of 14,375 men and women between the ages of 65 and 85, 401 women suffered from a hip fracture. In this group the risk of hip fracture was significantly correlated to tooth loss [19]. It is commonly accepted that the majority of menopausal women lose bone mass at a rate of 1–2% per year. Nevertheless, a quarter of menopausal women are rapid bone losers, with a loss rate of about 5–8% per year. This latter group is at particular risk for oral bone loss.

On the one hand, alveolar bone loss as a part of systemic osteoporosis may play a role in the multifactorial nature of periodontal disease pathogenesis [20]. On the other hand, systemic factors responsible for postmenopausal osteoporotic bone loss may combine with local factors such as periodontal disease to enhance alveolar bone loss [21]. In C.H. Chestnut's words: "Is systemic osteopenia a risk factor for periodontitis; is systemic osteopenia a risk factor for oral osteopenia independent of periodontal disease; or is periodontal disease a primary (exclusive) risk factor for oral osteopenia?" Owing to the study limitations mentioned earlier, the answers to these inquiries remain elusive [22].

**Table 1.** Correlation between bone density of the jaws and skeletal bone

| Authors year, [ref]          | Population  | Major outcome  | Type of study               |
|------------------------------|---|--|-----------------------------|
| Inagaki et al. 2001 [7]      | 190 Japanese women: 89 premenopausal, 101 postmenopausal                                | Correlation between low metacarpal bone density and periodontitis, and also with tooth loss after menopause                                  | Cross-sectional             |
| Payne et al. 2000 [8]        | 59 postmenopausal women with periodontitis  | Correlation between lumbar spine density or smoking and alveolar bone density change   | Longitudinal unblinded      |
| Tezal et al. 2000 [9]        | 70 Caucasian postmenopausal women aged 51–78  | Correlation between skeletal bone density (spine and femur neck) and alveolar bone loss and to less extent clinical attachment loss of teeth | Cross-sectional             |
| Taguchi et al. 1999 [10]     | 91 Japanese women aged 40–68  | Correlation between lumbar vertebral bone density and mandibular cortical bone mass and number of posterior teeth                            | Cross-sectional             |
| Payne et al. 1999 [11]       | 38 postmenopausal women with periodontitis: 17 with osteopenia/osteoporosis, 21 healthy | Osteopenic/osteoporotic subjects had higher frequency of alveolar bone loss relative to normal subjects                                      | 2 yr longitudinal unblinded |
| Bando et al. 1998 [12]       | 26 postmenopausal women: 12 edentulous, 14 healthy                                      | Correlation between reduced lumbar vertebral bone density and edentulous status  | Cross-sectional             |
| Strechfus et al. 1997 [13]   | 28 healthy women aged 23–78   | Correlation between second metacarpal bone density and alveolar bone density   | Cross-sectional             |
| Jacobs et al. 1996 [14]      | 69 women receiving HRT  | Correlation between spinal density mandibular cortical bone mass at second examination   | Longitudinal unblinded      |
| Von Wöern et al. 1994 [15]   | 12 women with severe osteoporosis, 14 healthy women                                     | Osteoporotic subjects had less bone mineral content and more loss of attachment than normal subjects   | Cross-sectional             |
| Klemetti et al. 1994 [16]    | 227 healthy postmenopausal women with periodontitis                                     | Individuals with high skeletal bone density retain more teeth than those with osteoporosis   | Cross-sectional             |
| Elders et al. 1992 [17]      | 286 perimenopausal women aged 46–55, 60 of them edentulous                              | No significant differences were noted between dentate and edentate subjects with lumbar and metacarpal bone densities                        | Cross-sectional             |
| Mohajery and Brook 1992 [18] | 35 postmenopausal women: 21 with osteoporosis, 14 healthy                               | Alveolar bone radiographic density did not correlate with femoral neck and lumbar spine densities  | Cross-sectional             |

### Hormonal replacement therapy

While numerous studies have demonstrated a relationship between low levels of estrogen and skeletal bone loss, the influence of estrogen deficiency on alveolar bone density has only recently been elucidated in epidemiologic studies. Regression of bone mass with age is curvilinear with a sharp decline in bone mass in the fifth decade of life. This was attributable to estrogen deficiency experienced during menopause. The number of years from menopause was found to be directly related to alveolar ridge height reduction. Analysis of self-reported data from the Nurses' Health Study for 42,171 female nurses between the ages of 30 and 55 indicated that estrogen reduced tooth loss by 24% in current

hormone users [23]. Similar results for tooth loss in menopausal women were reported in the 10 year Leisure World Cohort. This study reported a 36% reduction in tooth loss in estrogen users [24]. In a small 1 year longitudinal clinical study, alveolar bone density, evaluated by densitometric analysis, was compared between two patient groups: menopausal estrogen users and non-users. Estrogen users displayed a mean net gain in alveolar bone density while non-users disclosed a mean net loss of alveolar bone density [25]. Case-control studies support the suggestion that hormonal replacement therapy influenced alveolar bone loss and teeth detachment [26]. There is also evidence from a recent randomized, double-blind, placebo-controlled trial that 3 years of HRT at a dosage designed to treat systemic osteopenia and osteoporosis increased alveolar bone mass [27].

The influence of estrogen treatment on clinical parameters of periodontitis was further investigated in a sheep animal model. Gingival pocket depths and gingival IL-6 were significantly greater in ovariectomized sheep [28]. Clinical measurements such as detectable supragingival plaque, bleeding on probing and relative clinical attachment level improved with estrogen supplementation, indicating that HRT reduced gingival inflammation [29]. IL-1, a potent inflammatory mediator, was shown to increase in the gingival fluid of menopausal women compared to premenopausal women. In menopausal women suffering from progressive periodontitis, gingival fluid IL-1 level was three times lower in E2 users than in non-users [30]. E2 and progesterone were shown to suppress IL-1 production in response to stimulation in human peripheral monocytes *in vitro*. The

inhibition was not the result of enhanced prostaglandin E2 production [31]. It was concluded that low levels of E2 is a risk factor for periodontitis, and that HRT could improve periodontal status both by its anti-inflammatory and anti-bone resorptive actions. Postmenopausal estrogen users may retain more teeth. Sustained oral health and better tooth retention are potentially an additional benefit of HRT [32]. However, HRT was lately found to have a deleterious risk-benefit ratio to women's health [33]. This

HRT = hormone replacement therapy  
IL = interleukin  
E2 = estrogen

therapy increases the risk of thromboembolic events such as myocardial infarction and cerebral stroke. Breast cancer risk was found to be higher in long-term HRT users. The recent recommendations of the North American Menopause Society as well as of the Israel Menopause Society are to use HRT primarily for treatment of hot flashes and osteoporosis, based on the individual's symptoms and risk factors [34].

Selective estrogen receptor modulators such as tamoxifen and raloxifene have a beneficial effect on bone resorption. Raloxifene is indicated for the treatment of postmenopausal osteoporosis, however its influence on periodontal parameters has not been reported.

### Bisphosphonate therapy

Bisphosphonates have been shown to increase bone mass in estrogen-deficient patients by inhibition of osteoclast activity and induction of osteoclast apoptosis. Animal studies from the past 10 years have shown that bisphosphonates significantly retarded the progression of periodontitis in monkeys, as measured by bone density changes [35–37]. Alendronate, a third-generation aminobisphosphonate was studied in naturally occurring periodontitis in beagle dogs. A statistically significant difference in alveolar bone mass and teeth attachment loss and mobility was observed after 6 months of alendronate therapy, whereas no effect was found on clinical parameters of gingival inflammation and plaque formation in the bisphosphonate-treated dogs [37]. The role of alendronate in periodontitis was recently studied in humans. A placebo-controlled, double-blind randomized study was conducted among 40 type II diabetic patients with established periodontitis. The patients were assigned to alendronate 10 mg/day or placebo treatment. Alendronate induced a significant decrease in urine N-telopeptide, a biochemical bone resorption marker, and a significant increase in alveolar bone crest height, as evaluated by digital radiographic imaging after 6 months. In spite of comparable glycemic control in both groups, periodontal parameters were better for the alendronate-treated group in this short-term pilot trial [38].

### Conclusion

Osteoporosis is a multifactorial chronic asymptomatic disease that progresses subclinically for decades until fractures occur late in life; most patients are diagnosed too late to receive effective therapy. Oral bone loss might be interpreted as a part of generalized skeletal osteoporosis. Therefore, therapy aimed at osteoporosis could be of value in the treatment of oral bone loss. Postmenopausal osteoporosis is stressed as a risk factor with important orodental implications for dental patients. Identification of specific high risk groups for either osteoporosis or periodontitis could enable the gynecologist or dentist to prevent and treat systemic and alveolar bone loss prior to the occurrence of a fracture or tooth loss. Dentists should utilize the dental status of postmenopausal women suffering from periodontitis and tooth loss for referral for early diagnosis of generalized osteopenia/osteoporosis and for evaluation of treatment for its systemic and oral health benefits. An integral part of routine gynecologic workup for menopausal women with osteoporosis should be a dental check-up for the early

diagnosis of alveolar ridge resorption. Increased dialogue among medical and dental professionals could achieve maintenance of our patients' optimal health.

The treatment of periodontal disease has been primarily directed towards a microbiological etiology. The prevention of bone loss by modulating the host response to infection could be a new adjunctive method in the management of periodontitis. Drugs that alter bone metabolism, such as estrogen and bisphosphonate, were suggested by several case-control studies as a new approach to the treatment of periodontitis in postmenopausal patients. However, strong evidence-based data regarding the effect of estrogen and bisphosphonate on clinical endpoints such as loss of teeth are still lacking. Moreover, the optimal duration of these therapies is unknown. In light of the recently published data [33] from large-scale clinical trials of an altered risk-benefit ratio of hormone replacement therapy, prescribing estrogen formulation solely for the treatment of periodontitis would be unjustified. Nevertheless, the periodontal condition of postmenopausal women treated with HRT for various reasons such as hot flashes or osteoporosis is likely to improve. Further investigation is needed to confirm the efficacy of estrogen and bisphosphonate supplementary treatment modalities in postmenopausal periodontitis.

### References

1. National Institute of Dental Research. Broadening the Scope: Long-Range Research Plan for the Nineties. Bethesda, MD: National Institutes of Health, NIH Publication No. 90-1188, 1990.
2. Genco RJ. Current view of risk factors for periodontal diseases. *J Periodontol* 1996;67(Suppl):1041–9.
3. Friedlander AH. The physiology, medical management and oral implications of menopause. *J Am Dent Assoc* 2002;133:73–81.
4. Reinhardt RA, Masada MP, Payne JB, Allison AC, DuBois LM. Gingival fluid IL-1 beta and IL-6 levels in menopause. *J Clin Periodontol* 1994;21:22–5.
5. Groen JJ, Duyvsenz F, Halsted JA. Diffuse alveolar atrophy of the jaw (non-inflammatory form of parodontal disease) and pre-senile osteoporosis. *Geront Clin* 1960;2:68–86.
6. Mancke E, Chesnut CH III, Wergedal JE, Baylink DJ, Nelp WB. Relationship between local and total bone mass in osteoporosis. *Metabolism* 1975;24:605–15.
7. Inagaki K, Kurosu Y, Kamiya T, et al. Low metacarpal bone density, tooth loss, and periodontal disease in Japanese women. *J Dent Res* 2001;80:1818–22.
8. Payne JB, Reinhardt RA, Nummikoski PV, Dunning DG, Patil KD. The association of cigarette smoking with alveolar bone loss in postmenopausal females. *J Clin Periodontol* 2000;27:658–64.
9. Tezal M, Wactawski-Wende J, Grossi SG, Ho AW, Dunford R, Genco RJ. The relationship between bone mineral density and periodontitis in postmenopausal women. *J Periodontol* 2000;71:1492–8.
10. Taguchi A, Suei Y, Ohtsuka M, Otani K, Tanimoto K, Hollender LG. Relationship between bone mineral density and tooth loss in elderly Japanese women. *Dentomaxillofac Radiol* 1999;28:219–23.
11. Payne JB, Reinhardt RA, Nummikoski PV, Patil KD. Longitudinal alveolar bone loss in postmenopausal osteoporotic/osteopenic women. *Osteoporos Int* 1999;10:34–40.
12. Bando K, Nitta H, Matsubara M, Ishikawa I. Bone mineral density in periodontally healthy and edentulous postmenopausal women. *Ann Periodontol* 1998;3:322–6.
13. Streckfus CF, Johnson RB, Nick T, Tsao A, Tucc M. Comparison of alveolar bone loss, alveolar bone density and second metacarpal bone density, salivary and gingival cervical fluid interleukin-6 concentrations in

- healthy premenopausal and postmenopausal women on estrogen therapy. *J Gerontol A Biol Sci Med Sci* 1997;52:M343-51.
14. Jacobs R, Ghyselen J, Koninckx P, Van Steenberghe D. Long-term bone mass evaluation of mandible and lumbar spine in a group of women receiving hormone replacement therapy. *Eur J Oral Sci* 1996;104:10-16.
  15. Von Wowern N, Klausen B, Kellerup G. Osteoporosis: a risk factor in periodontal disease. *J Periodontol* 1994;65:1134-8.
  16. Klemetti E, Collins HL, Forss H, Markkanen H, Lassila V. Mineral status of skeleton and advanced periodontal disease. *J Clin Periodontol* 1994;21:184-8.
  17. Elders PJM, Habets LLMH, Netelenbos JC, Van der Linden LWJ, Van der Stelt PF. The relation between periodontitis and systemic bone mass in women between 46 and 55 years of age. *J Clin Periodontol* 1992;19:492-6.
  18. Mohajery M, Brook SL. Oral radiograph in the detection of early signs of osteoporosis. *Oral Surg Oral Med Oral Pathol* 1992;73:112-17.
  19. Astrom J, Backstrom C, Thidevall G. Tooth loss and hip fractures in the elderly. *J Bone Joint Surg Br* 1990;72:324-5.
  20. Loza JC, Carpio LC, Dziak R. Osteoporosis and its relationship to oral bone loss. *Curr Opin Periodontol* 1996;3:27-33.
  21. Hildebolt CF. Osteoporosis and oral bone loss. *Dentomaxillofac Radiol* 1997;26:3-15.
  22. Chesnut CH III. The relationship between skeletal and oral bone mineral density: an overview. *Ann Periodontol* 2001;6:193-6.
  23. Grodstein F, Colditz GA, Stampfer MJ. Post-menopausal hormone use and tooth loss: a prospective study. *J Am Dent Assoc* 1996;127:370-7, quiz 392.
  24. Paganini-Hill A. The benefits of estrogen replacement therapy on oral health. The Leisure World cohort. *Arch Intern Med* 1995;155:2325-9.
  25. Payne JB, Zachs NR, Reinhardt RA, Nummikoski PV, Patil K. The association between estrogen status and alveolar bone density changes in postmenopausal women with a history of periodontitis. *J Periodontol* 1997;68:24-31.
  26. Jeffcoat MK. Osteoporosis: a possible modifying factor in oral bone loss. *Ann Periodontol* 1998;3:312-21.
  27. Civitelli R, Pilgram TK, Dotson M, et al. Alveolar and postcranial bone density in postmenopausal women receiving hormone/estrogen replacement therapy: a randomized, double-blind, placebo-controlled trial. *Arch Intern Med* 2002;162:1409-15.
  28. Johnson RB, Gilbert JA, Cooper RC, et al. Effect of estrogen deficiency on skeletal and alveolar bone density in sheep. *J Periodontol* 2002;73:383-91.
  29. Reinhardt RA, Payne JB, Maze C, Patil KD, Gallagher SJ, Mattson JS. Influence of estrogen and osteopenia/osteoporosis on clinical periodontitis in postmenopausal women. *J Periodontol* 1999;70:823-8.
  30. Reinhardt RA, Payne JB, Maze C, Babbitt M, Nummikoski PV, Dunning D. Gingival fluid IL-1 beta in postmenopausal females on supportive periodontal therapy. A longitudinal 2-year study. *J Clin Periodontol* 1998;25:1029-35.
  31. Morishita M, Miyagi M, Iwamoto Y. Effects of sex hormones on production of interleukin-1 by human peripheral monocytes. *J Periodontol* 1999;70:757-60.
  32. Birkenfeld L, Yemini M, Kase NG, Birkenfeld A. Menopause-related oral alveolar bone resorption: a review of relatively unexplored consequences of estrogen deficiency. *Menopause* 1999;6:129-33.
  33. Rossouw JE, Anderson GL, Prentice RL, et al., for the Writing Group for the Women's Health Initiative Investigators. Risks and benefits of estrogen plus progestin in healthy postmenopausal women: principal results from the Women's Health Initiative randomized controlled trial. *JAMA* 2002;288:321-33.
  34. Report from the NAMS Advisory Panel on Postmenopausal Hormone Therapy. October, 2002.
  35. Brunsvold MA, Chaves ES, Kornman KS, Aufdemorte TB, Wood R. Effects of a bisphosphonate on experimental periodontitis in monkeys. *J Periodontol* 1992;63:825-30.
  36. Weinreb M, Quartuccio H, Seedor JG, et al. Histomorphometrical analysis of the effects of the bisphosphonate alendronate on bone loss caused by experimental periodontitis in monkeys. *J Periodont Res* 1994;29:35-40.
  37. Reddy MS, Weatherford TW 3rd, Smith CA, West BD, Jeffcoat MK, Jacks TM. Alendronate treatment of naturally occurring periodontitis in beagle dogs. *J Periodontol* 1995;66:211-17.
  38. Rocha M, Nava LE, Vazquez de la Torre C, Sanchez-Marin F, Garay-Sevilla ME, Malacara JM. Clinical and radiological improvement of periodontal disease in patients with type 2 diabetes mellitus treated with alendronate: a randomized, placebo-controlled trial. *J Periodontol* 2001;72:204-9.

---

**Correspondence:** Dr. R. Haimov-Kochman, Dept. of Stomatology, University of California San Francisco, P.O.Box 0512, San Francisco, CA 94143, USA.

Phone: (1-415) 476-1573

Fax: (1-415) 502-7338

email: rkochman@itsa.ucsf.edu